

# EMJ

# Dermatology


## Review of 31<sup>st</sup> EADV Congress

### Editor's Pick

**Pemphigus Vulgaris and Pemphigus Foliaceus: A Single-Centre Comparative Study in Rabat, Morocco**

### Interview

Christa De Cuyper speaks about her roles within the EADV, including the recent Nurses in Dermatology Practice event, which she co-chaired



# Contents

4 Editorial Board

6 Welcome

7 Foreword

10 Congress Review

Review of the European Academy of Dermatology and Venereology Congress 2022

Congress Feature

18 Designing the Future of Dermatology and Venereology

Bilgic and Murrell

20 Updates on Best Practices for Onychomycosis: Hitting the Nail on the Head

Darcy Richards

Symposium Review

25 Photoprotection and the Science Behind Skin Healing

Poster Reviews

32 Clinical Efficacy and Outcomes of Remibrutinib (LOU064) in Patients with Chronic Spontaneous Urticaria Inadequately Controlled with H<sub>1</sub>-Antihistamines: Findings from a Phase IIb Study

## Abstract Reviews

- 40**    **Secukinumab in Moderate-to-Severe Hidradenitis Suppurativa: Primary Endpoint Analysis from the SUNSHINE and SUNRISE Phase III Trials**
- 44**    **Dermatoscopic Rainbow Pattern in Extragenital Lichen Sclerosus et Atrophicus**  
Gunduz et al.

## 46    **Abstract Highlights**

## 53    **Congress Interview**

Christa De Cuyper

## 58    **Infographic**

Rosacea Awareness

## Articles

- 60**    **Editor's Pick: Pemphigus Vulgaris and Pemphigus Foliaceus: A Single-Centre Comparative Study in Rabat, Morocco**  
Mezni et al.
- 66**    **Dermatophyte Monitoring in an Iranian Training Dermatology Hospital**  
Diba et al.
- 73**    **Treatment with Hyaluronic Acid Injections in a Patient with Craniosynostosis**  
Muszalski and Yacomotti
- 79**    **Trichotillomania with Giant Gastric Trichobezoar in a Female Child: A Case Report**  
Abbas et al.
- 85**    **Case Report of Epstein–Barr Virus-Induced Autoimmune Vitiligo in Nigeria**  
Akolawole et al.
- 90**    **Severe Sunburn-Like Adverse Cutaneous Drug Reaction in a Patient on Treatment with Rifaximin: A Rare Case of Acute Phototoxic Drug Reaction**  
Mahajan et al.

# Editorial Board

## Editor-in-Chief

---

Dr Simone Ribero

Assistant Professor in Dermatology, Dermatologic Clinic, Department of Medical Sciences, University of Turin, Italy

## Editorial Board

Dr Michael Gold

The Chicago Medical School, USA

Dr Jennifer Cather

Medical Director, Modern Research Associates, Dallas, Texas, USA

Dr Vishalakshi Viswanath

Rajiv Gandhi Medical College, India

Dr Richard Warren

University of Manchester, UK

Prof Francesca Farnetani

Department of Dermatology, University of Modena and Reggio Emilia, Modena, Italy

Dr Hassan Galadari

Assistant Professor of Dermatology, College of Medicine and Health Sciences, United Arab Emirates University, Al-Ain, United Arab Emirates

Dr Jaishree Sharad

Skinfinti Aesthetic Skin and Laser Clinic, India

Prof Alin Laurentiu Tatu

Medical and Pharmaceutical Research Unit, "Dunărea de Jos" Integrated Interdisciplinary Research Platform (ReForm-UDJG), Dermatology, Faculty of Medicine and Pharmacy Pharmacology Sciences Department, Dunărea de Jos" University of Galați, Romania

Prof Des Tobin

Director of the Centre for Skin Sciences, Faculty of Life Sciences, University of Bradford, West Yorkshire, UK

## Aims and Scope

EMJ is an online only, peer-reviewed, open access general journal, targeted towards readers in the medical sciences. We aim to make all our articles accessible to readers from any medical discipline.

EMJ allows healthcare professionals to stay abreast of key advances and opinions across Europe.

EMJ aims to support healthcare professionals in continuously developing their knowledge, effectiveness, and productivity. The editorial policy is designed to encourage discussion among this peer group.

EMJ is published quarterly and comprises review articles, case reports, practice guides, theoretical discussions, and original research.

EMJ also publishes 16 therapeutic area journals, which provide concise coverage of salient developments at the leading European congresses. These are published annually, approximately 6 weeks after the relevant congress. Further details can be found on our website: [www.emjreviews.com](http://www.emjreviews.com)

## Editorial Expertise

EMJ is supported by various levels of expertise:

- Guidance from an Editorial Board consisting of leading authorities from a wide variety of disciplines.
- Invited contributors are recognised authorities from their respective fields.
- Peer review, which is conducted by EMJ's Peer Review Panel as well as other experts appointed due to their knowledge of a specific topic.
- An experienced team of editors and technical editors.

## Peer Review

On submission, all articles are assessed by the editorial team to determine their suitability for the journal and appropriateness for peer review.

Editorial staff, following consultation with either a member of the Editorial Board or the author(s) if necessary, identify three appropriate reviewers, who are selected based on their specialist knowledge in the relevant area.

All peer review is double blind. Following review, papers are either accepted without modification, returned to the author(s) to incorporate required changes, or rejected.

Editorial staff have final discretion over any proposed amendments.

## Submissions

We welcome contributions from professionals, consultants, academics, and industry leaders on relevant and topical subjects.

We seek papers with the most current, interesting, and relevant information in each therapeutic area and accept original research, review articles, case reports, and features.

We are always keen to hear from healthcare professionals wishing to discuss potential submissions, please email: [editorial.assistant@emjreviews.com](mailto:editorial.assistant@emjreviews.com)

To submit a paper, use our online submission site: [www.editorialmanager.com/e-m-j](http://www.editorialmanager.com/e-m-j)

Submission details can be found through our website: [www.emjreviews.com/contributors/authors](http://www.emjreviews.com/contributors/authors)

## Reprints

All articles included in EMJ are available as reprints (minimum order 1,000). Please contact [hello@emjreviews.com](mailto:hello@emjreviews.com) if you would like to order reprints.

## Distribution and Readership

EMJ is distributed through controlled circulation to healthcare professionals in the relevant fields across Europe.

## Indexing and Availability

EMJ is indexed on DOAJ, the Royal Society of Medicine, and Google Scholar®; selected articles are indexed in PubMed Central®.

EMJ is available through the websites of our leading partners and collaborating societies.

EMJ journals are all available via our website: [www.emjreviews.com](http://www.emjreviews.com)

## Open Access

This is an open-access journal in accordance with the Creative Commons Attribution-Non Commercial 4.0 (CC BY-NC 4.0) license.

## Congress Notice

Staff members attend medical congresses as reporters when required.

## This Publication

ISSN 2054-6211

EMJ **Dermatology** is published **once** a year. For subscription details please visit: [www.emjreviews.com](http://www.emjreviews.com)

All information obtained by EMJ and each of the contributions from various sources is as current and accurate as possible. However, due to human or mechanical errors, EMJ and the contributors cannot guarantee the accuracy, adequacy, or completeness of any information, and cannot be held responsible for any errors or omissions. EMJ is completely independent of the review event (EADV 2022) and the use of the organisations does not constitute endorsement or media partnership in any form whatsoever.

Front cover and contents photograph: Milan, Italy home of the **EADV 2022** © **Alexandra Lande** / stock.adobe.com

**Editor**

Evgenia Koutsouki

**Editorial Managers**

Katherine Colvin,  
Anaya Malik

**Copy Editors**

Noémie Fouarge  
Kirsty Hewitt, Jaki Smith

**Senior Editorial Assistant**

Theo Wolf

**Editorial Assistants**

Natasha Meunier-McVey,  
Janet Nzisa, Darcy Richards,  
Robin Stannard

**Head of Publishing****Operations**

Tian Mullarkey

**Design Manager**

Stacey Rivers

**Senior Designer**

Roy Ikoroha

**Designers**

Steven Paul, Emma Rayner

**Junior Designers**

Dominic Garwood,  
Dillon Benn Grove

**Head of Sales**

Robert Hancox

**Key Accounts Director**

Billy Nicholson

**Director of Performance**

Keith Moule

**Chief Executive Officer**

Dan Scott

**Executive Director**

Dan Healy

**Founder and Executive  
Chairman**

Spencer Gore



*Koutsouki*

**Evgenia Koutsouki**

Editor

I am delighted to welcome you to *EMJ Dermatology 2022*, covering this year's European Academy of Dermatology and Venereology (EADV) Congress, offering an overview of exciting developments, and featuring research articles and case reports among a great range of content.

This year we had the great pleasure of attending the congress that took place in Milan, Italy; our team has covered highlights ranging from the development of a non-invasive test to help predict paediatric eczema to a study on the association between vitamin D deficiency and overall survival for patients with skin cancer. We are also proud to feature a summary of highlights written by members of the congress communication committee, providing a great overview of topics covered at the congress. We had the honour of talking to the Chair of the EADV Nurse Association, Christa De Cuyper, who among other things, discussed the recent Nurses in Dermatology Practice event, which she co-chaired.

In this issue, you will also have the opportunity to read a number of articles: a single-centre study on pemphigus vulgaris and pemphigus foliaceus and an engaging case report describing the use of hyaluronic acid injections as a non-surgical alternative to correct bone deformities in a patient with craniosynostosis.

I would like to thank everyone who helped in bringing this issue together, from the EMJ team working towards producing this content to our Editorial Board, contributors, and reviewers. We are all very proud of this publication and we hope you enjoy reading this issue.

## Contact us

Editorial enquiries: [editor@emjreviews.com](mailto:editor@emjreviews.com)

Sales opportunities: [salesadmin@emjreviews.com](mailto:salesadmin@emjreviews.com)

Permissions and copyright: [accountsreceivable@emjreviews.com](mailto:accountsreceivable@emjreviews.com)

Reprints: [info@emjreviews.com](mailto:info@emjreviews.com)

Media enquiries: [marketing@emjreviews.com](mailto:marketing@emjreviews.com)

# Foreword

Dear Colleagues,

It is my pleasure to welcome you to the latest edition of *EMJ Dermatology*. As with previous issues, this issue contains an immersive array of clinically relevant peer-reviewed articles and case reports.


My choice for Editor's Pick in this publication is a single-centre retrospective study of patients with either pemphigus vulgaris or pemphigus foliaceus over a 30-year period in Rabat, Morocco. By comparing the course of these two major pemphigus variants, the authors are able to provide treatment insights and recommendations for future research.

Furthermore, this issue features several intriguing case reports. Of note, Abbas et al. present an unusual case of trichotillomania with giant gastric trichobezoar in a female child. This increases our understanding of psychological disorders and their dermatological manifestations. It might aid clinicians in the early detection of trichotillomania and trichophagia, as well as the prevention of life-threatening complications such as trichobezoar. Furthermore, our

in-house infographic shines a spotlight on rosacea, covering the symptoms, subtypes, comorbidities, epidemiology, and treatment of this long-term skin condition.

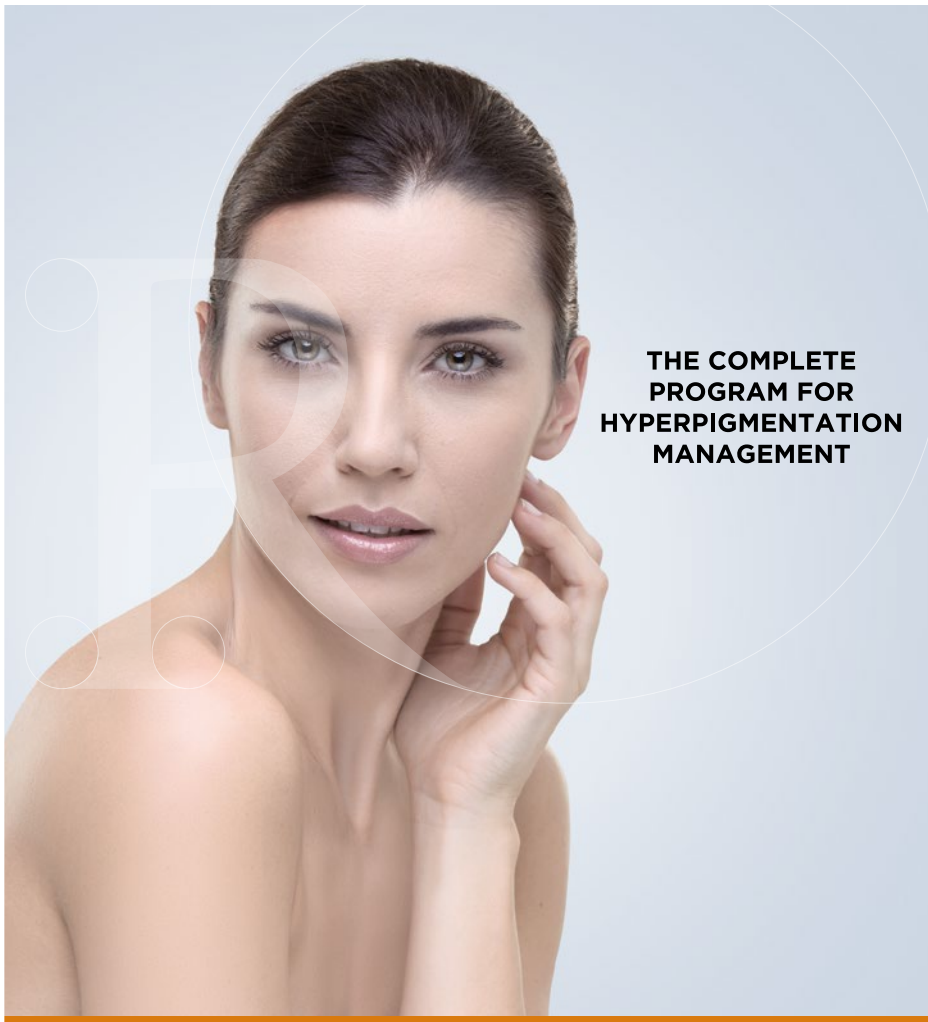For those who were unable to attend this year's European Academy of Dermatology and Venereology (EADV) Congress in Milan, Italy, I highly recommend our congress review. This features research news from the meeting, as well as a compelling feature on nail disorders, and abstract review summaries. EMJ also had the unique opportunity to speak with Christa De Cuyper, Chair of the EADV Nurse Association Working Group. De Cuyper discussed the EADV'S Nurses in Dermatology Practice event, which she co-chaired; the role of the nurse in the care and management of atopic dermatitis; and her primary duties as facilitator of the EADV Task Forces.

I would like to thank all the authors, interviewees, Editorial Board members, and reviewers who contributed to successfully create the 2022 issue of *EMJ Dermatology*. I hope this journal will prove an inspiring read, and assist in daily practice.



## Desmond Tobin

Full Professor of Dermatological Science, Director of the Charles Institute of Dermatology, UCD School of Medicine, University College Dublin, Republic of Ireland



**THE COMPLETE  
PROGRAM FOR  
HYPERPIGMENTATION  
MANAGEMENT**



**Pigment Solution™ Program**

**Efficacy clinically tested for  
hyperpigmentation management<sup>1</sup>.**

Take care of your patient's skin with Pigment Solution™ Program, the 3-in-1 kit (day cream, night cream, preparation cleanser).

It delivers a synergistic action against hyperpigmentation due to Kojic Acid, Glycolic Acid, Aquaxyl, Tocopherol and innovative Biodegradable Scrubbing Beads (BSB).

Pigment Solution™ Program reported an overall statistically significant gradual-reduction of mMASI score -34,62% at 45 days and -64,40% at 90 days in all types of melasma (epidermis, dermis, mixed)<sup>1</sup>.

**RELIFE™. MY SKIN SAYS HOW I FEEL.**

<sup>1</sup>Clinical test performed on 100 patients, with dark patches caused by melasma, for 90 days for the evaluation of percentage reduction in mMASI (modified Melasma Area Severity Index) score from the baseline to 45 days and 90 days.

[relifecompany.com](http://relifecompany.com)

# EMJ Podcasts

The EMJ Podcast aims to provoke conversations around the latest trends and innovations in healthcare, provide engaging and educational content for healthcare professionals, and hosts conversations with physician entrepreneur, Jonathan Sackier.

**Listen today**

[www.emjreviews.com](http://www.emjreviews.com)

**EMJ**



# VECTRA<sup>H2</sup>

## The premier 3D solution for FACE, BREAST & BODY

Now also on macOS<sup>®</sup>



See the benefits of 3D imaging on  
[www.canfieldsci.com](http://www.canfieldsci.com)

 **CANFIELD**



VISIA<sup>®</sup>

Reveal<sup>®</sup>  
imager

IntelliStand

IntelliStudio<sup>®</sup>

VECTRA 3D

 HairMetrix<sup>®</sup>

 Mirror<sup>®</sup>

VECTRA, VISIA, Reveal, IntelliStudio, HairMetrix, and Mirror are registered trademarks of Canfield Scientific, Inc.

macOS is a trademark of Apple Inc., registered in the U.S. and other countries.

# EADV 2022



## Review of the European Academy of Dermatology and Venereology (EADV) Congress 2022

**Location:** Milan, Italy

**Date:** 7<sup>th</sup>–10<sup>th</sup> September 2022

**Citation:** EMJ Dermatol. 2022;10[1]:10-16. DOI/10.33590/emjdermatol/10054247.  
<https://doi.org/10.33590/emjdermatol/10054247>.

THIS YEAR, the European Academy of Dermatology and Venereology (EADV) adopted a pioneering hybrid format for its congress, allowing delegates to attend onsite in Milan, Italy, as well as online. Clinicians and academics came together with one common goal: to build an international community that develops, shares, and adopts best practices within the fields of dermatology and venereology. With over 600 speakers across more than 170 sessions, EADV President Alexander Stratigos expressed his belief that this year's EADV Congress "will allow you to innovate your daily practice and advance patient care with the best research." Stratigos continued: "The event will be a chance to reconnect with experts in your field and truly foster scientific collaboration."

Stratigos concluded the President's Letter by encouraging participants to "take part in this important appointment and join the entire dermatology and venereology community to immerse in science, innovation, and networking." This year's conference certainly embodied Stratigos' vision of the EADV experience.

As with previous EADV conferences, nail disorders were a key topic in the 2022 scientific programme, covering aspects such as onychoscopy, nail

psoriasis, onychomycosis, melanoma of the nail, and trachyonychia. Our compelling feature is based on one of these sessions, and explores best practices for onychomycosis, including updates in topical, oral, and combination treatments as well as recommendations for specialist referral. This is complemented by our EADV abstract highlights, which focus on dermoscopy when examining patients with nail psoriasis, and the use of a novel topical cosmetic plus systemic therapy to improve onychomycosis outcomes.

---

**"We are delighted to feature an abstract review describing a case of extragenital lichen sclerosus with a prominent rainbow pattern under polarised dermoscopy. Written by the presenters, this will hopefully prove a valuable resource for other practitioners when they encounter similar clinical scenarios."**

---



Furthermore, our EADV abstract highlights shine a light on urticaria, providing insights into sequifenadine for the treatment of chronic urticaria in patients after COVID-19; sharing results from a systematic review of familial aquagenic urticaria; and evaluating COVID-19 vaccination rates, vaccination reactions, and disease activations in patients with chronic spontaneous urticaria. In addition, we are delighted to feature an abstract review describing a case of extragenital lichen sclerosus with a prominent rainbow pattern under polarised dermoscopy. Written by the presenters, this will hopefully prove a valuable resource for other practitioners when they encounter similar clinical scenarios.

Summaries of highly relevant EADV press releases have also been included in this issue of *EMJ Dermatology*, outlining the development of a non-invasive skin immune biomarker test to aid in the prediction of paediatric eczema, the use of a novel imaging technique to improve the accuracy of diagnosis for basal cell carcinoma, and the association between vitamin D deficiency and overall survival for patients with skin cancer.

EADV Congress 2022 was notable for its range of nurse-dedicated events, with presentations on the key role of nurses and nurse practitioners in supportive oncodermatology, and the therapeutic education of patients with atopic dermatitis. Of note, EMJ had the unique

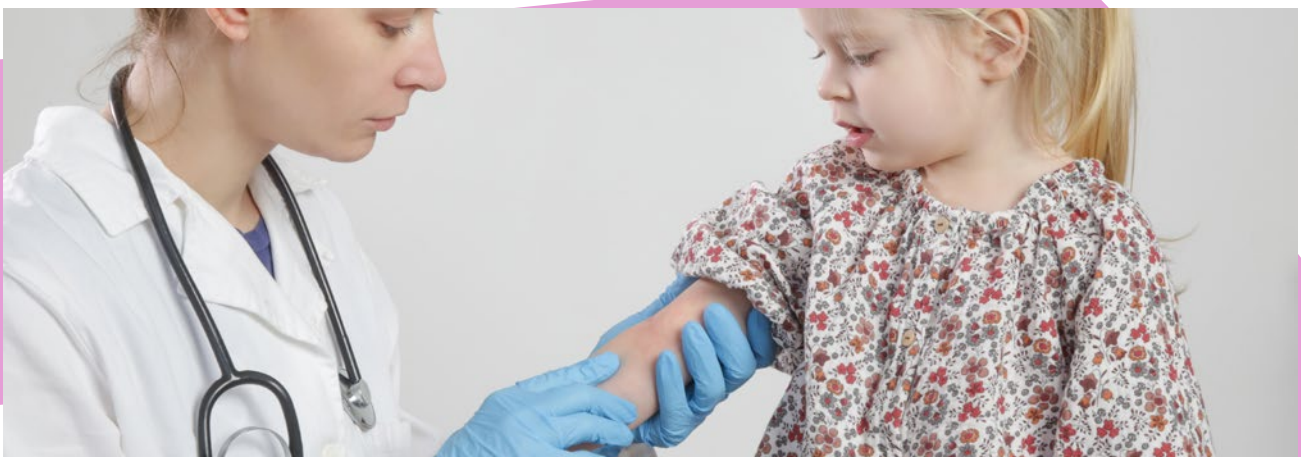opportunity to speak with Christa De Cuyper, Chair of the EADV Nurse Association Working Group and Task Force Facilitator. De Cuyper co-chaired the EADV's 2021 Nurses in Dermatology Practice event, and talked about the standout sessions and important take-home messages from this event. Moreover, De Cuyper discussed how the EADV can continue supporting the education of nurses and medical assistants in the dermato-venereology community. This interview can be found within the journal, and is not to be missed.

---

**"Of note, EMJ had the unique opportunity to speak with Christa De Cuyper, Chair of the EADV Nurse Association Working Group and Task Force Facilitator."**

---

Although EADV Congress 2022 has closed its doors, preparations are already underway for EADV Congress 2023. Whatever the future of dermato-venereology holds, the annual EADV Congress will remain crucial for the generation and exchange of scientific knowledge. With this in mind, we look forward to being part of the international dermatology and venereology community at next year's meeting in Berlin, Germany. Until then, read on for our key learnings from EADV Congress 2022. ●



## Predicting Paediatric Eczema Using Novel Skin Biomarker

ANALYSIS of tape strips, a painless and non-invasive skin cell collection method, taken from the skin of term and pre-term neonates, revealed an immune biomarker that predicts both the development and severity of atopic eczema in the first 2 years of life. This data was presented by lead author and co-researcher Anne-Sophie Halling, Department of Dermatology and Venereology, Bispebjerg Hospital, University of Copenhagen, Denmark, at the 31<sup>st</sup> EADV Congress, held in Milan, Italy, on 7<sup>th</sup> September 2022.

Tape strips from 450 babies were examined to identify whether any skin or immune biomarkers associated with development of paediatric atopic eczema could be identified. The strips were taken from the dorsal aspect of the hand at 0–3 days post-birth, and again at 2 months of age for babies born at term (n=300), and from the interscapular region of pre-term infants (n=150) once they had reached 2 months of age. The babies included in the study were subsequently followed up for 2 years for the development of atopic eczema.

The Barrier dysfunction in Atopic newBorns studY (BABY) found that raised levels of thymus and activation-regulated chemokine (TARC) at 2 months of age was associated with a more than two-fold likelihood of developing eczema in the first 2 years of life, irrespective of *filaggrin* gene mutations and parental atopy status. The study also found that higher levels of TARC were associated with increased

eczema severity. In addition to this, two further skin biomarkers, IL-8 and IL-18, were identified as being associated with moderate-to-severe paediatric atopic eczema. Halling highlighted that this is the first study showing how non-invasive skin biomarkers “can be used to predict the subsequent onset and severity of paediatric atopic eczema” and concluded that the study “provides a window of opportunity to develop targeted trials and prevent cases of eczema from occurring.”

These promising findings highlight how non-invasive identification of early-life skin biomarkers, such as elevated TARC levels, could enable healthcare professionals to develop and implement early and effective preventative and management strategies for these children, to help prevent and control their eczema symptoms, improve quality of life, and initiate treatment prior to developing severe symptoms or secondary complications, such as infection, occur. ●

---

**"Non-invasive identification of early-life skin biomarkers, such as elevated TARC levels, could enable healthcare professionals to develop and implement early and effective preventative and management strategies for these children."**

---

## Improvement in Accuracy of Diagnosis for Basal Cell Carcinoma

A NOVEL imaging technique has been found to significantly improve the accuracy of the diagnosis of basal cell carcinoma (BCC) when compared to clinical and dermoscopic examinations alone. BCC is primarily caused by sun exposure, or the use of tanning beds. This cancer subtype grows slowly, and rarely spreads. Worldwide, the incidence of BCC has doubled in the last two decades.

New research, carried out by the Department of Dermatology, Hôpital Erasme, Université Libre de Bruxelles, Belgium, was presented at the 31<sup>st</sup> EADV Congress in Milan, Italy. The study analysed instances of 303 lesions, including 173 BCC lesions and 130 BCC-imitators.

The study discovered that through the use of a new, non-invasive technology for skin imaging, called line-field confocal optical coherence tomography (LC-OCT), diagnosis is far more accurate. LC-OCT provides detailed three-dimensional images on a cellular level, and increased diagnostic accuracy for BCC in comparison to BCC-imitators (including seborrheic keratosis, inflammatory conditions, and squamous cell carcinoma) by 12% in comparison to dermoscopic examination, the current most commonly used skin cancer diagnostic technique (from 85% to 97%). Using LC-OCT also significantly increased diagnostic accuracy by 12% when differentiating between superficial BCC, a type which can be treated non-surgically, and other BCC subtypes (from 80% to 92%).

Researchers also produced a diagnostic algorithm, based on LC-OCT morphological criteria extracted from their comprehensive statistical analysis, as part of their study. This can be used to guide the clinician's diagnosis regarding different BCC and BCC-imitators.

Mariano Suppa, lead researcher and consultant dermatologist, commented:

---

**"LC-OCT has the potential to reduce the number of unnecessary biopsies and excisions in cases of superficial BCC, and also in the case of benign lesions that do not require surgery."**

---

"LC-OCT enables a more accurate diagnosis and, therefore, should be included in the diagnostic process and management of BCC." He added: "LC-OCT has the potential to reduce the number of unnecessary biopsies and excisions in cases of superficial BCC, and also in the case of benign lesions that do not require surgery."

It is hoped that LC-OCT imaging can aid clinicians in more accurately diagnosing BCC, a process which can prove a challenge using currently available clinical or dermoscopic assessments. ●



## Vitamin D Deficiency and Overall Survival in Melanoma

PATIENTS with vitamin D deficiency (<10 ng/mL) after a melanoma diagnosis are more likely to have a lower overall survival (OS) than patients with vitamin D levels of  $\geq 10$  ng/mL, according to a retrospective study presented at the 31<sup>st</sup> EADV Congress.

Melanoma develops when melanocytes grow uncontrollably. It accounted for 4% of new cancers in the European Union (EU) in 2020 and 1.3% of cancer deaths. Melanoma is more predominant in males than females (55,597 and 50,972 diagnoses, respectively), and was responsible for the deaths of 9,457 males and 7,031 females in the EU in 2020.

Lead Researcher Inés Garcia-Darder, Hospital University Con Espases, Mallorca, Spain, and colleagues analysed 264 patients with invasive melanoma at the Hospital Clinic of Barcelona, Spain. The analysis investigated the difference between OS and melanoma-specific survival, using Kaplan–Meir curves, Cox regression models, and other statistical techniques to control for confounding variables.

---

**“These findings suggest that vitamin D has a significant impact on people with melanoma, showing in particular that vitamin D deficient patients have a lower OS.”**

---

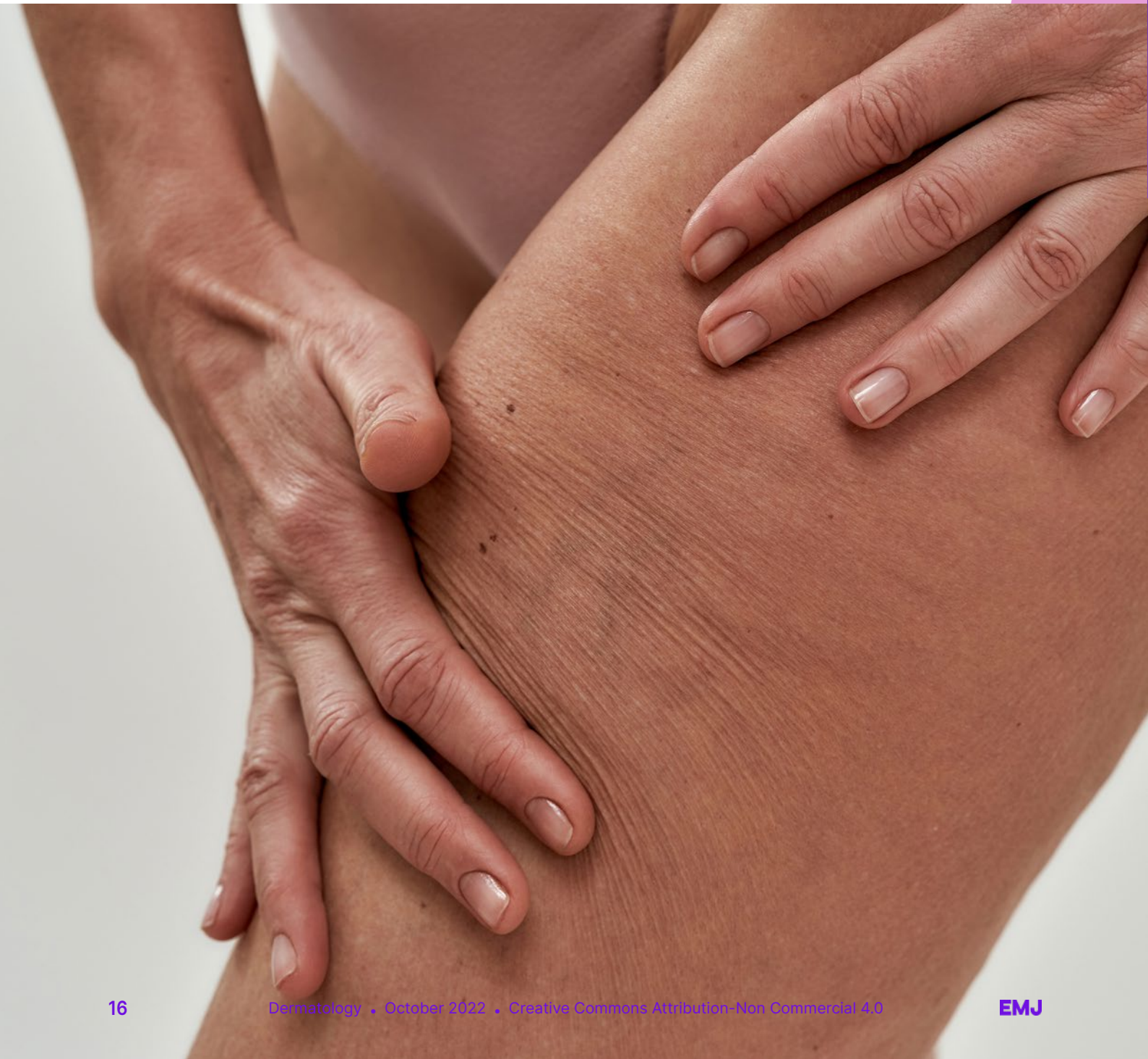Investigating if vitamin D has a protective role in melanoma survival, the researchers discovered that their findings contrasted with previous studies: basal characteristics at diagnosis were not associated with differences in vitamin D levels.

Deficiency did not appear to have an impact on melanoma-specific survival.

However, the research indicated that patients who are deficient in vitamin D were twice as likely to have a lower OS (hazard ratio: 2.3) than those with  $\geq 10$  ng/mL. Garcia-Darder stated: "These findings suggest that vitamin D has a

significant impact on people with melanoma, showing in particular that vitamin D deficient patients have a lower OS." When adjusted for sex, Breslow index, age, and the season, the findings remained significant (multivariate analysis hazard ratio: 2.4).

Garcia-Darder noted that while the "mechanisms underlying the association between vitamin D and melanoma OS" still needs research, they hope that this study encourages further research into whether vitamin D supplements will improve the prognosis and increase OS in patients with melanoma who are deficient in vitamin D. ●





# Interactive Medical Cases in Dermatology



A new initiative through which you can assess your diagnostic and therapeutic judgement. Work through the cases to test your clinical practice, where detailed explanations highlight learning points to grow your knowledge and skills.

## Wound Care

The patient is an 83-year-old female with rheumatoid arthritis presenting with a toe lesion. Learning is accompanied throughout by questions to test the correct clinical assessment and management of a chronic wound, also considering the sneaky risk of infections associated with the disease. The case is of particular interest as it is one of the few in chronic wounds care setting.

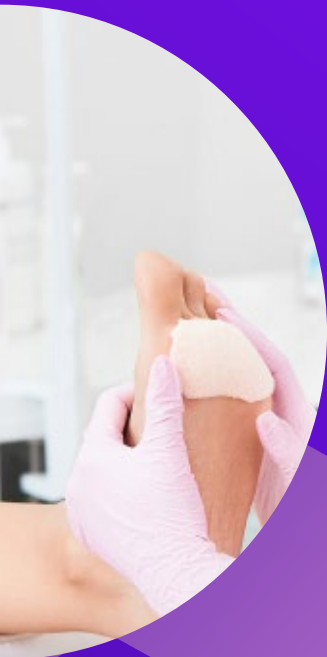Get started now



## Atopic Dermatitis

The patient is a 10-month-old child with moderate atopic dermatitis. Case details include a complete anamnesis and physical evaluation. Results of investigations highlight that a proper management is not only essential in treating the skin disease and preventing its worsening, but also the development of comorbidities or additional atopic diseases such as food allergy, asthma, and allergic rhinitis.

Get started now



This initiative was funded by Meda Pharma S.p.A, a Viatris company.

# Stay up to date with new advancements across European healthcare

Visit EMJ for our comprehensive collection of peer-reviewed research articles, latest interviews, and features across a range of therapeutic disciplines.

Visit EMJ

[www.emjreviews.com](http://www.emjreviews.com)

# EMJ



## Designing the Future of Dermatology and Venereology

### Authors:

Aslı Bilgic,<sup>1</sup> \*Dedee F. Murrell<sup>2,3</sup>

1. Department of Dermatology and Venereology, Akdeniz University, Faculty of Medicine, Antalya, Türkiye
2. Department of Dermatology, St George Hospital, Sydney, Australia
3. Faculty of Medicine, University of New South Wales, Sydney, Australia

\*Correspondence to [d.murrell@unsw.edu.au](mailto:d.murrell@unsw.edu.au)

### Citation:

EMJ Dermatol. 2022;10[1]:18-19. DOI/10.33590/emjdermatol/10176803. <https://doi.org/10.33590/emjdermatol/10176803>.


The European Academy of Dermatology and Venereology's (EADV) 31<sup>st</sup> Congress took place between 7<sup>th</sup> and 10<sup>th</sup> September 2022. This hybrid congress offered both a long-awaited onsite experience and the opportunity to attend virtually from across the globe. Over 600 speakers gathered in the beautiful city of Milan, Italy, to present over 170 sessions. Presentations of key research offered a chance for physicians and researchers to innovate their daily practice and advance patient care, whilst collaborating with colleagues from all around the world.

One of the main focuses of this year's congress was nail diseases. The scientific discussion started with a European Nail Society meeting on 7<sup>th</sup> September, and continued throughout the congress with multiple lectures on the topic. Michela Starace, Dermatologist at the University of Bologna, Italy, gave one of the most interesting talks, which centred on nutrition and nail diseases. This revealed that over-the-counter supplements are often used for nail fragility and nail disorders; however, there is a lot of interest and doubt on their actual benefit. Starace reviewed all the literature regarding vitamin and amino acid supplements (such as

zinc, biotin, vitamin D, nicotinamide, and L-cysteine) that are specifically used for nails, and found that although some studies suggest a benefit, the safety and efficacy data regarding their use is limited. One of the main problems is the lack of standardised treatment schedules for their use in different nail disorders; therefore, one should be careful to suggest them as a therapeutic option for specific diseases. Additionally, there is limited knowledge about their side effects as they are not under specific regulations like medications are, so there is a great need for large-scale randomised control trials in this area.

Another important focal point of the congress was hair disorders. The increasing worldwide prevalence of frontal fibrosing alopecia was one of the main topics discussed in this area by Ramon Grimalt, Faculty of Medicine and Health Sciences, Universitat Internacional de Catalunya (UIC), Barcelona, Spain. This cicatricial alopecia, which can cause irreversible hair loss, especially on the fronto-temporal hair line in females, is claimed to be associated with emollients, sunscreens, or other daily care products. Although there is no concrete evidence to support stopping their use, Grimalt

EADV 2022



emphasised that it is important for clinicians and researchers to understand the relation between the disease and these products when treating patients.

Current treatment approaches and future prospects in androgenetic alopecia, the most common hair loss type, was another hot topic presented by Sergio Vañó Galván, Grupo Español de Tricología, Madrid, Spain, and Academia Española de Dermatología y Venereología (AEDV), Madrid, Spain. Vañó Galván was enthusiastic about emerging therapies in the field especially with increasing options for this common, yet unsolved, problem.

Luís Puig, Universitat Autònoma de Barcelona School of Medicine, Spain, discussed the most important aspect of treatment safety and COVID-19 infection in his lecture during the COVID-19 panel. Puig emphasised that there is higher risk for hospitalisation and severe COVID-19 in patients who are immunosuppressed and not vaccinated. Recent systematic reviews suggest that there is no evidence that patients who receive systemic therapies and biologics have a higher risk of infection and/or increased risk of hospitalisation and death related to COVID-19 compared with the general population. This is especially demonstrated in patients with psoriasis

and rheumatologic diseases. However, it is important to consider that this may also be due to patients taking more protective measures during the pandemic compared with the public. A significant challenge was non-adherence to the therapy and compliance with the follow-up in the era of COVID-19. Thus, Puig suggested that physicians might choose therapies with longer half-lives, so if there are any problems with the treatment schedule, a sudden relapse can be avoided. The research is ongoing for patients to obtain better management of both the disease and their COVID-19 risk, especially in the high-risk populations.

Aside from these topics, attendees also enjoyed 10 exclusive plenary lectures with top-class speakers, hands-on workshops, patient and nurse dedicated events, sub-specialty sessions, and late-breaking abstract sessions. Those who were unable to participate onsite had access to the congress on livestream to ensure they did not miss out on this rich scientific experience.

The next EADV Symposium will be held in Seville, Spain, between 18<sup>th</sup> and 20<sup>th</sup> May 2023 and the next EADV Congress will take place in Berlin, Germany, between 11<sup>th</sup> and 15<sup>th</sup> October 2023. Join EADV to discover the latest updates in dermatology and venereology. ●



## Updates on Best Practices for Onychomycosis: Hitting the Nail on the Head

**Author:** Darcy Richards, Editorial Assistant

**Citation:** EMJ Dermatol. 2022;10[1]:20-24. DOI/10.33590/emjdermatol/10184052. <https://doi.org/10.33590/emjdermatol/10184052>.



**DURING** the 31<sup>st</sup> Annual European Academy of Dermatology and Venereology (EADV) Congress, 7<sup>th</sup>–10<sup>th</sup> September 2022, held both in-person in Milan, Italy, and virtually, experts delivered a session on the topic of nail disorders. The session, chaired by Michela Starace, University of Bologna, Italy, and Stamatis Gregoriou, National and Kapodistrian University of Athens, Greece, explored the complexity of nail disease and anatomy, the impact of diet on nail health, nail disorders in childhood, and fungal nail infections. Gregoriou delivered an insightful, up-to-date talk on the best practices for management of distal lateral subungual onychomycosis (DLSO), supported by recent data from clinical studies and the European Nail Society (ENS).<sup>1</sup>

### **HOW IS ONYCHOMYCOSIS DIAGNOSED AND WHY DOES IT MATTER?**

Onychomycosis commonly occurs in adulthood but can occur at any stage in life; however, incidence is rare in children. Fungal infection can affect nails of both fingers and toes, with toenail infection being more common. Onychomycosis can cause patient distress not only due to aesthetic dissatisfaction but also as a result of secondary complications, such as onychodystrophy and paronychia. Furthermore, the high rates of relapse and reinfection following treatment have a negative impact on both the patient and the health service.

Diagnosis is made through a combination of history, examination, onychoscopy, microscopy, fungal culture, and histology. There are several management options for the treatment of onychomycosis depending on the severity, as determined by the percentage of nail affected. The ENS conducted an online survey amongst

its members,<sup>1</sup> most of whom were European dermatologists specialising in nail disorders, with an average of 20 years clinical experience, in order to provide an updated consensus on the diagnosis and management of DLSO for non-specialists.

### **EXPERT ADVICE ON DIAGNOSIS OF ONYCHOMYCOSIS**

Gregoriou started by highlighting the results of this survey, which gave insight into how nail disease specialists manage patients in their clinics. The survey revealed that approximately 11% of patients presenting with nail disease in clinic had onychomycosis, of which 77% were diagnosed with DLSO.<sup>1</sup> According to the findings, the elements specialists implemented to make a diagnosis in the vast majority of consultations were asking the relevant medical history, often or always performing onychoscopy, often or always performing microscopic examination with potassium hydroxide and fungal culture, and often or always

EADV 2022



performing dermoscopy, with follow-up occurring in 100% of consultations.<sup>1</sup>

In terms of DLSO diagnostic recommendations for non-specialists, Gregoriou explained that history taking should consider predisposing factors such as current tinea pedis infection, immunosuppression, and diabetes, and that clinical examination should assess for subungual hyperkeratosis and yellow/orange nail discolouration, in addition to other diagnostic steps such as onychoscopy, microscopy and culture, and dermoscopy.

### **UPDATES ON TREATMENT**

Treatment options for onychomycosis include both topical and oral antifungals, as well as procedures such as laser therapy, nail debridement, or avulsion in more severe cases. Based on the ENS survey findings, it is recommended that response to treatment should be evaluated at follow-up every 3 months and consensus regarding decision to stop treatment should be based on

mycological cure, clinical cure, or both (complete cure).<sup>1</sup>

---

**"In terms of DLSO diagnostic recommendations for non-specialists, Gregoriou explained that history taking should consider predisposing factors such as current tinea pedis infection, immunosuppression, and diabetes, and that clinical examination should assess for subungual hyperkeratosis and yellow/orange nail discolouration."**

---

### Topical Treatment Updates

Of all the onychomycosis consultations reviewed by the ENS survey, 47% resulted in prescription of a topical antifungal,<sup>1</sup> which was considered the first-line therapy of choice when <50% of the nail was affected.

Gregoriou discussed how topical treatment advances for onychomycosis has been a “disappointing subject,” having seen “many new agents used” in the USA that have not been available in Europe. Gregoriou went on to discuss the results of a multicentre Phase III randomised controlled trial evaluating the efficacy of a 48-week course of terbinafine 10% solution in patients with mild-to-moderate, dermatophyte-positive DLSO, affecting 20–60% of at least one great toenail, in achieving mycological and complete cure.<sup>2</sup> Upon completion of the 48-week course and 4-week follow-up, 4.5% achieved complete cure compared with 0% in the control group. Furthermore, 69.9% achieved mycological cure compared with 27.7% in the control group. The cohort randomised to the terbinafine solution experienced negative fungal culture in 95.5% compared with 58.0% in the control group. By Week 52, ≤10% of the target toenail was affected in 19.1% of the terbinafine solution group compared with 8.4% in the control group.<sup>2</sup> No additional adverse events were observed with the terbinafine solution, demonstrating that terbinafine can reach sufficient concentrations in both the nail bed and plate to impose fungicidal activity.<sup>2</sup> Gregoriou commented how he hopes this treatment “will eventually be launched in Europe.”

### Oral Treatment Updates

The ENS survey detailed how oral antifungals were prescribed in 40% of onychomycosis consultations and that oral therapy was considered to be the first-line treatment used when either >50% of the nail was affected or infection involved the nail matrix.<sup>1</sup>

### Combination Treatment Updates

The survey results indicated that combination therapy with both topical and

oral antifungals or an oral antifungal alone was used in 70% of cases in which >50% of the nail was affected or the nail matrix was involved.<sup>1</sup>

Gregoriou also presented the results of a systematic review evaluating combination therapies of oral and topical medications or medications and procedures versus monotherapy,<sup>3</sup> which revealed that use of combination therapy led to a “significant clinical benefit” in 60% of cases. The review revealed that mycological cure rates were significantly higher when oral terbinafine and topical amorolfine were used in conjunction compared with oral terbinafine alone, whereas the combination of oral griseofulvin and topical tioconazole showed significantly higher complete cure rates, mycological cure rates, and lower relapse rates compared with griseofulvin oral monotherapy.<sup>3</sup> However, other combination studies evaluated, including oral itraconazole and topical amorolfine, revealed contradictory results.<sup>3</sup> Combining medication with a procedure such as debridement or laser therapy also led to a significant clinical benefit in 93.3% of studies when compared with medical monotherapy alone.<sup>3</sup> Given the limited number of studies in the review, and the conflicting results in the medical combination therapies, combination therapy should be considered as second-line therapy in cases where initial monotherapy has failed, the review concluded.<sup>3</sup>

---

**"Based on the ENS survey findings, it is recommended that response to treatment should be evaluated at follow-up every 3 months and consensus regarding decision to stop treatment should be based on mycological cure, clinical cure, or both (complete cure)."**

---

## ASSESSING RESPONSE TO TREATMENT

Assessing response to treatment can be measured in three different ways: mycological cure, defined as negative potassium hydroxide microscopy and culture; clinical cure, defined as an aesthetically 'normal-appearing' nail; and complete cure, defined as both mycological and clinical cure. When reviewing how the experts assess response to treatment, the ENS found that 54% of specialists used complete cure as a measure of response and 34% used clinical cure alone.<sup>1</sup> In addition to this, expert practice regarding decision to stop treatment demonstrated no definitive consensus, with 29% basing their decision on clinical cure alone, 29% on complete cure, and 22% on mycological cure alone.<sup>1</sup>

**"Gregoriou discussed how treating DLSO is 'complicated by high rates of reinfection' and emergence of terbinafine resistant *Trichophyton* species."**

Based on the above results, recommendations to non-experts in recognising treatment efficacy highlighted that there should be growth of a normal nail plate, normal nail colour, a reduction or absence of scales beneath the nails, and an absence of onycholysis.<sup>1</sup>

## UPDATES ON PROPHYLAXIS

Gregoriou discussed how treating DLSO is "complicated by high rates of reinfection" and emergence of terbinafine resistant *Trichophyton* species. When discussing the most important prophylactic measures, Gregoriou stressed the importance of disinfecting contaminated socks, highlighted by evidence from a Danish study showing that soaking socks for 24 hours in quaternary ammonium led to a 100% disinfection rate.<sup>4</sup> The study also assessed other disinfection methods such as freezing at -20 °C, which offered a 0% disinfection rate, and domestic washing at 40 °C with detergent, which only resulted in a 7.7% disinfection rate.<sup>4</sup> This method of prophylaxis is easy to implement by patients and could prove to be a highly effective preventative method; however, hyphae in skin and nail clippings may be more challenging to eliminate than those in clothing fibres.

Gregoriou also touched on how washing at 40 °C mimics the environment inside footwear. Therefore, it is recommended that patients should launder their socks at a minimum of 60 °C or soak them in quaternary ammonia for at least 24 hours.

## RECOMMENDATIONS FOR SPECIALIST REFERRAL

The outcome of the ENS survey<sup>1</sup> provided recommendations that non-experts should consider specialist referral if the initial presentation is with severe DLSO; if there is concurrent nail or skin psoriasis or a history





of additional nail disease; if the nail matrix is involved; if multiple nails are affected; if the patient is immunosuppressed, has uncontrolled diabetes, peripheral vascular disease, or polypharmacy; if there is progression of infection despite oral antifungal treatment; if either or both topical and oral treatments are not sufficient; and if there is the presence of dermatophytoma.

## CONCLUSION AND CLOSING

The session rounded-off with an interesting question and answer segment. One of the questions posed to Gregoriou centred around his preference in using pulsed versus continuous oral treatment protocols

for onychomycosis. Gregoriou explained that his preference was to use a continuous protocol as in “most cases” this yields a better result; however, he did highlight that a pulsed protocol can be used if there are concerns regarding patient comorbidities or abnormal biochemical profiles. Taking this further, Gregoriou commented that if there are concerns about the safety profile, debridement and topical treatment can be used as an alternative.

The key updates from this insightful presentation provide clinicians without specialist knowledge in nail disease with a useful framework for diagnosis, treatment, prophylaxis, and guidance on when to refer to an expert in nail disorders. ●


### References

1. Piraccini BM et al.; A working group of the European Nail Society. Onychomycosis: recommendations for diagnosis, assessment of treatment efficacy, and specialist referral. The CONSONANCE consensus project. *Dermatol Ther (Heidelb)*. 2022;12(4):885-98.
2. Gupta AK et al. Efficacy and safety of topical terbinafine 10% solution (MOB-015) in the treatment of mild to moderate distal subungual onychomycosis: a randomized, multicenter, double-blind, vehicle-controlled phase 3 study. *J Am Acad Dermatol*. 2021;85(1):95-104.
3. Falotico JM et al. Combination therapy should be reserved as second-line treatment of onychomycosis: a systematic review of onychomycosis clinical trials. *J Fungi (Basel)*. 2022;8(3):279.
4. Skastrup KN. Disinfection trials with terbinafine-susceptible and terbinafine-resistant dermatophytes. *Mycoses*. 2022;65(7):741-6.



# Photoprotection and the Science Behind Skin Healing

These presentations took place on September 9<sup>th</sup> 2022 as part of the 31<sup>st</sup> European Academy of Dermatology and Venereology (EADV) Congress in Milan, Italy, and online



<b>Speakers:</b>	Jean-Michel Amici, <sup>1</sup> Delphine Kerob, <sup>2</sup> Thierry Passeron, <sup>3</sup> Susana Puig <sup>4</sup>
	<ol style="list-style-type: none"> <li>1. Université Bordeaux, France</li> <li>2. La Roche-Posay Laboratoires, Paris, France</li> <li>3. University of Nice Sophia Antipolis, France</li> <li>4. University of Barcelona, Spain</li> </ol>
<b>Disclosure:</b>	Amici has acted as a consultant for L'Oréal and NAOS. Kerob is an employee of La Roche-Posay and L'Oréal. Passeron has received research grants and honoraria from Beiersdorf, Galderma, Hyphens, L'Oréal, ISDIN, ISIS Pharma, NAOS, Pierre Fabre, SUN Pharma, SVR Pharma and Symrise. Puig has acted as a speaker, has been on the advisory board, and involved in research and trials for Almirall, BMS, ISDIN, La Roche Posay, Leo Pharma, Novartis, and Roche; as a speaker and in research and trials for MSD; as a speaker and on the advisory board for Pfizer, Regeneron, and Sanofi; and in research and trials for AbbVie, Amgen, Biofrontera, Canfield, Cantabria, Fotofinder, GSK, MEDA, and Polychem; and on the advisory board for Sun Pharma. Puig has also been involved in educational activities for AbbVie and Eli Lilly, and in the start-up of Athena Tech & Dermavision Solutions.
<b>Acknowledgements:</b>	Writing assistance was provided by Eleanor Roberts, Beeline Science Communications, Ltd, London, UK, funded by EMJ.
<b>Support:</b>	This article was funded by an educational grant from L'Oréal Dermatological Beauty.
<b>Disclaimer:</b>	The opinions expressed in this article belong solely to the named speakers.
<b>Citation:</b>	EMJ Dermatol. 2022;10[1]:25-31. DOI/10.33590/emjdermatol/10058317. <a href="https://doi.org/10.33590/emjdermatol/10058317">https://doi.org/10.33590/emjdermatol/10058317</a> .



## Meeting Summary

In the first of two sessions from the 31<sup>st</sup> European Academy of Dermatology and Venereology (EADV) Congress, Thierry Passeron, University of Nice Sophia Antipolis, France, presented a large international survey that showed that while people are aware of the dangers of sun exposure, many still seek to tan and do not use or may not understand protective measures. In the second half of this session, Susana Puig, University of Barcelona, Spain, discussed data on the use of a high factor, broad-spectrum sunscreen combined with nicotinamide and panthenol. In people with photodamaged skin, the cream was shown to downregulate genes involved in apoptosis, the immune system, and cancer and upregulate collagen genes. In people with actinic keratosis (AK) and its precursor, field cancerisation (FC), treatment led to downregulation of genes involved in a number of signalling

pathways, including those implicated in cancer, the cell cycle, and apoptosis. In the second session, Jean-Michel Amici, Université Bordeaux, France, discussed the wound healing process and the role of the immune system and skin microbiome. Delphine Kerob, La Roche-Posay Laboratoires, Paris, France, then presented data from a survey of people with scars that revealed how redness, itching, pain, and burning could persist for at least a year in some people, and skin discomfort can impact quality of life (QoL). Kerob also presented findings from recent studies of effects of the cream Cicaplast Baume B5+® (La Roche-Posay, L'Oréal UK Ltd, London, UK). Cicaplast Baume B5+, which contains a prebiotic complex as well as panthenol, madecassoside, and moisturisers, showed positive effects on skin healing following laser treatment for skin damage.

## Introduction

Sun exposure can lead to tanning, but also to skin damage due to the actions of ultraviolet A and B, visible light, and infrared radiation.<sup>1,2</sup> One result of sun exposure is field cancerisation (FC), the precursor to actinic keratosis (AK), which in turn is a risk factor for, most notably, squamous cell carcinoma.<sup>3</sup> Daily sunscreen use can prevent the development of AK, decrease pre-existing AK, improve FC, and help prevent skin cancer.<sup>4,5</sup>

## Insights From a Large International Study of Sun Exposure and Associated Risks

### Thierry Passeron

To gain insight into how people view sun exposure, Passeron presented a survey conducted in 17 countries spanning all but the polar continents. This included 17,001 adults, predominantly Fitzpatrick skin phototypes II (fair skin, blue eyes, tans poorly, burns easily) and III (darker white skin that tans after initially burning), but spanning all phototypes.<sup>6</sup>

While the majority of respondents agreed with statements saying that sun exposure can cause skin health problems and accelerate skin aging, they also agreed that the sun helps them synthesise vitamin D, gives them energy, and that a tan makes a person look healthy and attractive. Three-quarters also never or very infrequently had moles checked by a dermatologist.

Protection from the sun can include using a suitable sunscreen, covering the body with

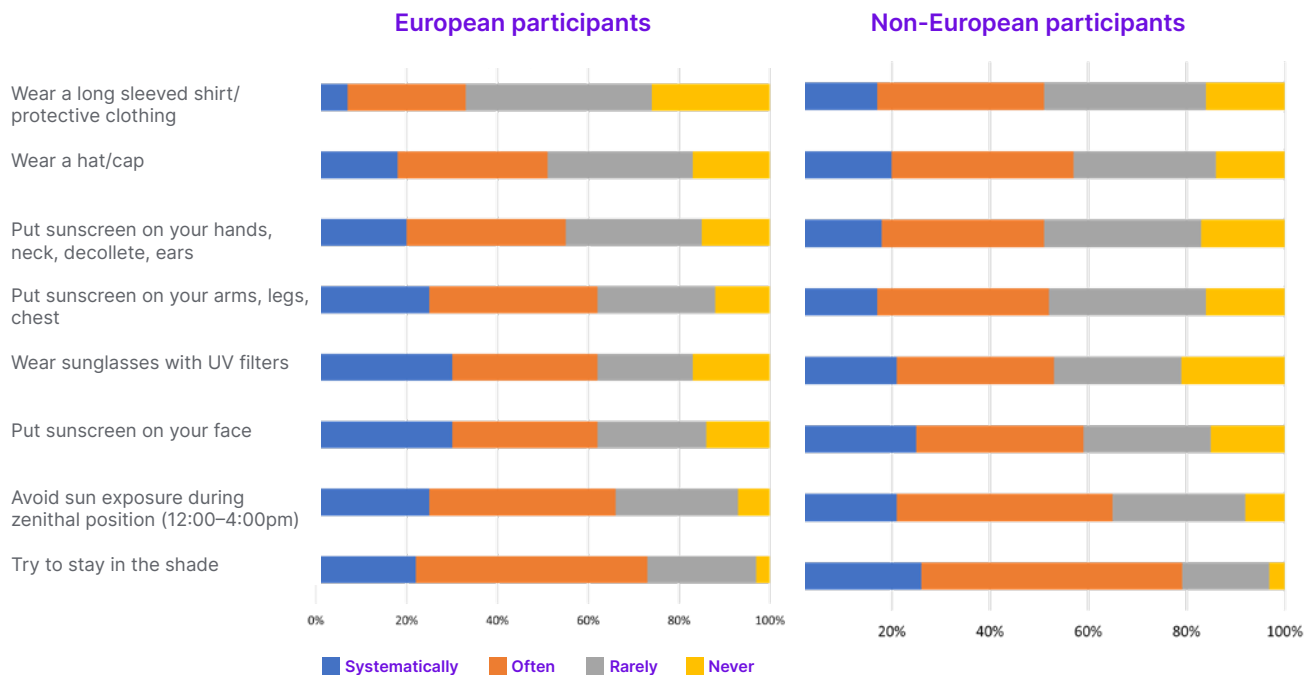
clothing and headwear, and staying in the shade.<sup>7,8</sup> Figure 1 shows that few people systematically use such protection, with some people never doing so.

Overall, only 10% of Europeans and 14% of non-Europeans were found to systematically or regularly undertake all the protective measures shown in Figure 1. This rose to only 21% in a cohort of 655 Europeans considered at risk to sun exposure as a result of skin conditions such as skin cancer and photodermatoses, or who were using a sun-limiting medication.

Sunscreen should be used regularly, year round, every 2–3 hours, even on cloudy days.<sup>8</sup> In this survey, most respondents only used sun protection when on vacation, two-thirds said they sought to tan with sun protection, a quarter believed that sun exposure without sunscreen is safe if they are already tanned, and many thought that sunscreen with sun protection factor (SPF)  $\geq 50$  is only for those who are at risk from sun exposure.

Additionally, it was found that two-thirds of Europeans and three-quarters of non-Europeans only applied sunscreen once or twice a day, and many did not use sun protection on cloudy days. It was also found that between one-half and three-quarters of respondents did not understand the differences in the various wavelengths of electromagnetic radiation that can affect the skin, or in SPF values.<sup>1,2</sup>

Passeron concluded by stating: “We have a lot of work to do [...] as most individuals are not protecting themselves and don't care most of the time.”

Figure 1: European and non-European habits with regard to sun protection.<sup>6</sup>

UV: ultraviolet.

## A Sunscreen Formula for Photodamage and Actinic Keratosis

Susana Puig

Puig presented a study investigating whether a high factor, broad-spectrum sunscreen combined with nicotinamide and panthenol could repair skin photodamage. Fourteen adults (phototypes II–III) applied the sunscreen daily to photodamaged skin on the external forearm and ‘healthy’ non-photodamaged skin on the internal forearm for 4 weeks. Biopsies were taken at baseline and study end.

After 4 weeks of use, small, non-significant decreases were found in measures of stratum corneum integrity, epidermal thickness (plus or minus the stratum corneum), dermal–epidermal junction undulation, and keratinocyte quantification. Analysis of cell damage markers in the biopsies also showed small, non-significant decreases.

Pre-treatment RNA sequencing revealed that 1,552 genes were significantly

differentially expressed between healthy and photodamaged skin. Genes significantly upregulated in photodamaged skin compared with healthy skin are shown in Table 1, and include those involved in collagen degradation and apoptosis.<sup>9,10</sup> Comparing pre- to post-sunscreen exposure in photodamaged skin showed that 5,429 genes were significantly differently expressed. Pathways that were significantly downregulated are shown in Table 1 and include those involved in the cell cycle, apoptosis, the immune system, cell communication, cellular energy, and cancer.<sup>11–13</sup> Significant upregulation was shown in a number of collagen genes.

A second study evaluated the effects of the sunscreen for repairing AK and FC in 20 patients who applied the cream for 8 weeks. From the data obtained of differences between FC and AK at pre- and post-treatment, a model was developed whereby AK progression from FC includes increases in stratum corneum and living epidermal thickness; keratinocyte layer number, volume, cytoplasm, and atypia; and dermal–epidermal junction undulation.

Table 1: RNA sequencing analysis of gene expression<sup>10</sup>

Signalling pathway	Change	P value
<b>From Group 1 to Group 2</b>		
MAPK (degradation of fibrillar Type 1 collagen)	↑	0.044
cGMP-PKG (apoptosis)	↑	0.044
<b>From Group 2 to Group 3</b>		
Epidermal growth factor B signalling	↓	<0.0001
Hippo signalling	↓	<0.0001
NOD-like receptor	↓	<0.0001
TNF	↓	<0.0001
NF-κB	↓	0.00017

Group 1: healthy samples; Group 2: lesion (photodamage) pre-treatment samples; Group 3: lesion (photodamage) post-treatment samples.

cGMP-PKG: cyclic guanosine monophosphate-protein kinase G; MAPK: mitogen-activated protein kinase; NF-κB: nuclear factor κ-light-chain-enhancer of activated B cells; NOD: nucleotide-binding oligomerisation domain.

Treatment reduced living epidermis thickness and number of keratinocyte layers in the AK areas and average volume and variability of keratinocyte nuclei in the FC areas.

AK and FC biopsy analysis showed significant decreases in expression of the cell cycle protein p21 and increases in thymine dimers following treatment. Skin damage that was previously present was also reduced. RNA sequencing data showed 1,555 differently expressed genes in the AK samples and 40 in the FC cases. Pathways downregulated in AK samples post-treatment included those involved in p53 signalling, cell communication, proteoglycans associated with cancer, apoptosis, muscle contraction, and sphingolipids. Pathways downregulated in both AK and FC included those involved in cancer, cell cycle, and glucose homeostasis.<sup>14,15</sup>

Puig concluded that “high broad spectrum photoprotection is able to reverse some photodamage and modulate DNA repair and carcinogenesis genes.”

## The Process of Wound Healing and the Role of the Microbiome

### Jean-Michel Amici

Amici discussed the four main stages of wound healing. Initially, haemostasis involves vasoconstriction and the formation of a fibrin clot to control bleeding and provide a scaffold for immune cells.<sup>16,17</sup> Next is inflammation, involving recruitment and activation of phagocytic cells to sterilise the wound and clear the site,<sup>18</sup> and macrophages to engulf apoptotic and necrotic cells and pathogens.<sup>16</sup> The degree of response at this stage can impact the following stages.<sup>18</sup>

The next stage is proliferation of keratinocytes, endothelial cells, and fibroblasts. These cells help in formation of granulation tissue,<sup>19</sup> wound re-epithelialisation,<sup>18,19</sup> and myofibroblast accumulation, which contracts the wound to decrease surface area.<sup>18</sup> At 2–3 weeks post-injury, granulation tissue has formed, covered with new epithelial cells.<sup>20</sup> The final stage, remodelling, can last for over a year.<sup>21</sup> Here, collagen is realigned to form an organised

network and there is extensive extracellular matrix remodelling.<sup>18</sup> Also taking place is apoptosis of endothelial cells, fibroblasts, and macrophages.<sup>22</sup> The result of this process is collagenous scar formation that increases the overall strength of the repaired skin.<sup>18</sup>

During wound healing, the co-ordinated response involves adaptive immunity, which can help fight infection and is essential for proper wound resolution and innate immunity, involving pathogen response and the production of antimicrobial peptides (AMPs). Two major AMPs, cathelicidins and defensins, are produced by keratinocytes and aid in modulating the innate immune response and activating adaptive immunity.<sup>23</sup>

The skin microbiome includes commensal micro-organisms in the form of bacteria (including *Staphylococcus*, *Corynebacterium*, and *Cutibacterium* species), mites, and fungi. It helps maintain skin acidification, create a hostile environment for pathogens, and in induction of host AMPs and antimicrobial molecules.<sup>23-26</sup> For example, *Staphylococcus epidermidis* can activate toll-like receptor-2 signalling to induce keratinocyte AMP expression.<sup>23,27,28</sup> In wound healing, *S. epidermidis* can induce CD8<sup>+</sup> T-cells, triggering the upregulation of immune regulation and tissue repair-related genes, improving re-epithelisation of affected skin and accelerating wound repair.<sup>29-31</sup>

Many factors can influence wound healing, including the wound's cause and location and a person's age, phototype, nutrition status, and comorbidities. There can also be complications, such as atrophic, hypertrophic, and keloid scars; chronic wound occurrence; and superinfection.<sup>32</sup>

In Amici's view, what is needed to improve wound healing is a balanced skin microbiome to limit pathogen colonisation and increase AMP production; control of inflammation to avoid post-inflammatory hyperpigmentation and abnormal scarring; and a synergistic relationship between the immune system and the skin microbiome to help accelerate wound repair and improve re-epithelialisation.

## The Impact of Scars

### Delphine Kerob

Symptoms associated with wound healing, discussed Kerob, include pain, itching, bruising, inflammation, erythema, desquamation, and scab formation. Supportive measures for managing scars for an optimal outcome include basic wound cleaning, healing optimisation, photoprotection, and corrective makeup to help protect healing skin and improve QoL during scar formation.<sup>33</sup>

A large international epidemiological survey, involving 11,100 adults (18–74 years) from China, Brazil, the USA, Russia, and France, was conducted to assess the impact of scars on a patient.<sup>34</sup> Respondents included an almost equal number of males and females, predominantly phototypes III–IV, but with the inclusion of all phototypes. About half of respondents had a scar due to an accident, illness, or surgery, with 78% having them for >1 year (n=4,186).<sup>34</sup>

Overall, 44% of respondents with newer scars (<1 year) reported redness, 35% itching, 29% pain, and 24% burning. While at significantly lower levels, these sensations were still reported by people with scars <1 year old, with respective values of 19%, 15%, 12%, and 10%. However, few people used any treatment for scar management, with only 11–13% prescribed a healing cream, antibiotic ointment, or antiseptic solution and 5–11% using a repairing cream, moisturising cream, massage, or scar camouflage product. Additionally, only 31% of respondents said they protected the scar from the sun, with only 47% using an SPF sunscreen. Of these, most used one with a high (29%) or very high (47%) SPF.<sup>34</sup>

This survey also found that having a scar can impact a person's QoL, with scores on a measure of such higher in the first few months, then decreasing after 1 year, though, for some, still showing some QoL impacts at this time. In respondents that reported skin discomfort, their symptoms significantly impacted several aspects of life, including leisure activities, clothing choice, and intimacy, compared with those without skin discomfort.

Kerob concluded that “understanding the process of scarring is key to recommending proper skin care and improving outcomes.”

## Wound Healing Management

Kerob also presented several studies regarding the effects of the topical cream Cicaplast Baume B5+, which contains Tribioma, a prebiotic complex including inactivated bacteria, yacoon root extract, and sugars. Other ingredients are shea butter, glycerine, panthenol, madecassoside, zinc, manganese, and spring water.

A randomised controlled trial conducted in China included 84 predominately female participants aged 34–50 years with skin damage in the form of facial pores, acne scars, photoaging, etc. Participants underwent a non-ablative fraction laser procedure, and were then treated with a collagen dressing applied once every 2 days for 14 days. Half of the participants also applied Cicaplast Baume B5+ twice a day. Significant differences in favour of Cicaplast Baume B5+ included increased hydration and sebum content as well as decreased water loss, erythema index, and melanin index. There were also fewer adverse events in the Cicaplast Baume B5+ group.<sup>35</sup>

The second study, also in China, was conducted with 45 females (25–50 years; phototypes III–IV) with atrophic acne scars or pores. They underwent ablative fractional CO<sub>2</sub> laser resurfacing on both sides of the face. On one half of the face, Cicaplast Baume B5+ was applied, on the other, the regular hospital-issued emollient was used. Significant differences were shown in favour of Cicaplast Baume B5+ for scab shedding time, erythema index, and water loss.<sup>36</sup>

The next study, conducted in Thailand, included 12 males and eight females (16–46 years; phototypes III–V) with atrophic acne scars. Following fractional CO<sub>2</sub> laser resurfacing, Cicaplast Baume B5+ was applied to half the face and a 0.02% triamcinolone acetonide cream to the other half, twice daily for 7 days. At all timepoints, to Day 60, there were no significant differences between the treatments in terms of redness, crusting and scaling, or post-inflammatory hyperpigmentation. There were no serious side effects.<sup>37</sup>

An open-label study in Poland and Mauritius, presented as part of this session, involved 52 participants (3–70 years old; phototypes I–V) with skin irritation conditions, including a superficial burn, dry patch, or cheilitis. Participants applied Cicaplast Baume B5+ at least twice a day for 14–24 days. There was progressive complete recovery over the time period, with 70% completely healed by Day 21. Significant improvements, favouring Cicaplast Baume B5+, were shown for erythema, cracks, and oedema. Pain and pruritus also significantly improved immediately after first application of Cicaplast Baume B5+. Clinical scores showed significant improvements from the start to the end of the trial.

In conclusion, Kerob said that “Cicaplast Baume B5+® is a suitable skin care (product) for superficial wounds and post-procedures.”

### References

- Krutmann J et al. The skin aging exposome. *J Dermatol Sci.* 2017;85(3):152-61.
- Dupont E et al. Beyond UV radiation: a skin under challenge. *Int J Cosmet Sci.* 2013;35(3):224-32.
- Gilchrist BA. Actinic keratoses: reconciling the biology of field cancerization with treatment paradigms. *J Invest Dermatol.* 2021;141(4):727-31.
- Thompson SC et al. Reduction of solar keratoses by regular sunscreen use. *N Engl J Med.* 1993;329(16):1147-51.
- Perugini P et al. Topical sunscreen application preventing skin cancer: systematic review. *Cosmetics.* 2019;6(3):42.
- Fitzpatrick TB. The validity and practicality of sun-reactive skin types I through VI. *Arch Dermatol.* 1988;124(6):869-71.
- Moyal D. Need for a well-balanced sunscreen to protect human skin from both ultraviolet A and ultraviolet B damage. *Indian J Dermatol Venereol Leprol.* 2012;78(Suppl 1):S24-30.
- Passeron T et al. Photoprotection according to skin phototype and dermatoses: practical recommendations from an expert panel. *J Eur Acad Dermatol Venereol.* 2021;35(7):1460-9.
- Muthusamy V, Piva TJ. The UV response of the skin: a review of the MAPK, NFkappaB and TNFalpha signal transduction pathways. *Arch Dermatol Res.* 2010;302(1):5-17.
- Gong L et al. Propranolol selectively inhibits cervical cancer cell growth by suppressing the cGMP/PKG pathway. *Biomed Pharmacother.* 2019;111:1243-8.
- Wang X et al. Nicotinamide adenine dinucleotide treatment alleviates the symptoms of experimental autoimmune encephalomyelitis by activating autophagy and inhibiting the NLRP3 inflammasome. *Int Immunopharmacol.* 2021;90:107092.
- Kondo S. The roles of cytokines in photoaging. *J Dermatol Sci.* 2000;23(Suppl 1):S30-6.
- Han SH et al. Anti-photoaging

- effect of hydrolysates from pacific whitening skin via MAPK/AP-1, NF- $\kappa$ B, TGF- $\beta$ /Smad, and Nrf-2/HO-1 signaling pathway in UVB-induced human dermal fibroblasts. *Mar Drugs*. 2022;20(5):308.
14. Hynes NE, MacDonald G. ErbB receptors and signaling pathways in cancer. *Curr Opin Cell Biol*. 2009;21(2):177-84.
  15. Zenonos K, Kyprianou K. RAS signaling pathways, mutations and their role in colorectal cancer. *World J Gastrointest Oncol*. 2013;5(5):97-101.
  16. Wilkinson HN, Hardman MJ. Wound healing: cellular mechanisms and pathological outcomes. *Open Biol*. 2020;10(9):200223.
  17. Ellis S et al. Immunology of wound healing. *Curr Dermatol Rep*. 2018;7(4):350-8.
  18. Boothby IC et al. Regulatory T cells in skin injury: at the crossroads of tolerance and tissue repair. *Sci Immunol*. 2020;5(47):eaaz9631.
  19. Karppinen SM et al. Toward understanding scarless skin wound healing and pathological scarring. *F1000Res*. 2019;8.
  20. Marshall CD et al. Cutaneous scarring: basic science, current treatments, and future directions. *Adv Wound Care (New Rochelle)*. 2018;7(2):29-45.
  21. Tottoli EM et al. Skin wound healing process and new emerging technologies for skin wound care and regeneration. *Pharmaceutics*. 2020;12(8):735.
  22. Broughton G 2nd et al. The basic science of wound healing. *Plast Reconstr Surg*. 2006;117(Suppl 7):12S-34S.
  23. Swaney MH, Kalan LR. Living in your skin: microbes, molecules, and mechanisms. *Infect Immun*. 2021;89(4):e00695-20.
  24. Byrd AL et al. The human skin microbiome. *Nat Rev Microbiol*. 2018 ;16(3) :143-55.
  25. Leonel C et al. Staphylococcus epidermidis role in the skin microenvironment. *J Cell Mol Med*. 2019;23(9):5949-55.
  26. Chen YE et al. Skin microbiota-host interactions. *Nature*. 2018 ;553(7689) :427-36.
  27. Lai Y et al. Activation of TLR2 by a small molecule produced by Staphylococcus epidermidis increases antimicrobial defense against bacterial skin infections. *J Invest Dermatol*. 2010;130(9):2211-21.
  28. Mookherjee N et al. Antimicrobial host defence peptides: functions and clinical potential. *Nat Rev Drug Discov*. 2020;19(5):311-32.
  29. Linehan JL et al. Non-classical immunity controls microbiota impact on skin immunity and tissue repair. *Cell*. 2018;172(4):784-96. e18.
  30. Harrison OJ et al. Commensal-specific T cell plasticity promotes rapid tissue adaptation to injury. *Science*. 2019;363(6422):eaat6280.
  31. Belkaid Y, Harrison OJ. Homeostatic immunity and the microbiota. *Immunity*. 2017;46(4):562-76.
  32. Martin P, Nunan R. Cellular and molecular mechanisms of repair in acute and chronic wound healing. *Br J Dermatol*. 2015;173(2):370-8.
  33. Jourdan M et al. Skin care management for medical and aesthetic procedures to prevent scarring. *Clin Cosmet Investig Dermatol*. 2019;12:799-804.
  34. Amici JM et al. Prevalence of scars: an international epidemiological survey in adults. *J Eur Acad Dermatol Venereol*. 2022;36(10):e799-800.
  35. Zhang Q et al. Effect of cream containing asiaticoside and 5% panthenol on skin repair after non-ablative fractional laser surgery. *Chin J Med Aesth*. 2022;28(1):9-12.
  36. Li W et al. Effects of a cream containing madecassoside, 5% panthenol, and copper-zinc-manganese on improving postlaser resurfacing wound healing: a split-face, randomized trial. *Dermatol Ther*. 2020;33(4):e13533.
  37. Lueangarun S et al. Efficacy and safety of moisturizer containing 5% panthenol, madecassoside, and copper-zinc-manganese versus 0.02% triamcinolone acetonide cream in decreasing adverse reaction and downtime after ablative fractional carbon dioxide laser resurfacing: a split-face, double-blinded, randomized, controlled trial. *J Cosmet Dermatol*. 2019;18(6):1751-7.

FOR REPRINT QUERIES PLEASE CONTACT: [INFO@EMJREVIEWS.COM](mailto:INFO@EMJREVIEWS.COM)

# Clinical Efficacy and Outcomes of Remibrutinib (LOU064) in Patients with Chronic Spontaneous Urticaria Inadequately Controlled with H<sub>1</sub>-Antihistamines: Findings from a Phase IIb Study

This congress report is based on five poster presentations that took place between 7<sup>th</sup> and 10<sup>th</sup> September 2022, as part of the 31<sup>st</sup> European Academy of Dermatology and Venereology (EADV) Annual Congress held in Milan, Italy, and online



## Speakers:

Marcus Maurer,<sup>1-4</sup> Ana Giménez-Arnau,<sup>5</sup> Martin Metz<sup>1-4</sup>

1. Urticaria Center of Reference and Excellence (UCARE), Institute of Allergology, Charité – Universitätsmedizin Berlin, Germany
2. Freie Universität Berlin, Germany
3. Humboldt-Universität zu Berlin, Germany
4. Fraunhofer Institute for Translational Medicine and Pharmacology ITMP, Allergology and Immunology, Berlin, Germany
5. Department of Dermatology, Hospital del Mar, IMIM (UCARE), Universitat Pompeu Fabra, Barcelona, Spain

## Disclosure:

Maurer is or recently was a speaker and/or advisor for and/or has received research funding from Amgen, Allakos, Aralez, AstraZeneca, Celldex, FAES, Genentech, GI Innovation, Kyowa Kirin, Leo Pharma, Menarini, Novartis, Moxie, MSD, Roche, Sanofi, Third Harmonic, UCB, and Uriach. Giménez-Arnau reports roles as a Medical Advisor for Uriach Pharma, Sanofi and Genentech, Novartis, FAES, GSK, AMGEN, and Thermo Fisher Scientific; has held research grants supported by Uriach Pharma, Novartis, and Instituto Carlos III FEDER; and also participates in educational activities for Uriach Pharma, Novartis, Genentech, Menarini, LEO PHARMA, GSK, MSD, Ammirall, AVENE, and Sanofi. Metz reports personal fees from Amgen, Aralez, Argenx, AstraZeneca, Celldex, Moxie, Novartis, Roche, Sanofi, and Uriach.

## Acknowledgements:

Medical writing assistance was provided by Claire Fielden, Birmingham, UK.

## Support:

The publication of this article was funded by Novartis Pharma AG.

## Disclaimer

The views and opinions expressed are those of the authors and not necessarily those of Novartis Pharma AG.

## Citation:

EMJ Dermatol. 2022;10[1]:32-39. DOI/10.33590/emjdermatol/10053856. <https://doi.org/10.33590/emjdermatol/10053856>.





## Summary

As part of the 31<sup>st</sup> European Academy of Dermatology and Venereology (EADV) Annual Congress held in Milan, Italy, and online, 7<sup>th</sup>–10<sup>th</sup> September 2022, five poster presentations outlined results from the Phase IIb study of remibrutinib (LOU064) in patients with chronic spontaneous urticaria inadequately controlled with H<sub>1</sub>-antihistamines. These posters presented data on quality of life, the need for antihistamine rescue medication to address symptoms, the time to complete urticaria control, and the safety profile of remibrutinib. The findings were outlined in these poster presentations and are summarised here.

## Background

Chronic spontaneous urticaria (CSU) is characterised by the spontaneous occurrence of wheals (hives) and/or angioedema for  $\geq 6$  weeks.<sup>1</sup> CSU can persist for several years and is associated with severe pruritus.<sup>1</sup> Skin mast cell activation in CSU occurs via Type I autoallergy driven by IgE to autoallergens, and a Type IIb autoimmune response due to mast cell-targeted autoantibodies against IgE or high-affinity IgE receptor.<sup>2</sup>

International clinical guidelines published in 2022 state that the goal of urticaria treatment is to achieve complete symptom control safely and effectively, with normalisation of quality of life (QoL).<sup>3</sup> However, real-world evidence from the ASSURE-CSU study,<sup>4</sup> the AWARE study,<sup>5</sup> and the 2-year follow-up of the AWARE study<sup>6</sup> confirmed that in many patients CSU remains uncontrolled, undertreated, and associated with a high healthcare resource use burden, with a detrimental effect on QoL, work, sleep, and other activities.<sup>4–6</sup>

Second-generation, non-sedating H<sub>1</sub>-antihistamines at approved doses are currently recommended as first-line therapy for all types of urticaria.<sup>3</sup> However, up to 60% of patients do not respond adequately within 2–4 weeks of starting treatment with H<sub>1</sub>-antihistamines and require increased doses (up to four-fold of the licensed dose) as second-line therapy before other treatments are considered.<sup>3,7</sup> For many patients, the current treatments inadequately control the symptoms that impact their QoL.<sup>7–9</sup> Hence, there is a considerable unmet need for effective and safe oral therapies for CSU with novel mechanisms of action.<sup>10</sup>

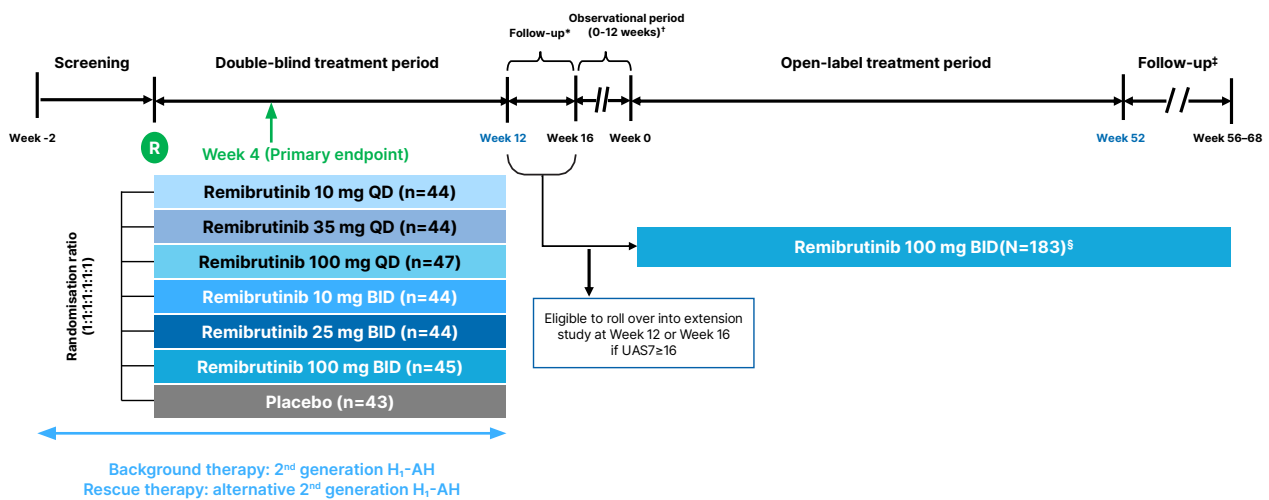
Bruton's tyrosine kinase (BTK) is essential for signalling through the high-affinity IgE receptor in mast cells and basophils.<sup>11</sup> Therefore, BTK is an attractive therapeutic target for CSU.<sup>11</sup> BTK inhibitors have potential efficacy in both Type I and Type IIb CSU due to BTK-mediated degranulation in mast cells and inhibition of autoantibody production in B cells.<sup>12</sup>

## A Phase IIb Dose-Finding Evaluation of Remibrutinib (LOU064)

Remibrutinib (LOU064) is a novel, highly selective, and potent covalent oral BTK inhibitor, recently evaluated in a Phase IIb, first-in-patient, dose-finding, multicentre, randomised, double-blind, placebo-controlled study.<sup>13,14</sup> This trial was conducted at 82 sites in 17 countries for adult patients with moderate-to-severe CSU for  $\geq 6$  months, and itch and hives for  $\geq 6$  consecutive weeks, despite treatment with H<sub>1</sub>-antihistamines.<sup>13</sup> Eligible patients were required to have a Urticaria Activity Score (UAS7) of  $\geq 16$  points, and a Hives Severity Score (HSS7) of  $\geq 8$  points at baseline.<sup>13</sup> The primary endpoint was the change from baseline in UAS7 at Week 4, with secondary endpoints evaluating change from baseline in UAS7 at Week 12 and over time, complete absence of hives and itch, well-controlled disease response, and safety and tolerability.<sup>13</sup>

A total of 311 patients were randomised to receive remibrutinib 10 mg once daily (QD), 35 mg QD, 100 mg QD, 10 mg twice daily (BID), 25 mg BID, 100 mg BID, or placebo (Figure 1).<sup>13</sup> Approximately 90% of patients completed a 12-week treatment course in the core study, and eligible patients

**Figure 1: A dose-finding, multicentre, randomised, double-blind, placebo-controlled Phase IIb and open-label extension study in patients with chronic spontaneous urticaria.<sup>13-20</sup>**



\*Eligible patients (UAS7 ≥ 16) rolled over into the extension study at Week 12 or at Week 16.

†If UAS7 < 16 at Week 16, patients were allocated to the observational period of the extension study for up to 12 weeks. After a relapse in the extension study (UAS7 ≥ 16 at least once), the observational period was terminated, and the patient could enter the treatment period.

‡Minimum duration of the follow-up period was 4 weeks for all patients who stopped treatment with remibrutinib. Patients who achieved UAS7 ≤ 6 at Week 52 of the treatment period extended their follow-up period until relapse (UAS7 ≥ 16). Follow-up ended at Week 68 for all patients.

§Data for 183 patients were available during interim analysis (July 2021).

Background therapy was a second-generation H<sub>1</sub>-AH at a locally approved licensed posology that had to be administered daily with a stable treatment regimen throughout the study. Rescue therapy was a second-generation H<sub>1</sub>-AH at a locally approved licensed posology that differed from the background H<sub>1</sub>-AH, was eliminated primarily via renal excretion, and could only be given to treat unbearable symptoms (itch) of CSU on a day-to-day basis.

BID: twice a day; CSU: chronic spontaneous urticaria; H<sub>1</sub>-AH: H<sub>1</sub>-antihistamines; QD: once daily; UAS7: weekly Urticaria Activity Score.

from this study (weekly UAS7 ≥ 16) had the option to roll-over into an open-label extension study at Week 12 or Week 16, where patients were treated with 100 mg remibrutinib BID for 52 weeks.<sup>13,15</sup> All patients received second-generation H<sub>1</sub>-antihistamines at a locally approved licensed dose as background therapy throughout the study.<sup>13</sup>

Baseline demographic and disease characteristics were similar across groups.<sup>13</sup> The mean (± standard deviation) age was 45.0 years (± 14.9 years), and 71.4% of patients were female.<sup>13</sup> The mean UAS7 score at baseline was 29.6 (± 7.1).<sup>13</sup> UAS7 scores significantly improved at Week 4 in all remibrutinib doses (p < 0.0001

versus placebo), the primary endpoint.<sup>13</sup> A rapid and significant improvement in UAS7 was observed as early as Week 1, which was maintained up to Week 12 in all doses compared with placebo.<sup>13</sup> More patients who received remibrutinib (all doses) achieved a complete absence of hives and itch (UAS7 = 0) and a well-controlled disease response (UAS7 ≤ 6) over the 12-week treatment period.<sup>13</sup> From Week 2, these responses were maintained (UAS7 ≤ 6) or gradually increased (UAS7 = 0) up to Week 12.<sup>13</sup> Remibrutinib demonstrated a favourable safety profile across the dose range, with no dose-dependent pattern of adverse events (AE).<sup>13</sup> The most frequent AEs were headache and nasopharyngitis (9.7% and 8.6%

all-dose remibrutinib versus 14.3% and 7.1% placebo, respectively).<sup>13</sup>

In the Phase IIb trial, all remibrutinib doses provided clinically meaningful improvements versus placebo regarding the proportion of patients achieving UAS7=0 and UAS7≤6 over the entire treatment period up to Week 12, with a fast onset of action starting as early as Week 1.<sup>13</sup> Safety and tolerability were favourable across the whole dose range, with no dose-dependent pattern of events.<sup>13</sup> Remibrutinib was shown to be a promising new oral treatment option for patients with moderate-to-severe CSU.<sup>13</sup>

The following poster presentations at EADV 2022 further outlined the benefits of remibrutinib from the Phase IIb dose-finding study, specifically the time to complete urticaria control, a reduced need for rescue medication, a favourable safety profile, and improved QoL for patients.<sup>16-20</sup>

### Faster Time to Complete Urticaria Control Compared to Placebo

Marcus Maurer

The current analysis examined the time to first weekly UAS7 responses in patients with moderate-to-severe CSU from the Phase IIb study.<sup>16</sup> The median times to UAS7=0 (complete absence of hives and itch), first UAS7≤6 (well-controlled disease), and the response rate for achieving UAS7=0 and UAS7≤6 over time up to Week 12 were included.<sup>16</sup>

The median time to first UAS7=0 was shortest with remibrutinib 25 mg BID (4 weeks), compared with 100 mg BID (11 weeks) and 35 mg QD (12 weeks), and was not estimable for placebo.<sup>16</sup> Similarly, the median time to first UAS7≤6 was shortest with remibrutinib 25 mg BID (2 weeks) compared with all other doses and was not estimable for placebo.<sup>16</sup>

As early as Week 2, up to 32.6% of patients (in the 25 mg BID arm) reached complete control (UAS7=0) compared with 0% in the placebo arm.<sup>16</sup> By Week 12, 41.9% of patients (in the 25 mg BID arm) and 26.7–31.8% of patients on other doses of remibrutinib had reached UAS7=0,

compared with 14.3% in the placebo arm.<sup>16</sup> By Week 1, 27.9% patients (in the 25 mg BID arm) had achieved well-controlled disease (UAS7≤6), compared with 0% in the placebo arm.<sup>16</sup> By Week 12, 55.8% (in the 25 mg BID arm) and 38.3–52.3% of patients on other doses of remibrutinib had reached UAS7≤6, compared with 28.6% of patients on placebo.<sup>16</sup>

The results demonstrated that complete response (UAS7=0) and well-controlled disease (UAS7≤6) were achieved more rapidly and by more patients with remibrutinib compared with placebo.<sup>16</sup>

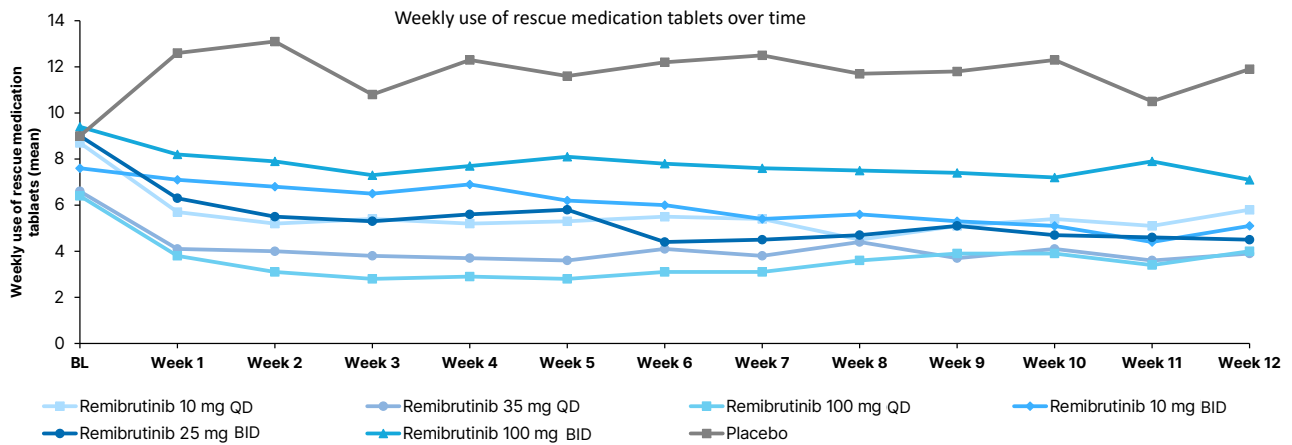
### A Reduced Need for Rescue Medication

Marcus Maurer

This analysis reported the use of second-generation H<sub>1</sub>-antihistamines as rescue medication in patients with moderate-to-severe CSU.<sup>17</sup> The number of rescue H<sub>1</sub>-antihistamine tablets used over the preceding 24 hours to control itch or hives was evaluated from baseline to Week 12.<sup>17</sup> Rescue medication allowed was second-generation H<sub>1</sub>-antihistamines eliminated mainly by renal excretion.<sup>17</sup> The rescue medication had to be different from the standard H<sub>1</sub>-antihistamines and was given as needed to treat severe symptoms during the screening, treatment, and follow-up periods.<sup>17</sup> The weekly use of rescue medication was calculated as the sum of the doses per day, over 7 days.<sup>17</sup>

Remibrutinib reduced the need for rescue medication as early as Week 1 compared with baseline and placebo across all doses over 12 weeks in patients with CSU (Figure 2), which was accompanied by an improvement in CSU symptoms, despite reduced use of H<sub>1</sub>-antihistamines.<sup>17</sup> The mean weekly use of rescue medication tablets was numerically lower across all remibrutinib arms compared to baseline and placebo.<sup>17</sup> At Week 4, the use of rescue medication with remibrutinib ranged from 2.9–7.7, compared with 12.3 for placebo; and at Week 12 the use of rescue medication with remibrutinib ranged from 3.9–7.1, compared with 11.9 for placebo.<sup>17</sup>

**Figure 2: Reduction in weekly use of rescue medication was observed early in all remibrutinib arms and remained low throughout the study.**



Full analysis set.

BID: twice a day; BL: baseline; QD: once daily.

Results demonstrated a rapid reduction in the need for rescue medication following treatment with remibrutinib across all doses, which was maintained over time in patients with CSU.<sup>17</sup>

treated groups than placebo. At Week 4, a decrease of 6.2–9.6 was observed with remibrutinib compared with –3.3 with placebo, and at Week 12 a decrease of 6.3–9.0 was observed with remibrutinib, compared with –4.4 with placebo (Figure 3).<sup>18</sup>

### Improved Quality of Life with Remibrutinib (LOU064)

Marcus Maurer

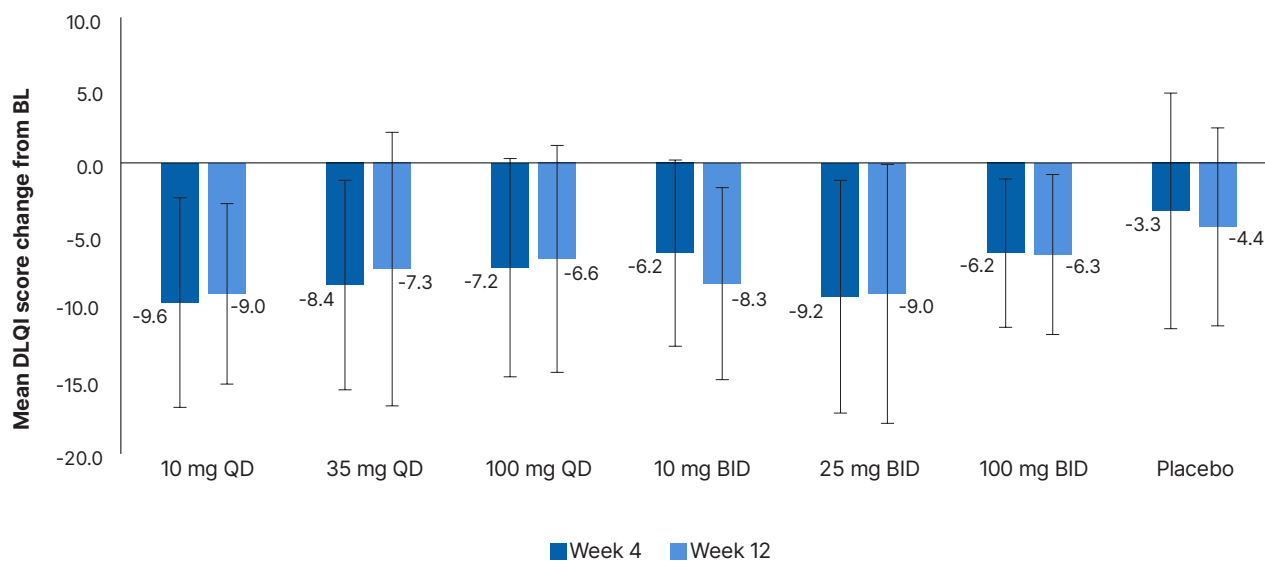
It is known that CSU can, and often does, have a substantial negative effect on patients' QoL.<sup>4</sup> The current analysis explored the changes in QoL over time in patients with CSU treated with remibrutinib compared with placebo using the Dermatology Life Quality Index (DLQI). Changes in DLQI score from baseline to Week 4 and Week 12, as well as proportions of patients achieving DLQI=0–1, were analysed at Week 4 and Week 12.<sup>18</sup>

The mean (±standard deviation) baseline DLQI score across all 311 randomised patients was 12.8 (±6.9), and ranged from 14.9 (±7.1)–10.8 (±6.7) across the group of patients that received remibrutinib, compared with 13.4 (±7.9) in the placebo group. Improvements in DLQI scores from baseline to Week 4 and Week 12 were numerically greater in all remibrutinib-

Further, a greater proportion of patients achieved DLQI=0–1 with remibrutinib than with placebo.<sup>18</sup> At Week 4, a total of 29.5–51.2% of patients achieved DLQI=0–1 with remibrutinib compared with 16.7% of patients with placebo, and at Week 12 a total of 34.1–53.5% of patients achieved DLQI=0–1 with remibrutinib compared with 28.6% of patients with placebo.<sup>18</sup> The group that contained the highest proportion of patients to achieve DLQI=0–1 was the group of patients who received remibrutinib at a dose of 25 mg BID (51.2% and 53.5% at Weeks 4 and 12, respectively).<sup>18</sup>

All remibrutinib doses, and particularly 25 mg BID, provided marked improvements in QoL of patients with CSU as early as Week 4 up to Week 12 compared to placebo.<sup>18</sup> These findings were consistent with previously reported results of remibrutinib treatment on weekly UAS7.<sup>13</sup>

Figure 3: Changes in Dermatology Life Quality Index scores from baseline to Week 4 and Week 12.



A decrease in DLQI score indicates an improvement in QoL.

BID: twice a day; BL: baseline; DLQI: Dermatology Life Quality Index; QD: once daily; QoL: quality of life.

## A Favourable Safety Profile Across All Doses of Remibrutinib

Ana Giménez-Arnau, Martin Metz

These two analyses reported the safety and tolerability of remibrutinib for up to 52 weeks in patients with CSU from the final analysis of the dose-finding Phase IIb trial and an interim analysis of its open-label extension period.<sup>19,20</sup> A total of 183 patients were recruited from the core study into the extension study, and at the time of interim analysis, 65 out of 183 patients (36%) had completed the full 52-week treatment in the extension period.<sup>19,20</sup> Patient demographics (age, gender, and weight) were similar across studies.<sup>19,20</sup> Safety assessments comprised AEs, serious AEs, AEs of special interest, infections and infestations, vital signs, ECG, and laboratory parameters.<sup>19,20</sup>

Analyses showed that safety and tolerability of 52-week treatment with remibrutinib 100 mg BID were comparable to any remibrutinib dose in the core study.<sup>19,20</sup> No new safety signals were observed with longer-term exposure to remibrutinib in patients with CSU.<sup>19</sup>

Haemorrhages were infrequent, minor, and non-serious cutaneous and mucosal events, primarily petechiae and purpura.<sup>19</sup>

The analysis of laboratory parameters, vital signs, and ECG findings did not reveal any significant safety concerns.<sup>19</sup> Notably, liver function tests identified only isolated cases of increased alanine aminotransferase (ALT).<sup>19</sup> One patient in the extension study had more than three-times the upper limit of normal for ALT, which normalised within 4 weeks (this patient withdrew from the study for personal reasons).<sup>19</sup> One patient in the core study underwent a transient increase in ALT of more than five-times the upper limit of normal, which resolved during treatment.<sup>19</sup>

The rate of infections and infestations was comparable between remibrutinib (all doses) and placebo and did not increase with longer-term exposure to remibrutinib.<sup>19,20</sup> Most infections were of unspecified pathogen, of which upper respiratory tract infection was the most common.<sup>20</sup> Rates of viral infections were low, with primarily coronavirus ones reported, reflecting the impact of the COVID-19

pandemic.<sup>20</sup> Bacterial and fungal infections were rare.<sup>20</sup>

The final analysis of the dosing in the Phase IIb trial and an interim analysis of the extension study showed a favourable safety profile and good tolerability of remibrutinib in patients with CSU, including long-term treatment with an oral dose of 100 mg BID remibrutinib for up to 52 weeks.<sup>19,20</sup>

## Conclusions

The Phase IIb dose-finding study of remibrutinib (LOU064), a novel, highly selective, and potent covalent oral BTK inhibitor, demonstrated significant improvements in disease activity as measured by the UAS7 in patients with CSU at Week 4 and Week 12 when compared with placebo. Clinical efficacy was maintained throughout the treatment, with a rapid clinical response, and a favourable safety profile across the entire dose range, with no dose-dependent events. Further analyses of the Phase IIb dose-

finding study of remibrutinib demonstrated complete response and well-controlled disease. Also, there was a reduced need for rescue medication and reduced CSU symptoms despite the reduced use of H<sub>1</sub>-antihistamines. Significant improvements in the QoL of patients with CSU were present as early as Week 4 and up to Week 12. A favourable safety profile and good tolerability of remibrutinib were found, including with long-term treatment of up to 52 weeks. These results support that remibrutinib is a promising new oral treatment option for patients with CSU.

Remibrutinib (LOU064) is currently in Phase III development to evaluate the efficacy and safety of remibrutinib for the treatment of CSU in adults inadequately controlled by second-generation H<sub>1</sub>-antihistamines. REMIX-1<sup>21</sup> and REMIX-2<sup>22</sup> are 52-week, global, multicentre, randomised, double-blind, parallel-group, placebo-controlled studies. BISCUIT<sup>23</sup> is a multicentre, open-label, single-arm study to investigate the safety, tolerability, and efficacy of remibrutinib in a Japanese population. The results of these clinical trials are awaited.

## References

- Zuberbier T et al. EAACI/GA<sup>2</sup>LEN/EDF guideline: management of urticaria. *Allergy*. 2006;61(3):321-31.
- Maurer M et al. Urticaria: Collegium Internationale Allergologicum (CIA) update 2020. *Int Arch Allergy Immunol*. 2020;181(5):321-33.
- Zuberbier T et al. The international EAACI/GA<sup>2</sup>LEN/EuroGuiDerm/APAAACI guideline for the definition, classification, diagnosis, and management of urticaria. *Allergy*. 2022;77(3):734-66.
- Maurer M et al. The burden of chronic spontaneous urticaria is substantial: real-world evidence from ASSURE-CSU. *Allergy*. 2017;72(12):2005-16.
- Maurer M et al. Antihistamine-resistant chronic spontaneous urticaria: 1-year data from the AWARE study. *Clin Exp Allergy*. 2019;49(5):655-62.
- Maurer M et al. Antihistamine-resistant chronic spontaneous urticaria remains undertreated: 2-year data from the AWARE study. *Clin Exp Allergy*. 2020;50(10):1166-75.
- Guillén-Aguinaga S et al. Updosing non-sedating antihistamines in patients with chronic spontaneous urticaria: a systematic review and meta-analysis. *Br J Dermatol*. 2016;175(6):1153-65.
- Maurer M et al. Omalizumab for the treatment of chronic idiopathic or spontaneous urticaria. *N Engl J Med*. 2013;368:924-35.
- Stull D et al. Analysis of disease activity categories in chronic spontaneous/idiopathic urticaria. *Br J Dermatol*. 2017;177(4):1093-101.
- Kaul M et al. Remibrutinib (LOU064): a selective potent oral BTK inhibitor with promising clinical safety and pharmacodynamics in a randomized phase I trial. *Clin Transl Sci*. 2021;14(5):1756-68.
- Smiljkovic D et al. BTK inhibition is a potent approach to block IgE-mediated histamine release in human basophils. *Allergy*. 2017;72(11):1666-76.
- Mendes-Bastos P et al. Bruton's tyrosine kinase inhibition— an emerging therapeutic strategy in immune-mediated dermatological conditions. *Allergy*. 2022;77(8):2355-66.
- Maurer M et al. Remibrutinib, a novel BTK inhibitor, demonstrates promising efficacy and safety in chronic spontaneous urticaria. *J Allergy Clin Immunol*. 2022.
- Novartis Pharmaceuticals. A multicenter, randomized, double-blind, placebo-controlled phase 2b dose-finding study to investigate the efficacy, safety and tolerability of LOU064 in adult chronic spontaneous urticaria (CSU) patients inadequately controlled by H1-antihistamines. NCT03926611. <https://clinicaltrials.gov/ct2/show/study/NCT03926611>.
- Novartis Pharmaceuticals. An open-label, single arm, multicenter, long-term safety and tolerability extension study for CSU patients who completed CLOU064A2201 or other preceding studies with LOU064. NCT04109313. <https://clinicaltrials.gov/ct2/show/NCT04109313>.
- Maurer M et al. Remibrutinib demonstrates faster time to complete urticaria control in patients with chronic spontaneous urticaria compared with placebo.

- Poster P1726. EADV Congress, 7-10 September, 2022.
17. Maurer M et al. Remibrutinib (LOU064) reduces the use of rescue medication in patients with chronic spontaneous urticaria: findings from a phase 2b study. Poster P1721. EADV Congress, 7-10 September, 2022.
  18. Maurer M et al. Remibrutinib (LOU064) treatment improves quality of life in patients with chronic spontaneous urticaria. Poster P1729. EADV Congress, 7-10 September, 2022.
  19. Giménez-Arnau A et al. Long-term safety and tolerability of remibrutinib (LOU064) in phase 2b study in chronic spontaneous urticaria patients. Poster P1722. EADV Congress, 7-10 September, 2022.
  20. Metz M et al. No increased rate of infections and infestations with remibrutinib (LOU064) in phase 2 studies in patients with chronic spontaneous urticaria. Poster P1737. EADV Congress, 7-10 September, 2022.
  21. Novartis Pharmaceuticals. A phase 3 study of efficacy and safety of remibrutinib in the treatment of CSU in adults inadequately controlled by H1 antihistamines (REMIX-1). NCT05030311. <https://www.clinicaltrials.gov/ct2/show/NCT05030311>.
  22. Novartis Pharmaceuticals. A phase 3 study of efficacy and safety of remibrutinib in the treatment of CSU in adults inadequately controlled by H1- antihistamines (REMIX-2). NCT05032157. <https://www.clinicaltrials.gov/ct2/show/NCT05032157>.
  23. Novartis Pharmaceuticals. A safety and efficacy study of remibrutinib in the treatment of CSU in Japanese adults inadequately controlled by H1-antihistamines (BISCUIT). NCT05048342. <https://www.clinicaltrials.gov/ct2/show/NCT05048342>.


FOR REPRINT QUERIES PLEASE CONTACT: [INFO@EMJREVIEWS.COM](mailto:INFO@EMJREVIEWS.COM)

# Secukinumab in Moderate-to-Severe Hidradenitis Suppurativa: Primary Endpoint Analysis from the SUNSHINE and SUNRISE Phase III Trials

This late-breaking oral presentation took place on 10<sup>th</sup> September 2022 as part of the 31<sup>st</sup> European Academy of Dermatology and Venereology (EADV) Congress, held in Milan, Italy, 7<sup>th</sup>–10<sup>th</sup> September 2022

**Presenter:** Alexa Kimball<sup>1</sup>

**Presenters:** Afsaneh Alavi,<sup>2</sup> Gregor Jemec,<sup>3,4</sup> Alice Gottlieb,<sup>5</sup> Xiaoling Wei,<sup>6</sup> Magdalena Wozniak,<sup>7</sup> Lorenz Uhlmann,<sup>8</sup> Angela Llobet Martinez,<sup>8</sup> Deborah Keefe,<sup>9</sup> Ruvie Martin,<sup>9</sup> Li Chen,<sup>8</sup> Elisa Muscianisi<sup>9</sup>



1. Harvard Medical School and Clinical Laboratory for Epidemiology and Applied Research in Skin (CLEARS), Department of Dermatology, Beth Israel Deaconess Medical Center, Boston, Massachusetts, USA
2. Department of Dermatology, Mayo Clinic, Rochester, Minnesota, USA
3. Department of Dermatology, Zealand University Hospital, Roskilde, Denmark
4. Health Sciences Faculty, University of Copenhagen, Denmark
5. Department of Dermatology, Icahn School of Medicine at Mount Sinai, New York, USA
6. Novartis Pharma Shanghai, China
7. Novartis Ireland Limited, Dublin, Ireland
8. Novartis Pharma AG, Basel, Switzerland
9. Novartis Pharmaceuticals Corporation, East Hanover, New Jersey, USA

**Disclosure:** Kimball is a consultant and investigator for Abbvie, Bristol Meyers Squibb, Janssen, Eli Lilly, Novartis, Pfizer, and UCB; an investigator for Incyte and AnaptysBio; a consultant for Bayer, Boehringer Ingelheim, Ventyx, Moonlake, Eli Lilly, Concert, Evolmmune, Sonoma Bio, and Sanofi; receives fellowship funding from Janssen; and serves on the Board of Directors for Almirall. Alavi has received honoraria as a consultant or advisory board participant from AbbVie, Janssen, Novartis, Boehringer Ingelheim, InflaRx, and UCB; and is an investigator for Processa and Boehringer Ingelheim. Jemec has served as a consultant for AbbVie, Coloplast, Leo Pharma, Novartis, UCB, and InflaRX; as an investigator for AbbVie, Leo Pharma, Novartis, Regeneron, UCB, and InflaRX; has received unrestricted grants from AbbVie, LeoPharma, and Novartis; has served on advisory boards for AbbVie, Janssen Pharmaceuticals, MSD, and Novartis; and as a speaker for AbbVie, Coloplast, Leo Pharma, and Galderma. Gottlieb has received honoraria as an advisory board member, non-promotional speaker, or consultant for Amgen, Anaptys Bio, Avotres Therapeutics, Boehringer Ingelheim, Bristol Myers Squibb, Dermavant, Eli Lilly, Janssen, Novartis, Pfizer, Sanofi, Sun Pharmaceutical Industries, UCB, and Xbiotech;



<b>Disclosure (continued):</b>	and research/educational grants from AnaptysBio, Janssen, Novartis, Ortho Dermatologics, Sun Pharmaceutical Industries, Bristol Myers Squibb, and UCB. Wei is an employee at Novartis Pharma Shanghai, China. Wozniac is an employee and stockholder at Novartis Ireland Limited, Dublin. Uhlmann and Martinez are employees and stockholders at Novartis Pharma AG, Basel, Switzerland. Keefe, Martin, Chen, and Muscianisi are employees and stockholders at Novartis Pharmaceuticals Corporation, East Hanover, New Jersey, USA.
<b>Acknowledgements:</b>	Writing assistance was provided by Helen Boreham, Wetherby, UK.
<b>Support:</b>	The publication of this article was funded by Novartis Pharma AG, Basel, Switzerland.
<b>Citation:</b>	EMJ Dermatol. 2022;10[1]:40-43. DOI/10.33590/emjdermatol/10182311. <a href="https://doi.org/10.33590/emjdermatol/10182311">https://doi.org/10.33590/emjdermatol/10182311</a> .



### Meeting Summary

The primary endpoint analyses from the SUNSHINE and SUNRISE Phase III trials of secukinumab in moderate-to-severe hidradenitis suppurativa (HS) were featured in an oral presentation as part of the late-breaking news session at the 31<sup>st</sup> annual European Academy of Dermatology and Venereology (EADV) congress. Known collectively as the SUNNY trials, the SUNSHINE and SUNRISE studies represent the largest Phase III trials conducted in HS to date. The primary endpoint was met in both studies for the every 2 weeks (Q2W) regimen, and in one for the every 4 weeks (Q4W) regimen, demonstrating the superiority of secukinumab over placebo in patients with moderate-to-severe HS. Secukinumab delivered rapid symptom relief and showed a favourable safety profile consistent with its use in other indications. Available data on file from the Week 52 database lock support the sustained efficacy beyond Week 16 with no new safety findings. Based on the positive outcomes of these milestone clinical trials, secukinumab is expected to be a new, safe, and effective biologic treatment option with a novel mode of action, targeting IL-17A, for moderate-to-severe HS.

### Primary Endpoint Analysis from the SUNSHINE and SUNRISE Phase III Trials

Alexa Kimball, Harvard Medical School and Clinical Laboratory for Epidemiology and Applied Research in Skin (CLEARS), Department of Dermatology, Beth Israel Deaconess Medical Center, Boston, Massachusetts, USA, presented the Week 16 results from the two identical Phase III SUNSHINE and SUNRISE trials.<sup>1</sup> Both studies were randomised, double-blind, multicentre clinical trials that assessed the short- (16 weeks) and long-term (up to 1 year) efficacy, safety, and tolerability of secukinumab, a monoclonal antibody selectively neutralising IL-17A in adult patients with moderate-to-severe HS.

Patients were randomised 1:1:1 to one of two subcutaneous secukinumab dosing regimens: 300 mg Q2W or 300 mg Q4W, or placebo. Key inclusion criteria included  $\geq 5$  inflammatory lesions affecting at least two distinct anatomical areas at baseline, and diagnosis of HS  $\geq 1$  year prior to enrolment. Patients in the antibiotic stratum were permitted to enter the study on stable treatment with selected antibiotics (i.e., doxycycline, minocycline, and tetracycline, representing only 10–14% of patients). Patients with HS with a total fistulae count  $\geq 20$  at baseline, active inflammatory disease, or previous exposure to secukinumab or other IL-17(A)-biologics were excluded. Together, the SUNSHINE and SUNRISE trials randomised a

total of 1,084 patients with HS across 219 sites worldwide between January 2019 and July 2022. Retention was very high, with a completion rate of approximately 94% across the two studies. Overall, patients were well-balanced between treatment arms, although Kimball highlighted the higher proportion of Hurley Stage III patients in the SUNRISE trial, particularly in the secukinumab Q2W arm (45.6%), indicating a more severe patient population.

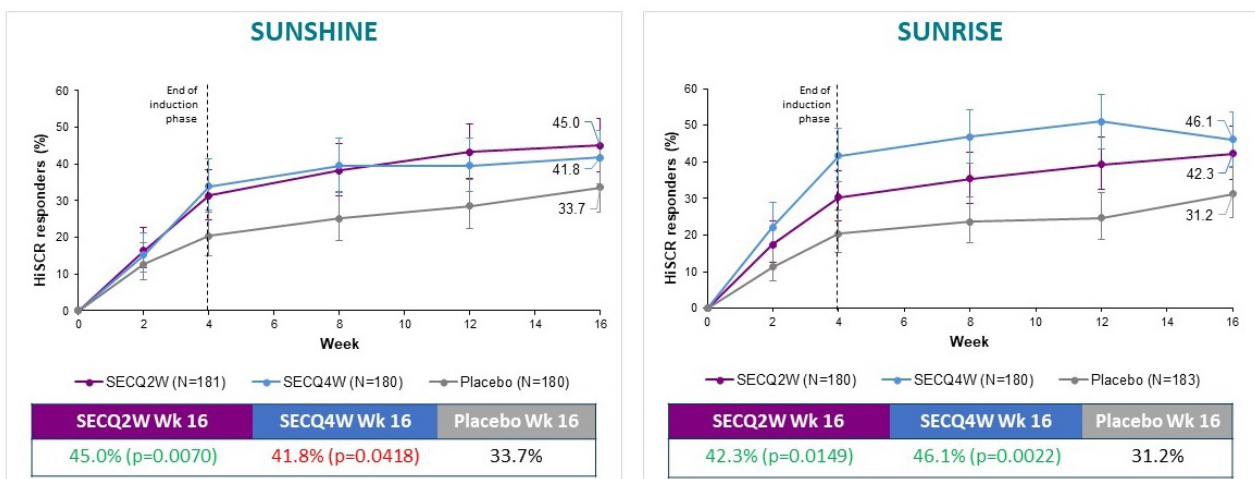
Both the SUNSHINE and SUNRISE studies met their primary endpoint based on HS clinical response (HiSCR), defined as at least a 50% decrease in abscess and inflammatory nodule (AN) count with no increase in the number of abscesses, or in the number of draining fistulae relative to baseline (Figure 1). Across both studies, numerically greater HiSCR response rates for secukinumab compared to placebo were seen at all time points from Week 2 to Week 16, with secukinumab demonstrating a rapid onset of action by Week 2. In the SUNSHINE and SUNRISE trials, treatment with secukinumab 300 mg Q2W demonstrated superiority compared to placebo in regard to the proportion of HiSCR responders (primary endpoint) in patients with moderate-to-severe HS at Week 16. In the SUNRISE trial only, secukinumab 300 mg Q4W was superior versus

placebo at Week 16 for HiSCR. Despite not achieving superiority, numerical differences at Week 16 were also observed in the SUNSHINE trial following the Q4W dosing regimen. The clinical response (HiSCR) to secukinumab at Week 16 is in line with the sustained and continued improvement that was seen up to 52 weeks of treatment, based on available data on file from the Week 52 database lock.

Secukinumab also achieved statistical significance and clinical improvements in key secondary endpoints evaluated in the SUNSHINE and SUNRISE trials. In both studies, secukinumab significantly reduced the AN count in patients with moderate-to-severe HS. The decrease in AN count with secukinumab appeared as early as Week 2 of treatment, and further improved up to Week 16. Overall, patients in the secukinumab treatment groups attained reductions from baseline of 39–47% in their AN count by Week 16, compared to decreases of approximately 23% with placebo.

Secukinumab was also shown to reduce the number of flares experienced by patients with moderate-to-severe HS, an outcome that Kimball described as an important “mirror” of efficacy. Across both studies, the proportion of patients experiencing flares was lower with secukinumab

Figure 1: SUNSHINE and SUNRISE both met their primary endpoints.



HiSCR: hidradenitis suppurativa clinical response; Q2W: every 2 weeks; Q4W: every 4 weeks; SEC: secukinumab; Wk: Week.

versus placebo at all time points from Week 2 to Week 16. Again, secukinumab demonstrated a rapid onset of action, with improvement seen as early as Week 2.

Finally, secukinumab reduced pain in patients with moderate-to-severe HS, which Kimball highlighted as an important and debilitating feature of this disease. A significantly higher proportion of patients with HS achieved a skin pain response (using the high hurdle of the numeric rating scale [NRS30] score), analysed based on pooled data from SUNSHINE and SUNRISE, compared with placebo at Week 16 following secukinumab 300 mg Q2W treatment. Despite not achieving statistical significance, numerical superiority at Week 16 was also observed with the Q4W dosing regimen. Only patients with a baseline NRS  $\geq 3$  were included in this analysis of skin pain.

Alongside its clinical efficacy, secukinumab also demonstrated substantial improvements in the quality of life of patients with moderate-to-severe HS in exploratory analyses from the SUNSHINE and SUNRISE trials. In both studies, Dermatology Life Quality Index (DLQI) response, defined as a >5 point reduction, was evident as early as Week 2. The proportion of patients achieving DLQI response was greater in both secukinumab regimens at Week 16 compared to placebo.

Safety data from the SUNSHINE and SUNRISE trials showed secukinumab to be well tolerated, consistent with its established safety profile in other disease states. Rates of adverse events

(AE) and all non-fatal serious AEs were very similar in both secukinumab arms compared to placebo. Rates of infections, including Candida infections, were low and not substantially different to placebo. The number of patients discontinuing study treatment due to AEs was also low across the secukinumab treatment groups in both trials. Discontinuations due to AEs in the secukinumab Q2W and Q4W arms were 2.8% and 0.6%, respectively, in the SUNSHINE trial and 0.6% and 2.2%, respectively, in the SUNRISE trial, compared to discontinuation rates of 0.6% and 2.2%, respectively, for placebo. Kimball described these safety data as “reassuring”, with secukinumab demonstrating “a very clean profile overall.”

---

## Conclusion

Both the SUNSHINE and SUNRISE Phase III trials successfully met the primary endpoint, demonstrating superiority of secukinumab over placebo in HiSCR, with rapid symptom relief in patients with moderate-to-severe HS. Secukinumab reportedly also demonstrated sustained efficacy beyond the Week 16 primary efficacy analysis. Overall, secukinumab was well tolerated in patients with moderate-to-severe HS, consistent with its known safety profile. Collectively, these results highlight that secukinumab is expected to be a new, safe, and effective addition to the treatment armamentarium for moderate-to-severe HS, Kimball concluded.

---

## References

1. Kimball AB et al. Secukinumab in moderate to severe hidradenitis suppurativa: primary endpoint analysis from the SUNSHINE and SUNRISE phase 3 trials. LB-3549. 31st EADV Congress, 7-10 September, 2022.

FOR REPRINT QUERIES PLEASE CONTACT: [INFO@EMJREVIEWS.COM](mailto:INFO@EMJREVIEWS.COM)

# Dermatoscopic Rainbow Pattern in Extragenital Lichen Sclerosus et Atrophicus

**Authors:** Hasret Gunduz,<sup>1</sup> Bengu Nisa Akay,<sup>2</sup> Mehmet Fatih Atak,<sup>2</sup> Aylin Okcu Heper,<sup>1</sup> \*Banu Farabi<sup>3</sup>

1. Faculty of Medicine, Ankara University, Türkiye
2. Department of Dermatology, Ankara University, Türkiye
3. Department of Dermatology, New York Medical College, Valhalla, New York, USA

\*Correspondence to banufarabi91@gmail.com

**Disclosure:** The authors have declared no conflicts of interest.

**Keywords:** Case report, dermatoscopy, extragenital lichen sclerosus et atrophicus (LSEA).

**Citation:** EMJ Dermatol. 2022;10[1]:44-45. DOI/10.33590/emjdermatol/10099504. <https://doi.org/10.33590/emjdermatol/10099504>.

## BACKGROUND

Lichen sclerosus et atrophicus (LSEA) is an inflammatory skin disease that most frequently affects pre-pubertal and post-menopausal females. It commonly affects anogenital skin; however, extragenital lesions are not uncommon and occur in isolation or concomitantly with genital lesions. Autoimmunity, genetic factors, and hormonal influences are the main factors suspected in aetiology; however, the exact cause remains unknown. Histopathologic and dermatoscopic features of LSEA have been included in several studies; however, the dermatoscopic rainbow pattern has been rarely reported. Herein, the authors discuss a case of extragenital LSEA with a prominent rainbow pattern under polarised dermatoscopy.

## CASE STUDY

A female in their 50s presented with a 2-year history of multiple itchy lesions on the right inner thigh. Physical examination revealed porcelain white crinkled violaceous patches extending from the right inner thigh to the inguinal fold.

Dermatoscopic examination showed brown follicular plugs, white lines, and a rainbow pattern arranged over white polygonal clods on polarised mode (Dermlite DL4; DermLite, San Juan Capistrano, California, USA [Figure 1]). A punch biopsy of the lesion was performed, and histopathology was consistent with LSEA. In light of clinical symptoms as well as histopathologic and dermatoscopic findings, the patient was diagnosed with extragenital LSEA and started on topical steroid therapy. The lesions resolved completely and no relapse was noted in the following 2 years.

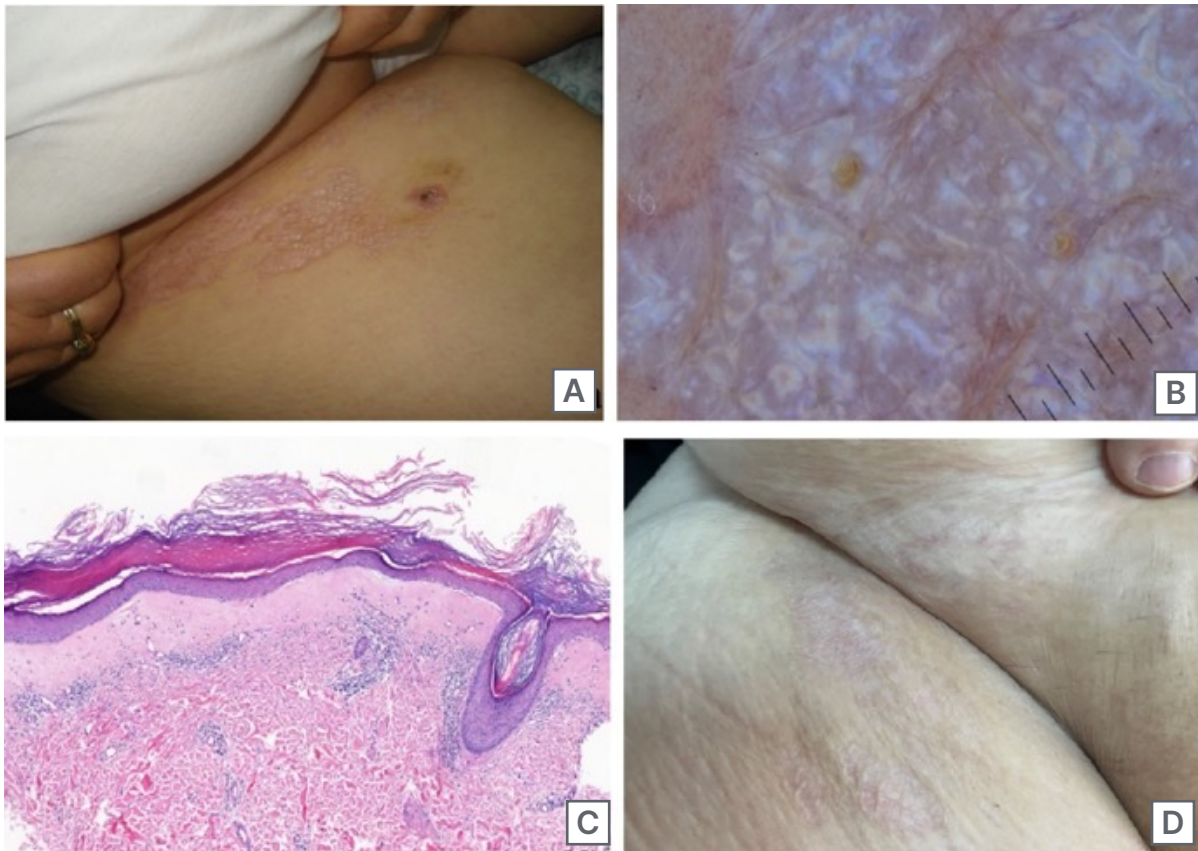
## DISCUSSION

Extragenital LSEA mostly occurs as multiple, oval, bluish-whitish macules or papules located on the neck, shoulders, and upper trunk. Lesions are predominantly asymptomatic. Itching is the most common complaint in symptomatic cases and leads to increased frequency of scratching followed by scarring. Diagnosis is mostly clinical; however, in ambiguous cases, dermatoscopy and histopathology lead to diagnosis. Dermatoscopic features of LSEA are characterised by white structureless areas, follicular plugs, purple dots, shiny white streaks, and peppering.<sup>1</sup> In the authors' patient, a prominent rainbow pattern arranged over white polygonal clods on polarised dermatoscopy was observed. The rainbow pattern has been reported in a few LSEA cases in the literature.<sup>2</sup> In previous studies, this pattern has been associated with a rich vascular network; however, the authors' histological examination did not reveal a vascular-rich pattern. The authors observed epidermal hyperkeratosis, atrophy, and homogeneous dense fibrosis in the papillary dermis and dense lymphocytic infiltrate below the fibrosis. Although the mechanism behind this appearance is not clear, it can be secondary to diffuse and dense homogenous fibrosis in the superficial dermis, giving a sharp and brighter appearance along with increased dermal capillaries and inflammatory cell infiltration.

## CONCLUSION

Extragenital LSEA should be considered in the differential diagnosis in the presence of

Figure 1: Dermatoscopic examination of the patient.



A) Clinical image of lichen sclerosus et atrophicus extending from the left inner thigh to the inguinal fold showing porcelain white crinkled violaceous patches. B) Dermatoscopic findings revealing brown follicular plugs, white lines, and a prominent rainbow pattern arranged over white polygonal cods on polarised mode (DermLite DL4; DermLite, San Juan Capistrano, California, USA). C) Histologic findings revealing epidermal hyperkeratosis, atrophy, follicular plugs with basal vacuolar degeneration, and homogenous dense fibrosis in the papillary dermis with dense lymphocytic infiltrate beneath the fibrosis (haematoxylin and eosin stain, 7.3x magnification). D) Clinical image of lichen sclerosus et atrophicus showing regression of the lesions except mild atrophy and depigmentation after 2 years of topical steroid use.

dermatoscopic rainbow pattern, shiny white lines, and follicular plaques along with clinical features. ●

### References

1. Wang YK et al. Dermoscopic features of morphea and extragenital lichen sclerosus in Chinese patients. *Chin Med J (Engl)*. 2020;133(17):2109-11.
2. Errichetti E et al. Dermatoscopy of morphea and cutaneous lichen sclerosus: clinicopathological correlation study and comparative analysis. *Dermatology*. 2017;233(6):462-70.

# Abstract Highlights

The following highlights spotlight abstracts presented at the European Academy of Dermatology and Venereology (EADV) Congress 2022, specifically focusing on the latest developments in nail disorders and urticaria.

**Citation:**

EMJ Dermatol. 2022;10[1]:46-52. DOI/10.33590/emjdermatol/10000762. <https://doi.org/10.33590/emjdermatol/10000762>.





## The Expanding Uses of Dermoscopy

NAIL dermoscopy should be considered when examining a patient with nail psoriasis, according to an abstract presented at the EADV's 31<sup>st</sup> congress.

Dermoscopy emerged into the field of dermatology as an aid to diagnosing cutaneous malignant tumours such as melanoma and basal cell carcinoma and pre-malignant conditions such as actinic keratosis. A noninvasive procedure, dermoscopy uses have expanded and the study authors believe that it could be used as a tool when examining nail changes that are associated with a number of dermatological conditions.

The authors evaluated the dermoscopic findings in 44 patients with psoriatic fingernails, then compared these results with the clinical findings, with the aim of determining the relationship with disease severity. Demographic data such as age, gender, disease duration, other illnesses, and medications were recorded along with psoriasis type.

The patients' fingernails were thoroughly cleaned with spirits beforehand to remove dirt or external applications, and disease severity was determined according to the Psoriasis Area Severity Index (PASI) score. The fingernails were examined with the naked eye and dermoscopically, with the Nail Psoriasis Severity Index (NAPSI) scores being calculated clinically and dermoscopically. Pitting was the most common finding, both clinically and dermoscopically (77.27% and 86.36%,

respectively). There was no significant difference in clinical and dermoscopic NAPSI ( $p=0.45$ ). There was a positive correlation between clinical ( $r=0.458$ ;  $p<0.001$ ) and dermoscopic ( $r=0.421$ ;  $p<0.002$ ) PASI and NAPSI scores. Splinter haemorrhages and oil spots were seen more frequently with dermoscopy ( $p=0.031$  and  $p<0.001$ , respectively). The latter were found more frequently after an onychoscopic examination of patients with severe cutaneous disease ( $PASI>10$ ), with two novel onychoscopic findings being described for the first time.

---

**"Nail dermoscopy should be considered when examining a patient with nail psoriasis, as well as in cases of isolated nail involvement when the clinical diagnosis of nail psoriasis is considered suspicious."**

---

The authors concluded that nail dermoscopy should be considered when examining a patient with nail psoriasis, as well as in cases of isolated nail involvement when the clinical diagnosis of nail psoriasis is considered suspicious. ●

## Non-invasively Diagnosing Nail Disorders

IN CERTAIN diseases, some onychoscopic patterns are consistently seen and can be used in diagnosing a patient, stated Snehal Shelke from the Krishna Institute of Medical Science in Pune, India.

Dermatologists can find it challenging to diagnose nail disorders without invasive procedures, and nail disorders comprise 10% of all dermatological conditions. Therefore, Shelke evaluated onychoscopic patterns associated with specific nail disorders.

The study comprised of 150 patients with a history and clinical presentation that was suggestive of nail disorders, such as inflammatory disorders of the nail unit, nail pigmentary disorders, and more. Patients were recruited after confirmation of their clinical diagnosis was given and the study excluded patients with secondary modified lesions.

Wet and dry onychoscopy was performed using polarised and non-polarised modes. The DermLite DL4 (DermLite, San Juan Capistrano, California, USA) was attached to a mobile camera to take and save the dermoscopic images. When the data had been compiled, they were analysed with SPSS Statistics (IBM, Armonk, New York, USA), version 21.0.

Most patients were aged 21–50 years and there were slightly more males than females. However, females were more likely to present with green nail

---

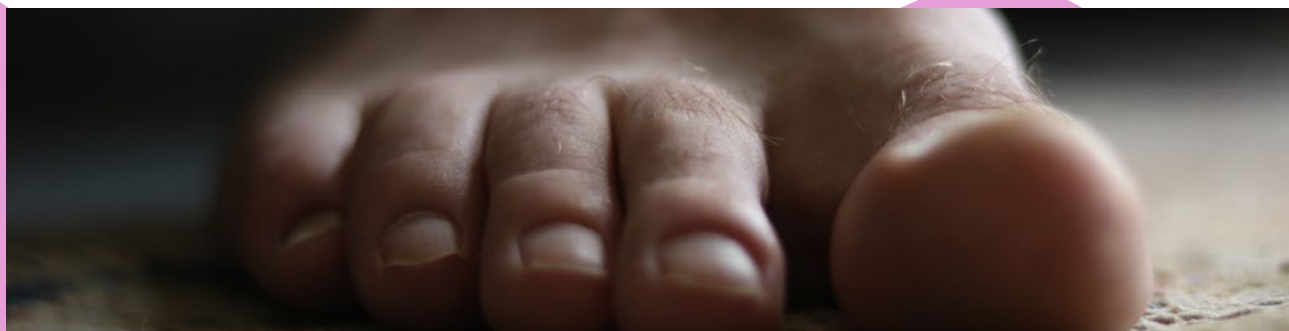
**"Onychoscopic patterns could be used to diagnose specific conditions while avoiding unnecessary biopsies, and thus improve patient outcomes."**

---

syndrome. The most common changes that were found onychoscopically were chromonychia, longitudinal striae, and nail plate alterations, while the latter and chromonychia were also the most common nail disorders.

Certain symptoms are associated with specific conditions. For example, jagged edges of the onycholytic plate, hyperkeratotic ruin patterns, and aurora borealis were specific to onychomycosis. If present with another disorder, it could indicate a secondary infection of dermatophytes. Inflammatory disorders associated with the nail unit, such as nail psoriasis, indicated nail plate alterations with increased fragility of the nail plate. Changes in curvature and proximal nail fold capillaries were the most common changes associated with connective tissue disorders.

Therefore, onychoscopic patterns could be used to diagnose specific conditions while avoiding unnecessary biopsies, and thus improve patient outcomes. ●





## Novel Topical Cosmetic Plus Systemic Therapy Improves Onychomycosis Outcomes

COMBINING a topical cosmetic with systemic therapy for distal subungual onychomycosis (DSO) treatment improved the rate of healing and treatment concordance according to an abstract presented at EADV's 31<sup>st</sup> congress, held in Milan, Italy, 7<sup>th</sup>-10<sup>th</sup> September 2022.

Onychomycosis accounts for approximately half of all nail disease and is the single most common infective nail disorder. Best treatment practices include topical and/or systemic antifungal medications as either monotherapy or combination therapy. The treatment course takes several months, a factor which contributes to reduced concordance.

A pilot study, led by Michela Starace, University of Bologna, Italy, evaluated the treatment efficacy of oral itraconazole 100 mg/day plus twice-daily application of a topical cosmetic treatment containing hyaluronic acid and *Pistacia lentiscus* combination therapy for 6 months, against oral itraconazole alone.

Twenty patients presenting with DSO of the same severity in two nails were enrolled to the study. All candidates received oral itraconazole, and the topical cosmetic was applied to just one of the infected nails. Patients were followed up for the 6-month treatment regimen. Photography, videodermoscopy, Global Assessment Scales (GAS), Onychoscopy Assessment Scales, and patient self-assessment scores at baseline, 3 months, and 6 months, were used to assess treatment efficacy. Of the 20 enrolled patients, 15 completed the study.

The authors found that 60% of patients displayed a marked clinical and onychoscopic improvement in nails

treated with combination therapy, as highlighted by a GAS of 0 (defined as clearance of infection). In contrast, only 20% of nails treated with itraconazole monotherapy had a GAS score of 0 and 60% showed signs of residual infection.

---

**"As a result of this faster healing and improved nail aesthetic, using such hyaluronic acid and *P. lentiscus*-containing topical cosmetic treatments could increase onychomycosis treatment concordance."**

---

The findings from this pilot study highlight how combination therapies can improve nail healing for patients with DSO. The authors concluded that the topical cosmetic therapy was a safe and effective treatment for DSO, and resulted in improved colour, decreased nail thickness, and reduced onycholysis. As a result of this faster healing and improved nail aesthetic, using such hyaluronic acid and *P. lentiscus*-containing topical cosmetic treatments could increase onychomycosis treatment concordance. ●



# Treating Patients with Chronic Urticaria Following COVID-19 Infection Using Sequifenadine

URTICARIA is one of the most common symptoms of severe acute respiratory syndrome coronavirus 2, according to recently conducted studies. Urticaria following COVID-19 infection can last for up to 10 months.

Also known as hives, urticaria is a rash presenting with red or pink itchy bumps. Sometimes appearing as raised weals, areas of urticaria range in size, and can be as large as a dinner plate. The rash can appear on a single part of the body, or can spread across several different areas. In some patients, chronic urticaria manifests, which involves symptoms over a 6-week period or longer.

Researchers at the Ivano-Frankivsk National Medical University (IFNMU), Ukraine, studied a cohort of 14 patients aged 18–60 years who had varying severities of COVID-19 during the autumn of 2020 (asymptomatic: two patients; treated at home: seven patients; hospitalised: five patients; O<sub>2</sub> support for 2 weeks following hospital discharge: one patient). No patient had chronic urticaria before contracting COVID-19. In each, urticaria presented as one of the symptoms of COVID-19, and lasted for more than 6 weeks.

Treatments for chronic urticaria range from rehabilitation, elimination, or significant reduction of concomitant pathology to pharmacotherapy, diet therapy, and environmental control. The study used the H1- and 5HT-serotonine receptor antagonist sequifenadine in combination therapy, with an oral

---

**"Sequifenadine had no significant sedative effect in the trial, and has a pronounced and prolonged antipruritic effect."**

---

dose of 50 mg twice daily for 15 days. Sequifenadine blocks histamine receptors, and reduces histamine in tissue by accelerating its destruction using diamine oxidase.

Researchers found that in 10 patients, improvement occurred on Day 2 of combination therapy, and in four patients on Day 3. On Day 2 to Day 3, itching intensity decreased significantly, the regression of urticaria was observed, and sleep was normalised. Sequifenadine had no significant sedative effect in the trial, and has a pronounced and prolonged antipruritic effect.

The study recommends that sequifenadine can be used as a combined treatment for patients with chronic urticaria following COVID-19 infection, as part of a complex therapy programme. ●

## COVID-19 Vaccination Safe for Patients with Chronic Spontaneous Urticaria

VACCINATION against COVID-19 is safe for patients with chronic spontaneous urticaria (CSU) using omalizumab/antihistamine therapy, as shown in an abstract presented at EADV Congress 2022. Following the limited data on the effects of vaccination against COVID-19 in these patients, this study examined adverse events following immunisation, cutaneous adverse reactions, and vaccination rates, as well as potential flares following vaccination in patients with CSU on this treatment.

Through a face-to-face survey, the researchers collected demographic data, vaccination status against COVID-19, history of COVID-19 disease, post-vaccination events, and disease activation from 40 patients with a history of CSU. They then assessed the severity of disease with the Urticaria Activity Score (UAS7).

Regarding vaccination rates, 84.21% (n=32) of the participants were vaccinated, having received 2–4 doses of either CoronaVac (Sinovac Biotech, Beijing, China; 46.7%), an inactivated whole-virus vaccine, or the mRNA BNT162b2 vaccine (Pfizer, New York City, New York USA, and BioNTech, Mainz, Germany; 53.2%). They noted cutaneous adverse reactions, including mild skin symptoms, in 18.75% (n=6),

13.33% (n=4), and 20% (n=3) after the first, second, and third dose, respectively. Extracutaneous systemic mild side effects, the most common one being injection site pain, were noted in 62.5% (n=20) of participants after the first dose, 53.3% (n=16) after the second, 46.6% (n=7) after the third, and 50% (n=1) after the fourth dose.

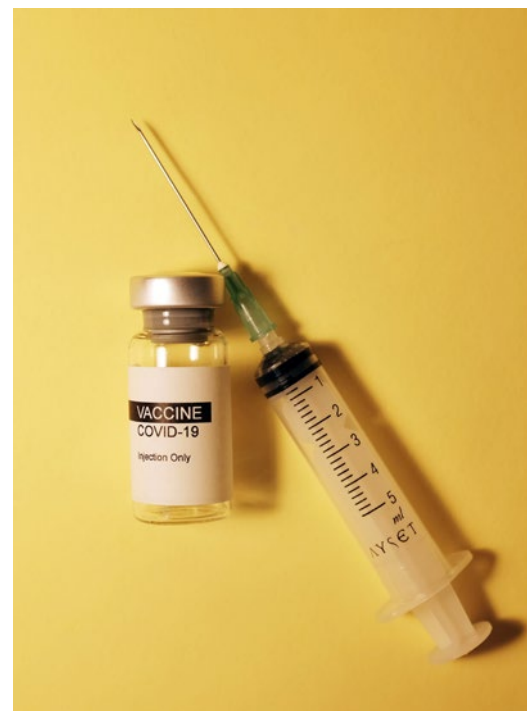They obtained the UAS7 from nine patients, which showed that urticaria was absent or well-controlled in all but one patient, who showed severe urticaria. No serious adverse events following immunisation or cutaneous adverse reactions were noted.

The researchers concluded that the vaccine is well-tolerated among patients with CSU receiving omalizumab/antihistamine therapy and that the treatment may even have a protective effect. Further studies should determine if the vaccine is safe for patients with CSU who are treated with monoclonal antibodies or biologicals. ●

---

**"The researchers concluded that the vaccine is well-tolerated among patients with CSU receiving omalizumab/antihistamine therapy and that the treatment may even have a protective effect."**

---



**"FAU is a rare hereditary chronic urticaria, which presents as pruritic weals following exposure to water, and affects children, adolescents, and young adults."**

## A Review of Familial Aquagenic Urticaria

RESEARCHERS from the Veltischev Research and Clinical Institute for Pediatrics, Pirogov Russian National Research Medical University, Moscow, Russia, have conducted a systematic review of the condition familial aquagenic urticaria (FAU). FAU is a rare hereditary chronic urticaria, which presents as pruritic weals following exposure to water, and affects children, adolescents, and young adults.

The study aimed to characterise both the clinical features and demographics of FAU, with particular focus placed upon family history, clinical phenotypes, and diagnostic approaches. A search using the keywords "aquagenic urticaria" was conducted using PubMed, and articles published between 1964 and 2022 were included. Using this criteria brought up 73 articles: eight of these were case reports or series about FAU, and were included in the study analysis. However, studies that were unrelated to FAU were excluded, as were review articles.

In the study cohort, researchers included those affected with genetic disorders, alongside first- (parents, siblings, twins, children) and second-degree relatives (grandchildren, siblings of parents, grandparents). Overall, the study identified a total of 16 FAU cases, 12 of whom were patients, and

four of whom were their relatives. Eight patients in this cohort were male, and the median age of disease onset was 15 years (range: infancy–22 years). Ten patients had disease onset before the age of 18 years.

Triggers for FAU included tap water (n=15), sweat (n=4), seawater (n=3), pool water (n=2), rain (n=1), chlorinated water (n=1), and saline (n=1). The median time to which weals presented following exposure to these triggers was 10 minutes (range: 5–20 minutes). Skin lesions were weals (n=14) or weals with papules (n=1), and were located on the trunk (n=11), neck (n=3), upper arms (n=3), shoulders (n=2), thighs (n=2), and rarely on the face and feet (n=1 in each case). Pruritis was reported in 11 cases. In all cases, urticarial lesions cleared up within 1 hour.

For testing purposes, tap water (n=12), distilled water (n=4), saline (n=1), and sweat (n=1) were used. Methods of exposure included water compresses (n=4), water-soaked gauze (n=3), showering (n=3), wet towels (n=2), and bandages (n=1). Patients with FAU were subsequently treated with sedating (n=6) or non-sedating antihistamines (n=7). Three patients were given phototherapy, and two patients from the cohort practiced trigger avoidance without pharmacotherapy. ●



# Congress Interview



## Christa De Cuyper

Chair of the European Academy of Dermatology and Venereology (EADV) Nurse Association Working Group (NAWG) and Task Force Facilitator (TFF); Former Head of Dermatology, Sint-Jan General Hospital, Bruges, Belgium

**Citation:** EMJ Dermatol. 2022;10[1]:53-57. DOI/10.33590/emjdermatol/10060529. <https://doi.org/10.33590/emjdermatol/10060529>.

EMJ spoke to Christa De Cuyper about her roles within the European Academy of Dermatology and Venereology (EADV), including the recent Nurses in Dermatology Practice event, which De Cuyper co-chaired.

### 01 What does your role as Chair of the European Academy of Dermatology and Venereology (EADV) Nurse Association Working Group (NAWG) entail, and what have been your greatest achievements to date in this position?

In 2016, I was invited by the Executive Committee of EADV to start and chair a NAWG. We had several challenges to tackle: to increase the presence of nurses in the EADV; to develop a solid network with nurses and nurse organisations; to improve the knowledge and insights into the roles and responsibilities of nurses in the management of patients with skin diseases, and to identify their needs, shortcomings, and gaps in training; and, last but not least, to promote education in dermato-venereology.

In collaboration with the Statutes Committee, a new EADV member category for nurses and medical assistants has been created; it was approved by the EADV board in 2020.

We started with 21 nurse members in 2021, increasing to 46 in September 2022. More than 80 nurses attended the Congress in Milan, Italy, and many registered for online participation. We have a growing network, excellent contacts with the British Dermatology Nurse Group (BDNG), and have already gathered a core group of motivated nurses from different European regions in the brand new Nurse Task Force, which was approved at the board meeting in Milan, and which will continue the work of the working group.

### 02 Could you tell us about your primary duties as facilitator of the EADV Task Forces?

The Task Force Facilitator (TFF) is the liaison between the different task forces (TFs) and EADV management. TFs are expert groups on a specific field or topic of dermatology. We currently have 37 TFs in EADV co-ordinated by the TF office and the TFF. The TFF supports with organisational and structural advice, facilitates communication with the Executive Committee and Board, and enhances collaboration between TFs. The TFF can attend TF meetings, virtually or in-person during the congress, and is expected to encourage initiatives and enhance the productivity of the TFs. Since I started in November

2019, I have included five new TFs, guiding them through the application process. The TF bylaws have been updated, implementing the suggestions we collected from a TF survey, which was done in 2020.

TFs have been invited to prepare information and recommendations for the 'Covid Corner' on the EADV website. New patient leaflets have been prepared and released, and several TFs have published in the EADV newsletter. My idea to rejuvenate TFs by stimulating mentorship and inviting junior members (dermatologists in training) to join the TFs received positive response. In general, my conclusion is that with my help TFs got a boost, and despite the COVID-19 pandemic, they increased their activities and productivity.

**03** In addition to the NAWG, you serve on the Patient Association Working Group and the Advocacy Working Group. How do you contribute to the operation of these committees?

In both working groups, I try to contribute with critical advice from my personal experience as a clinical dermatologist. I have been working for 35 years in a general hospital, which has given me the opportunity to be in daily contact with patients and with a wide range of other specialties, but also to get involved in clinical studies and gain a lot of practical knowledge regarding innovative therapies and techniques. My department had an excellent relationship with oncology, nephrology, haematology, and rheumatology; has consulted in the diabetic foot clinic; and was partner in the multidisciplinary approach of patients with complex



---

**"In both working groups, I try to contribute with critical advice from my personal experience as a clinical dermatologist."**

---

diseases. My job also included teaching and training young dermatologists. All this allows me to give feedback on different aspects of dermatology. I acted as liaison with my national Member of the European Parliament (MEP) to support the initiatives proposed by EADV for the European Beating Cancer Plan.

**04** One of the EADV's goals is to "build and support a strong nurse community via well-structured training." To date, what actions has the organisation undertaken to facilitate this? Going forward, how can the EADV continue to provide education for nurses and medical assistants in the dermato-venereology community?

Since 2012, there has been a nurse session during the congress. It became a 'Nurse Day' in 2019, and we will continue to have a full day with nurse-dedicated sessions at the future EADV congresses, with a balanced faculty of nurses and doctors.

In 2021, we organised a first fostering course for nurses in dermatology. This was an excellent opportunity to bring nurses from different countries together and exchange knowledge and vision. Many of them joined us for a first roundtable for nurses in dermatology during the recent congress in Milan, and shared their ideas for new educational activities and the further development of a common training framework for dermatology specialist nurses. This interactive meeting was a positive experience to be repeated in the future.

More courses for nurses have been planned on their request, on specific subjects. On 28<sup>th</sup>-30<sup>th</sup> November 2022, we will have a course on allergy in Porto, Portugal, and in November 2023 another nurse course, 'All about Cancer', will take place in Brussels, Belgium. We intend to prepare webinars and online teaching in co-operation with the EADV school.



---

**"In 2021, we organised a first fostering course for nurses in dermatology. This was an excellent opportunity to bring nurses from different countries together and exchange knowledge and vision."**

---

**05** You were the Co-Chair for EADV's Nurses in Dermatology Practice event, which took place between 25<sup>th</sup>–27<sup>th</sup> November 2021. In your opinion, what were the standout sessions and key take-home messages from this course?

The course received a very high global score from the participants. The presentations were very interactive, featuring different educational programmes for nurses, implementation of European guidelines in daily practice, and also addressing the diversity of competences and tasks of nurses, in particular illustrating the valuable psychological support and coaching role for patients with chronic skin diseases.

We feared the language barrier, but it was not an obstacle. Lots of participants contributed with presentations, highlighting some aspects of their clinical practice. This proved to be a perfect way to exchange experiences, resulting in animated discussions.

One participant commented: "Many of us spoke different languages. However, we all had something in common; eager to learn and to share our knowledge. We had the opportunity to introduce ourselves, to present case studies or approaches that we considered innovative. In a very short time, the language barrier was broken, and we started to envisage a European Nurse co-operation."

**06** At the 2021 Nurses in Dermatology Practice meeting, you delivered presentations on photodynamic therapy and skin surgery. What were the most important learnings from these talks?

Patient selection was the starting point. The message I tried to transfer was that informed decision making should be considered for all types of procedures. Guidelines and recommendations are excellent tools to ensure quality of care and to help us with a structured overview of treatment modalities for different indications. However, they should not be mandatory and should allow deviation, taking the specific situation and wishes of the patient into consideration.

Correct diagnosis is crucial. When in doubt, refrain from invasive actions. Do not be ashamed to ask for a second opinion. Good knowledge of procedures, devices, and materials is important and, most of all, know your own limits.

**07** Could you highlight the principal findings from your 2020 review, 'The role of the nurse in the care and management of patients with atopic dermatitis'?

Higher nursing education is associated with improved patient outcome and safety. The outcome of the treatment of atopic dermatitis is highly related to the patient compliance. Nurses can play a central role in therapeutic patient education and follow-up.



**08** You are a founding member of the European Society of Tattoo and Pigment Research (ESTP), which aims to “advance the manufacturing, distribution and sales of safer tattoo ink and to develop and support research projects, guidelines and publications.” How close are you to achieving this goal, and what further efforts are necessary?

There has been some progress, and the issue has been taken seriously on the European level in recent years. Unfortunately, the decisions taken by the European Chemical Agency (ECHA) do not assure complete safety. The new regulations do not cover all tattoo ink ingredients, and some ingredients with minor risks have been banned, which puts manufacturers in a difficult position. It remains a complex domain, and expert opinion is often not taken into consideration by the decision makers. ESTP is continuing its efforts, and will discuss the issue and current situation at the next congress on 24<sup>th</sup>–26<sup>th</sup> May 2023 in Vienna, Austria.

**09** What initiatives and projects are you involved with to promote hygiene standards for tattooists and the safety of tattoos? How active are the EADV in this field?



EADV launched its first tattoo campaign in 2015, and has continued its efforts with the production of two cartoon videos on the website. The aim was to inform the public about the risks of tattooing and tattoo removal. I was a member of the CEN 435 project. The final document, ‘Tattooing - safe and hygienic practice’, was released in 2020, and is a guideline for body art practitioners. It is an international standard on safety and hygienic practices on tattooing to ensure the safety and protection of users. At the EADV congress in Paris, France, an interactive meeting with tattooists took place, where we discussed several aspects of this document.

Since 2020, the new TF Body Art has prepared several patient leaflets regarding complications and aftercare. Several members of the TF are giving teaching sessions for tattooists in their respective countries. We are considering organising a meeting with tattooists at the next EADV congress in Berlin, Germany, in 2023, with the aim to enhance the communication, exchange knowledge, and share experiences. Dialogue is important, and the skin is our common topic.


FOR REPRINT QUERIES PLEASE CONTACT: [INFO@EMJREVIEWS.COM](mailto:INFO@EMJREVIEWS.COM)

# ROSACEA AWARENESS



## SYMPTOMS

Redness across the nose, cheeks, forehead, and chin





Hot and tender skin in affected area

Telangiectasia








Dry skin






Swollen bumps


## SUBTYPES


-  Ocular
-  Papulopustular
-  Erythematotelangiectatic
-  Phymatous


## COMORBIDITIES


 Gastrointestinal disorders

 Depression


 Parkinson's disease

 Cardiovascular diseases


 Dementia

 Migraine


## EPIDEMIOLOGY




5.46% affected globally




**Females** are **three times** more likely to develop **rosacea** whereas **males** are more likely to develop **severe disease**



**40%** of patients have a family member with the **condition** or **similar symptoms**



Most prevalent among **30-60-year-olds** and people from **Ethnic backgrounds** or with **fair skin**



**Cause unknown** but **mechanisms** of rosacea include abnormally functioning **immune system**, **neurovascular dysregulation**, and infestation with **Demodex mites**

## TREATMENTS

### Medication

- Papulopustular rosacea 1st line treatment: Topical therapies (azelaic acid, ivermectin, and metronidazole) papulopustular rosacea. Facial erythema: Topical brimonidine and oxymetazoline considered
- Systemic therapies (oral antibiotics; tetracycline derivatives first, followed by azithromycin or erythromycin for those who are intolerant to the former)

### Procedural therapies

- Pulsed dye laser, neodymium-doped yttrium aluminium garnet laser, or intense pulsed light for persistent facial erythema associated with rosacea
- Nasal debulking by surgical intervention or laser ablation for significant rhinophyma

### Therapies for ocular rosacea

- Minimise exposure to aggravating factors (e.g., periocular cosmetics, air conditioning)
- Alleviate symptoms with over-the-counter liposomal sprays or ocular lubricants. Preservative-free preparations best if using more than 6 times daily

### References

1. National Health Service (NHS). Rosacea. 2020. Available at: <https://www.nhs.uk/conditions/rosacea/>. Last accessed: 28 September 2021.
2. Vera N et al. Rosacea comorbidities. *Dermatol Clin*. 2018;36(2):115-22.
3. Gether L et al. Incidence and prevalence of rosacea: a systematic review and meta-analysis. *Br J Dermatol*. 2018;179(2):282-9.
4. Aponte JL et al. Assessment of rosacea symptom severity by genome-wide association study and expression analysis highlights immuno-inflammatory and skin pigmentation genes. *Human Mol Genet*. 2018;27(15):2762-72.
5. Tidy C. Rosacea and rhinophyma. 2021. Available at: <https://patient.info/doctor/rosacea-and-rhinophyma>. Last accessed: 28 September 2021.
6. National Rosacea Society (NRS). The Great Imposter. 2011. Available at: <https://www.rosacea.org/blog/2011/july/the-great-imposter>. Last accessed: 28 September 2021.
7. Farshchian M, Daveluy S. Rosacea. In: *StatPearls* [Internet]. 2021. Treasure Island (FL): StatPearls Publishing.
8. Hampton PJ et al. British Association of Dermatologists guidelines for the management of people with rosacea 2021. *Br J Dermatol*. 2021;DOI:10.1111/bjd.20485.

# Pemphigus Vulgaris and Pemphigus Foliaceus: A Single-Centre Comparative Study in Rabat, Morocco

## Editor's Pick

My choice for the Editor's Pick this issue is the highly relevant research article by Mezni et al. The authors conducted the first comparative study in Morocco of the two main pemphigus subtypes: pemphigus vulgaris and pemphigus foliaceus. By analysing the clinical course of these variants, the authors are able to provide treatment insights and recommendations for future research, which might facilitate patient stratification and the design of personalised therapeutic plans in the hospital setting.



## Desmond Tobin,

Full Professor of Dermatological Science, Director of the Charles Institute of Dermatology, UCD School of Medicine, University College Dublin, Republic of Ireland

<b>Authors:</b>	*Line Mezni, Farah El Hadadi, Mariam Meziane, Nadia Ismaili, Laila Benzekri, Karima Senouci  Department of Dermatology-Venereology, Ibn Sina University Hospital, Mohammed V University, Rabat, Morocco  *Correspondence to <a href="mailto:mezni_line@outlook.com">mezni_line@outlook.com</a>
<b>Disclosure:</b>	The authors have declared no conflicts of interest.
<b>Received:</b>	16.02.22
<b>Accepted:</b>	05.04.22
<b>Keywords:</b>	Morocco, pemphigus foliaceus (PF), pemphigus vulgaris (PV), prognosis.
<b>Citation:</b>	EMJ Dermatol. 2022; DOI/10.33590/emjdermatol/22-00052. <a href="https://doi.org/10.33590/emjdermatol/22-00052">https://doi.org/10.33590/emjdermatol/22-00052</a> .

## Abstract

**Background:** Pemphigus is a group of rare autoimmune blistering diseases affecting the skin and mucous membranes. Pemphigus foliaceus (PF) is known to be relatively benign than the other forms of pemphigus.

**Methods:** The authors carried out a single-centre retrospective study of 40 patients with PF and 125 patients with pemphigus vulgaris (PV) over a 30-year period. The aim was to compare the course of these two major variants.

**Results:** Both populations shared similar age, sex ratio, and treatment received. This investigation showed that relapses were more frequent in the group of PF, whereas the PV group needed a higher dose of corticosteroids to control the disease, a higher mortality rate, and complications were documented in this group. Severity, remissions, and mean duration of the disease were the same in both groups.

**Conclusion:** This investigation arises some doubts concerning the relative mildness of PF. Despite the improvement of the prognosis of pemphigus through the use of immunosuppressive therapy, few studies have been interested in comparing the clinical course of treated PF and PV. In the authors' experience, PF should be treated as PV, as they may share a mutual evolutive profile. Further investigations are needed to define if the prognosis of PF depends on epidemiological, environmental, and genetic factors, including the optimal therapeutic management of this disease.

### Key Points

1. While rare, both pemphigus vulgaris (PV) and pemphigus foliaceus (PF) are life-threatening autoimmune intraepidermal blistering diseases.
2. In this comparative study, the authors compared PV and PF to determine the clinical course for treating both conditions and who is the most affected (in regard to age, sex, and geographical location).
3. The authors' report indicated that patients with PV needed higher doses of corticosteroids to control their disease than patients with PF.

## INTRODUCTION

Pemphigus encloses a group of autoimmune intraepidermal blistering diseases of the skin and mucous caused by the loss of intraepidermal adhesions. It is a rare and life-threatening dermatosis. Two major subtypes have been described: pemphigus vulgaris (PV) and pemphigus foliaceus (PF). The objective of this analysis is to compare pemphigus vulgaris and pemphigus foliaceus, concerning demographic data, clinical course, and prognosis. Thus, the authors are sharing their experience in the management of these two major variants.

## PARTICIPANTS AND METHODS

The present study is a retrospective analysis of patients with pemphigus hospitalised in the University Hospital Ibn Sina in Rabat, Morocco, over 30 years (1991–2020). The authors included only PV and PF based on clinical, histological, direct immunofluorescence, and immunological features (indirect immunofluorescence). Following the consensus statement on pemphigus,<sup>1</sup> all medical files have been analysed regarding age, gender, duration, the severity of the disease, pemphigus disease area index (PDAI) score, indirect immunofluorescence level, treatment modalities, complete remission rate off therapy, healing time, relapses, patients

lost to follow-up, complications, and mortality rate. Data analysis was conducted using SPSS version 20.0 (IBM, New York City, New York, USA). Ethical approval for this study was granted by the Research Health Committee of Ibn Sina University Hospital at the Mohammed V University in Rabat, Morocco.

## RESULTS

A total of 302 patients were investigated during the research period, and only the cases of PV (125) and PF (40) were considered. **Table 1** includes the main features of the two groups. There were no major differences between PF and PV in terms of age (median age: 52 versus 53 years), gender (50% female versus 39% male), median illness duration before initiating therapy (13.0 versus 13.4 months). The PDAI score was severe in 36 cases in the PF group versus 102 cases in the PV group. The PV group showed more cases of positive indirect immunofluorescence in contrast to the PF group (76 versus 16 cases).

All patients with pemphigus received oral prednisone at the dose of 1.5 mg/kg per day. The primary outcome of the initial treatment regimen showed that 95 cases of the PV group required a higher dose of prednisone (2 mg/kg/day) to control the disease. Adjuvant therapy was

Table 1: Pemphigus demographic data and immunologic findings.

	PV (N=125)	PF (N=40)
Age (years)	53	52
Sex (male/female)	50/75	18/22
Duration before treatment (months)	13.4	13.0
Number of patients PDAI (severe)	102	36
Number of IIF-positive patients (average titre range: 640–1,280)	76	16

IIF: indirect immunofluorescence; PDAI: pemphigus disease area index; PF: pemphigus foliaceus; PV: pemphigus vulgaris.

administered to the two groups (16 PF versus 84 PV cases). In the PF group, additional treatments used were azathioprine in 13 cases, dapsone in six cases, methotrexate in one case, and rituximab in one case. In the PV group, additional treatments used were azathioprine in 36 cases, rituximab in 10 cases, cyclophosphamide in one case, and dapsone in one case. In this study, no differences were noted in the two groups regarding maintenance treatment (the drug and its dosage), and no patient was required to stop the therapy.

Table 2 highlights the course and the follow-up of patients with PF and PV. The rate of complete remission off therapy was higher in patients with PF (52.5% versus 36%), and the healing time was similar between the groups (2.7 versus 3.2 months). However, the PF group showed a greater tendency to recurrence than the PV group (42.5% versus 29.6%), over a longer period (74 versus 47 months). Concerning death and complications, patients with PV were more concerned. The mortality rate was 17.6% versus 2.5%, and iatrogenic complications were 45.6% versus 35%, yet the PF group marked an increased level of complications. In this study, 17 cases in the PF group and 37 in the PV group were lost to follow-up (Figure 1).

## DISCUSSION

PV and PF are intimately connected as autoimmune blistering diseases. Nevertheless, their dissimilarities are based on clinical

and immunohistological features. In PV, IgG autoantibodies against the *DSG3* and in some cases *DSG1* cause a suprabasal cleft by the loss of keratinocyte cell adhesion (acantholysis). Lesions occur on the oral mucous membranes as erosions, and on the healthy-looking skin as flaccid blisters. PF is frequently described as fragile cutaneous blisters and erosions appearing primarily on seborrheic areas (e.g., scalp, face, and upper trunk) which might disseminate. It is characterised by the production of antibodies directed against *DSG1*, creating a cleavage within subcorneal cells.<sup>2</sup>

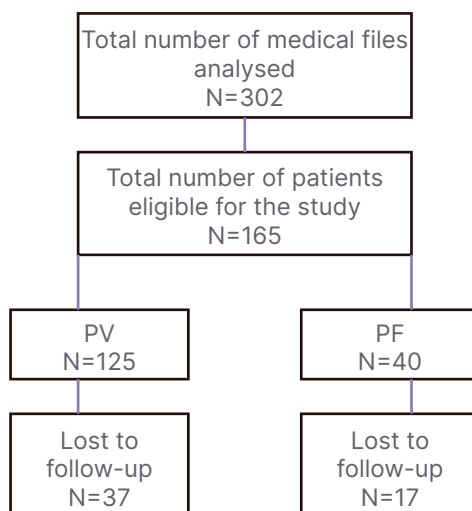
The geographical distribution of pemphigus is unequal. The annual incidence of PV ranges from 16.1 /million in Jerusalem to 0.76 /million in Finland.<sup>3</sup> PF is less common than PV; the annual incidence in Western Europe varies between 0.5–1.0/million<sup>4</sup> to 6.7/million in Tunisia.<sup>5</sup> Two forms have been described in Brazil. The typical PF seen around the world sporadically, without evidence of geographical clustering, and the endemic occurring in certain regions of Brazil may be triggered by environmental factors, known as fogo selvagem. Fogo selvagem is endemic in Brazil, occurring mainly in middle age, neighbours, and family members as it follows the course of streams and creeks. PF is also endemic in other South American countries, and in Tunisia. In a recent Moroccan study,<sup>6</sup> PV was the most reported form (50.3%), with fewer cases of PF (28.8%). In this analysis, PV was more prevalent than PF. These results are in

Table 2: Pemphigus clinical course.

	PV (N=125)	PF (N=40)
Relapse		
Frequency (%)	29.6	42.5
Meantime/treatment (months)	47	74
Remission		
Frequency (%)	36.0	52.5
Duration (months)	3.2	2.7
Number of patients lost to follow-up	37	17
Iatrogenic complications (%)	45.6	35.0
Mortality (%)	17.6	2.5

PF: pemphigus foliaceus; PV: pemphigus vulgaris.

Figure 1: Patient analysis flow chart.



PF: pemphigus foliaceus; PV: pemphigus vulgaris.

line with existing literature. While few studies have been interested in comparing the two major variants of pemphigus, the authors' work focused on analysing their clinical course. The most interesting findings were the absence of significant differences concerning demographic patterns, such as age and gender. In the northwest region of Africa, the disease affects those in the fifth decade<sup>6,7</sup> and

has a female predominance, as reported in the majority of epidemiological studies around the world; this supports the authors' findings. However, in northern Colombia, endemic PF has been reported as more common in males (95%), which speculates that the epidemiology of PF may be attributed more to environmental triggers than to race and ethnicity.<sup>8</sup>

The mean duration of the disease before treatment was long: 13 months, as reported by the Tunisian study.<sup>7</sup> In fact, it takes approximately 10 months and five doctors to make the diagnosis of PV.<sup>9</sup> The delay in diagnosis is probably due to the lack of recognition of the disease among primary care physicians, especially in PV when mucosal lesions are predominant, or in the case of delayed skin manifestations. Patients tend to see specialist doctors such as dentists, otolaryngologists, gynaecologists, and urologists, who may evoke other differential diagnoses, leading to a late referral to dermatologists. In addition, in both PV and PF, intact blisters may not be seen, which may mislead even those who are familiar with these diseases.

Both groups had a severe PDAI score, which may be explained by area of skin involvement in PF, and mucosal lesions in PV. As for the time to heal, there were no statistical differences between the two groups. These findings are in line with the results reported by Zaraq et al.<sup>7</sup> Azathioprine was the most used adjuvant therapy in the authors' practice, either in the PV or in the PF group, while dapsone was used as second-line treatment in the study of Goon and Tan.<sup>10</sup>

The authors' report showed that PV needed higher doses of corticosteroids to control the disease, and more cases of complications and mortality have been reported in this group as documented by Goon and Tan,<sup>10</sup> and an Israeli study.<sup>8</sup> Kridin et al.<sup>8</sup> have found that the median overall survival among patients with PF was longer than patients with PV (14.0 versus 10.1 years;  $p=0.05$ ), and the highest mortality rate was observed in the PV cohort. Even though these results sharpen the fact that PV is more life-threatening disease, and PF has a more favourable outcome, patients with PF presented a high tendency to relapse and a considerable rate of complications, suggesting that PF and PV may share the same course as reported by Zaraq et al.<sup>7</sup>

and Dehen et al.<sup>11</sup> For instance, Jelti et al.<sup>12</sup> have reported that the mortality rate in their research was mainly observed in elderly patients with a median age at death of 87.4 years for patients with PF versus 82.4 years for patients with PV. Interestingly, the highest mortality rate in their study concerned patients with PF (31.1% versus 19.4%), which was explained by the high proportion (32.8%) of patients older than 75 years among those with PF.<sup>12</sup>

This investigation, therefore, arises some uncertainty concerning the mildness of PF, as its prognosis may depend on geographic areas, genetic background, and environmental factors.

Untreated pemphigus had a mortality rate >70%; corticosteroid use and immunosuppressive therapy have narrowed the difference in morbidity and mortality.<sup>13</sup> Today, mortality is mainly due to treatment-related complications, older age, cardiovascular comorbidities, and the level of autoantibodies.<sup>14</sup>

In this study, flaws and barriers concern the design of the research as a retrospective single-hospital study, and the absence of dosage of the anti-desmoglein antibodies, as ELISA testing is not available in the authors' hospital, and is relatively expensive in private practices.

## CONCLUSION

Pemphigus being the most common indication for hospitalisation in the authors' department led them to conduct the first comparative study in Morocco of its two main variants. Their research advocates that PF and PV share similar evolutive profiles. However, prospective, multicentre trials based on demographic profile, genetic analysis, and prognostic factors are, therefore, needed to enhance the knowledge of this pathology in Morocco, to facilitate patient stratification, and to design personalised therapeutic plans in the hospital setting.

### References

- Murrell DF et al. Consensus statement on definitions of disease, end points, and therapeutic response for pemphigus. *J Am Acad Dermatol.* 2008;58(6):1043-6.
- Stanley JR. "Pemphigus," Freedberg IM et al. (eds.), *Dermatology in General Medicine* (1999) 4<sup>th</sup> edition, New York: McGraw-Hill, pp. 654-66.
- Hietanen J, Salo OP. Pemphigus: an epidemiological study of patients treated in Finnish hospitals between 1969 and 1978. *Acta Derm Venereol.* 1982;62:491-6.
- Stanley J. "Pemphigus," Wolff K et al. (eds.), *Fitzpatrick's Dermatology in General Medicine* (2008) New

- York: McGraw-Hill, pp. 459-68.
5. Bastuji-Garin S et al. Comparative epidemiology of pemphigus in Tunisia and France: unusual incidence of pemphigus foliaceus in young Tunisian women. *J Invest Dermatol.* 1995;104(2):302-5.
  6. El Hadadi F et al. Epidemiology of pemphigus: a single-center overview in Morocco. *Int J Dermatol Venereol.* 2022;5(1):20-6.
  7. Zaraa I et al. Pemphigus vulgaris and pemphigus foliaceus: similar prognosis? *Int J Dermatol.* 2007;46(9):923-6.
  8. Kridin K et al. Pemphigus vulgaris and pemphigus foliaceus: differences in epidemiology and mortality. *Acta Derm Venereol.* 2017;97(9):1095-9.
  9. International Pemphigus and Pemphigoid Foundation. Biopsies save lives. Available at: <http://www.pemphigus.org/awareness/about-the-awareness-campaign/campaign-overview/>. Last accessed: 6 January 2022.
  10. Goon ATJ, Tan SH. Comparative study of pemphigus vulgaris and pemphigus foliaceus in Singapore. *Australas J Dermatol.* 2001;42(3):172-5.
  11. Dehen L et al. [Comparative study of the development and prognosis of pemphigus vulgaris and seborrheic pemphigus]. *Ann Dermatol Venereol.* 1993;120(12):874-8. (In French).
  12. Jelti L et al. Incidence and mortality of pemphigus in France. *J Invest Dermatol.* 2019;139(2):469-73.
  13. Morgado-Carrasco D et al. [RF-rituximab: revolutionizing the treatment of pemphigus]. *Actas Dermosifiliogr.* 2018;109(2):177-8. (In Spanish).
  14. Baican A et al. Prediction of survival for patients with pemphigus vulgaris and pemphigus foliaceus: a retrospective cohort study. *Orphanet J Rare Dis.* 2015;10:48.

FOR REPRINT QUERIES PLEASE CONTACT: [INFO@EMJREVIEWS.COM](mailto:INFO@EMJREVIEWS.COM)




# Dermatophyte Monitoring in an Iranian Training Dermatology Hospital

## Authors:

\*Kambiz Diba,<sup>1,2</sup> Arezoo Gheibi,<sup>3</sup> Khosro Hazrati,<sup>1</sup> Pouria Rokhsartalab<sup>4</sup>

1. Cellular and Molecular Research Center, Urmia University of Medical Sciences, Iran
2. Department of Medical Mycology, School of Medicine, Urmia, Iran
3. Department of Medical Microbiology, University of Istanbul, Turkey
4. School of Medicine, Urmia University of Medical Sciences, Iran

\*Correspondence to kdiba@umsu.ac.ir



## Acknowledgements:

The study data was extracted from a research project approved and supported by the deputy of research and technology, Urmia Medical Sciences University (ethics number: IR.UMSU.REC.1399.190; research code: 10302).

## Received:

09.06.21

## Accepted:

20.12.21

## Keywords:

Dermatophyte, molecular epidemiology, restriction fragment length polymorphism (RFLP).

## Citation:

EMJ Dermatol. 2022; DOI/10.33590/emjdermatol/21-00126. <https://doi.org/10.33590/emjdermatol/21-00126>.

## Abstract

**Introduction:** The most common cutaneous fungal infections are caused by dermatophyte fungi such as *Microsporum*, *Trichophyton*, and *Epidermophyton*. In this study, the epidemiologic trends and the predominant organisms causing dermatophytosis in Urmia, Northwest Iran, were identified.

**Aims and objectives:** To get better perception of dermatophyte distribution in Northwest Iran, the authors studied the identification of isolated dermatophytes from human specimens by using a fast and cheap molecular method: PCR-based restriction fragment length polymorphism (PCR-RFLP). The authors also aimed to use this method in for rapid and reliable identification of medically important and common dermatophytes at the level of species.

**Methods:** The study samples were collected from clinically suspected cutaneous lesions. All the specimens were transported to Medical Mycology Center, Urmia Medical Sciences University (UMS), Iran. First of all, a conventional diagnosis was carried out, which included microscopic examination and culture of sabouraud dextrose agar medium with antibiotics: chloramphenicol and cycloheximide. All the dermatophyte isolates were then identified at the level of species by the molecular method of PCR-RFLP.

**Results:** From the tested 357 clinical specimens, 30 dermatophytic isolates were identified. The percentage rate of dermatophyte species were *Trichophyton mentagrophytes* (36%), *Microsporum canis* (32%), *Microsporum gypseum* (16%), *Trichophyton rubrum* (4%), and *Epidermophyton floccosum* (12%).

**Conclusion:** By using of PCR-RFLP, a fast and reliable identification of these species is possible. This molecular method provided an opportunity for dermatophyte identification at the species level.

## Key Points

1. Dermatophyte fungi are the cause of the majority of common cutaneous fungal infections. Accurate identification of the species of dermatophytes is needed to improve diagnosis, control environmental and animal sources of infection, and develop preventive strategies.

2. Conventional phenotypic identification of dermatophyte fungi can be challenging due to several factors, including uniformity of microscopic appearance and sterile mycelia. This study analysed the effectiveness of PCR-based restriction fragment length polymorphism (PCR-RFLP) for rapid and reliable identification of common dermatophytes.

3. Dermatophyte species can be quickly and reliably identified using PCR-RFLP, which can help inform appropriate treatment choice.

## INTRODUCTION

Dermatophytes are the keratinophilic moulds living on the superficial layer of human and animal skin and are transmitted by direct and indirect contact with infecting debris or soil.<sup>1-4</sup> These fungi are not able to cause serious and fulminate infections. The diseases caused by dermatophytes may have important clinical consequences, including secondary bacterial infections, remedial failures, and mental difficulties.<sup>5</sup> For the best choices of antifungal drugs or treatment protocols, the reliable identification of the species level is necessary as some dermatophyte species such as *Trichophyton rubrum* are usually resistant to routine treatments. A correct and rapid identification of dermatophytes at the species level helps to improve the diagnosis of dermatophytic infections<sup>6</sup> and control environmental and animal sources of infection, resulting in the development of preventive strategies.<sup>7</sup>

Routinely used characteristics for identifying of dermatophytes are clinical symptoms, culture parameters, microscopic features, and physiological examinations. However, the differentiation of dermatophytes is, in some cases, hard and confusing because of overlapping morphologic features, polymorphism, and shifting formation.<sup>8</sup> In fact, the classic identification of isolates using morphologic features has been complicated by their overlapping characteristics, variability, and pleomorphism. Mating as a means of identification is not always practical as a result of the need to keep a library of opposite mating

types for each species. Furthermore, many of the anamorphic species lack a teleomorph. A variety of chemotaxonomic methods have been developed to bypass the traditional methods of identification and to determine relationships between various species.<sup>9</sup>

During last few decades, many researchers have tried to design new molecular methods for fast identification of dermatophyte fungi at the species level in clinical specimens and cultures.<sup>10-11</sup> Alternative molecular methods to the identification of dermatophyte fungi have been used through techniques such as arbitrarily primed PCR,<sup>12</sup> random amplified polymorphic DNA analysis,<sup>13,14</sup> and restriction analysis of mitochondrial DNA<sup>15</sup> and recombinant DNA (rDNA),<sup>16,17</sup> which are generally adequate for various species.

The authors studied the identification of isolated dermatophytes from human specimens by using the fast and cheap molecular method, PCR-based restriction fragment length polymorphism (PCR-RFLP) to get better perception of dermatophyte distribution in Northwest Iran. They also aimed to use this method in for rapid and reliable identification of medically important and common dermatophytes at the level of species.

## METHODS

The authors' cases were selected among patients with the clinical manifestation, suspected to be dermatophytosis. For 7 years, starting in October

2011, 357 clinical specimens were collected (100 samples taken during the Year 1). The specimens were taken from the scalp, body, palm, foot, and nails by scrapping the skin and hair lesions at the dermatology clinic of Imam Khomeini University Hospital, Urmia, Iran, and transported to the Medical Mycology Center, Urmia Medical Sciences (UMS) University, Iran. All clinical specimens were obtained from cases applied for routine mycological examinations; therefore, it was not necessary to prepare a letter of consent for the authors' cases due to the provisions of the Committee of Ethics, and the authors also got approval from the Deputy of Research, UMS University. A direct microscopic examination was carried out on the specimens using potassium hydroxide 10–20%, and the wet mounts to detect the pathogenic forms of dermatophyte, including septate mycelia and arthroconidia.

Also, basic culture medias such as sabouraud glucose agar 2% and sabouraud agar, with chloramphenicol 50 mg/L and cycloheximide 500 mg/L, were used for the detection of dermatophytes in the specimens. Then, morphologic identification of dermatophytes at species level was carried out based on the macroscopic and microscopic characteristics. The macroscopic features, including colony size, topography and textures, production of pigment, and fruiting bodies, were considered<sup>18</sup> as well as the microscopic characteristics, including shape and size of macroconidia or microconidia conidia, mycelia, and other characteristics.

### DNA Extraction

Dermatophytic mycelia for the DNA extraction harvested from the 48–72 hours growth in sabouraud glucose broth. A manual DNA extraction using 0.4 mm glass beads and phenol–chloroform was performed. The lysis solution included: 1 mM ethylenediaminetetraacetic acid, 1% sodium dodecyl sulfate, 100 mM sodium chloride, 10 mM tris-hydroxymethyl aminomethane hydrochloride (Tris-HCl), and 2% Triton X-100, mixed in distilled water.<sup>16</sup>

### PCR for Identification

The PCR profile included 5 µL of the DNA template in a total volume of 50 µL, containing a PCR buffer (20 mM Tris-HCl at pH 8), 50 mM potassium chloride, and 0.1 mM of each primer.

The authors used rDNA universal primers for the amplification of the internal transcribed spacer (ITS) regions (Primer F :5'- TCC GTA GGT GAA CCT GCG G - 3'; and Primer R: 5'- TCC TCC GCT TAT TGAT TAT GC - 3') and 1.5 U of Taq polymerase DNA (Mirhendi Molecular Biology Lab, Tehran University of Medical Sciences [TUMS], Iran).<sup>16</sup> The reactions performed in a thermocycler (XP Cyclor, BIOER, Hangzhou, China). Thermal programme included an initial DNA denaturation at 95 °C for 5 minutes, followed by 30 cycles of denaturation at 95 °C for 30 seconds, annealing at 55 °C for 30 seconds, and extension at 72 °C for 1 min, with a final extension at 72 °C for 5 min. The PCR products were subjected to a 1.5% agarose gel electrophoresis and were documented using a UV documentation system (Syngene, Cambridge, UK).

### Digestion of PCR Products

The restriction enzyme MvaI was used in RFLP.<sup>16</sup> For each reaction, 13 µL of PCR product was directly digested by 5 U (0.5 µL) of the restriction enzyme in 1.5 µL of the enzyme buffer, at 37 °C for 180 min. Digested PCR products were subjected to 2% agarose gel electrophoresis. The identification based on the differential patterns among the medically important dermatophytes at the level of species (Table 1).

## RESULTS

As expected, amplification of rDNA's ITS regions resulted in a PCR pattern with similar electrophoretic bands in size (600–700 bp), which distinguished no dermatophytes in this study (Figure 1). Digestion of the PCR products with MvaI in PCR-RFLP made a differential electrophoretic pattern that some tested dermatophyte species, including *Trichophyton mentagrophytes*, *Microsporum canis*, *Microsporum gypseum*, *T. rubrum*, and *Epidermophyton floccosum* were identified (Figure 1). The morphologic identification, confirmed by PCR-RFLP, include some macroscopic and microscopic features that are shown in the figures.

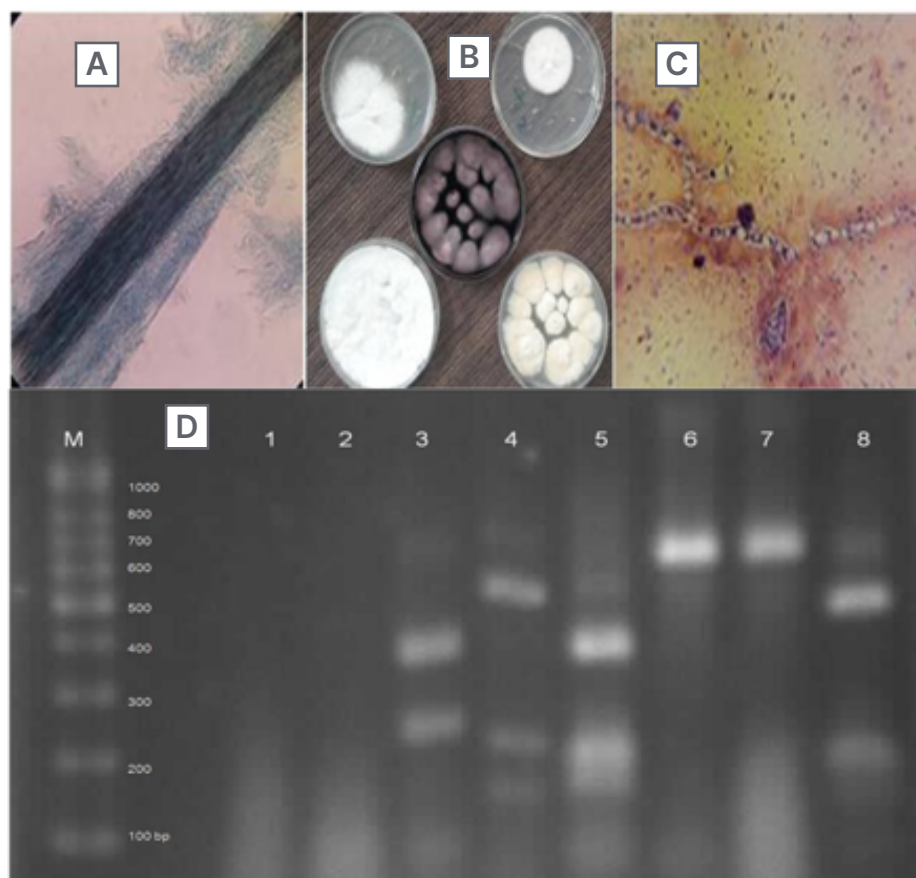
Among all the studied cases, 25 (7%) were identified with a dermatophyte infection. The findings of PCR-RFLP confirmed five dermatophytic species including: *T.*

**Table 1: Frequency and percentage of dermatophytes species identified by the PCR-restriction fragment length polymorphism method.**

Dermatophyte species	Missed	Confirmed	Total
<i>M. canis</i>	2 (40%)	6 (30%)	8 (32%)
<i>T. mentagrophytes</i>	3 (60%)	6 (30%)	9 (36%)
<i>M. gypseum</i>	0 (0%)	4 (20%)	4 (16%)
<i>T. rubrum</i>	0 (0%)	1 (5%)	1 (4%)
<i>E. floccosum</i>	0 (0%)	3 (15%)	3 (12%)
Total	5 (100%)	20 (100%)	25 (100%)

*E. floccosum*: *Epidermophyton floccosum*; *M. canis*: *Microsporium canis*; *M. gypseum*: *Microsporium gypseum*; *T. mentagrophytes*: *Trichophyton mentagrophytes*; *T. rubrum*: *Trichophyton rubrum*.

**Figure 1A–D:** The pictures A to C show the microscopic feature of a hair infection, some dermatophyte colonies and the microscopic picture of a dermatophytic mycelium (respectively), and picture D shows PCR-RFLP pattern of some identified dermatophytes in Lanes: 3, 5, 4, 8 and not digested DNA bands 6, 7 of the studied dermatophyte species.



mentagrophytes (36%), *M. canis* (32%), *M. gypseum* (16%), *T. rubrum* (4%), and *E. floccosum* (12%); although, two cases of *M. canis* and three of *T. mentagrophytis* were missed (Table 1). Among all the isolated dermatophytes, the *T. mentagrophytes* complex and *M. canis* were the most frequent species (Table 2). The most common sites encountered by dermatophytes were the scalp (skin and hair), nail, body, and palm, and the most frequent infections were tinea capitis and tinea unguium. Among all dermatophyte species, *M. canis*, *M. gypseum*, and the *T. mentagrophytes* complex were the most isolated, and *Trichophyton schoenleinii* was identified by PCR-RFLP as the exceptional case in this study.

## DISCUSSION

Conventional (phenotypic) identification of dermatophyte fungi is problematic due to a lack of stable characteristics distinguishing between isolates. Most *T. rubrum* strains show uniformity in both microscopically and colonial appearance, although variations in colony morphology do exist.<sup>19</sup> Likewise, in some instances, the causative dermatophyte fails to produce any obvious reproductive structure in culture (termed sterile mycelia), which makes it impossible for ultimate definitive diagnosis.

Many typical isolates of common dermatophytes can be identified directly from primary isolation media, particularly sabouraud glucose agar and potato glucose or potato flakes agar. Identification characters include colony pigmentation, texture, and growth rate, and distinctive morphological structures such as microconidia, macroconidia, spirals, pectinate branches, pedicels, and nodular organs.<sup>20</sup> In spite of its some disadvantages such as expensive material, including PCR kits and restriction enzymes, and the limited potency of identification for most species, PCR-RFLP prepares a differential pattern for the identification of dermatophytes to the species level in a rapid and reliable manner.

In the authors' study, use of PCR-RFLP provided the authors with a simple and rapid diagnostic method compared with the conventional culture and microscopy. However, a reliable statistical comparison between the two methods used need much more identified cases from each dermatophyte species. The use of PCR-RFLP can be of great use; however, when it is not possible to use it for the above specified reactions, the classical method can be still valid and advisable for identifying species with well-characterised morphological aspects.

In the study by Kamiya et al.,<sup>21</sup> identification was obtained from the PCR and PCR-RFLP

**Table 2: Data of identification by the conventional method based on the involved site.**

Infection site	<i>T. mentagrophytes</i>	<i>M. canis</i>	<i>M. gypseum</i>	<i>T. rubrum</i>	<i>T. schoenleinii</i>	Total
Scalp (skin and hair)	2 (14.0%)	6 (66.6%)	4 (100.0%)	0 (0%)	1 (100.0%)	13 (43.3%)
Nail	8 (57.1%)	0 (0%)	0 (0%)	1 (50.0%)	0 (0%)	9 (30.0%)
Body	3 (21.4%)	3 (25.0%)	0 (0%)	1 (50.0%)	0 (0%)	7 (23.3%)
Palm	1 (7.1%)	0 (0%)	0 (0%)	0 (0%)	0 (0%)	1 (3.3%)
Total	14 (100%)	9 (100%)	4 (100%)	2 (100%)	1 (100%)	30 (100%)

*M. canis*: *Microsporum canis*; *M. gypseum*: *Microsporum gypseum*; *T. mentagrophytes*: *Trichophyton mentagrophytes*; *T. rubrum*: *Trichophyton rubrum*; *T. schoenleinii*: *Trichophyton schoenleinii*.

targeting the DNA Type II topoisomerase gene and using some restriction enzymes in all cases. Also, Ganlin et al.<sup>22</sup> identified six common dermatophytes by using PCR-RFLP targeting the Type II topoisomerase gene. All six dermatophytes were identified to species level.<sup>22</sup>

In the present study, the use of PCR-RFLP with the single restriction enzyme MvaI, according to the previous studies,<sup>23</sup> enabled the identification of most of the *Aspergillus* species, which was proved in this study by using the morphologic method. There have been several restriction enzymes for the digestion in PCR-RFLP to better identify species, and the newer ones could have been used but in the present study, MvaI was selected to compare the data with the results of similar works. This is a well-known restriction enzyme for dermatophytes identification. All tested dermatophytes were identified at species level and no obvious difference found in terms of identification among the species patterns. Some more studies have also confirmed the present molecular findings: Mirzahoseini et al.<sup>24</sup> studied the application of PCR-RFLP by using different restriction enzymes, including MvaI, HinfI, and HaeIII for the differentiation of isolated dermatophytes at the genus or species level.<sup>23</sup>

However, there were some exceptions in the present findings of molecular study, including *M. canis*, *M. gypseum*, and *T. schoenleinii*, which did not match with the other methods. In fact, 30 dermatophyte isolates (8.5%), recovered in the culture, were identified and confirmed by a molecular test based on the rDNA ITS regions. Molecular identification of the isolated dermatophytes provided reliable information about the frequency of dermatophytic infections in Northwest Iran. With the ignorance of the mentioned exceptions, *M. canis*, *T. mentagrophytes*, *M. gypseum*, *T. rubrum*, and *E. floccosum* were the most frequent isolated dermatophytes in Northwest Iranian

cases in the present molecular study. Other Iranian surveys have presented similar results, as shown in studies by Mirzahoseini et al.<sup>24</sup> and Zamani<sup>23</sup>, where *T. mentagrophytes*, *T. rubrum*, *T. verrucosum*, *M. canis*, and *E. floccosum* are the main isolated dermatophyte species.

An Indian epidemiologic survey reported predominant dermatophytes including *T. rubrum*, *T. violaceum*, *T. mentagrophytes*, and *E. floccosum*. In contrast to the present findings in Iran, the major isolates of scalp and body of the Indian study were *T. violaceum* and *T. rubrum*, respectively. Also, in a Japanese study, six dermatophyte species of *T. rubrum*, *T. mentagrophytes*, *Trichophyton tonsurans*, *M. canis*, *M. gypseum*, and *E. floccosum* were obtained from 305 patients with tinea. *M. canis* seems to be prevalent and a more common cause of dermatophytosis than other dermatophytes agents.<sup>21</sup> It is believed that the distribution pattern of dermatophyte species in Asia follows a general incidence with some differences.

Furthermore, according to Glanin et al.,<sup>22</sup> *T. rubrum*, *T. mentagrophytes*, *Trichophyton verrucosum*, *M. canis*, *M. gypseum*, and *E. floccosum* represented the main causes of human dermatomycosis, which were the most frequently isolated species, in the dermatology department of University Hospital Graz, Austria. This point was also in agreement with the present results.

## CONCLUSION

By using molecular method in the present study, a fast and reliable identification of medically important dermatophytes at species level is possible. To make the best drug choice for treatment, it is necessary the identity the dermatophyte fungi at the species level.

### References


- Mahmoudabadi AZ. A study of dermatophytosis in South West of Iran (Ahwaz). *Mycopathologia*. 2005;160(1):21-4.
- Falahati M et al. Epidemiology of dermatophytoses in an area south of Tehran, Iran. *Mycopathologia*. 2003;156(4): 279-87.
- Khosravi AR, Mahmoudi M. Dermatophytes isolated from domestic animals in Iran. *Mycoses*. 2003;46(5-6):222-5.
- Chadeganipour M et al. Prevalence and etiology of dermatophytoses in Isfahan, Iran. *Mycoses*. 1997;40(7-8):321-4.
- Panasiti V et al. Epidemiology of dermatophytic infections in Rome, Italy: a retrospective study from 2002 to 2004. *Med Mycol*. 2007;45(1):57-60.
- Aghamirian MR, Ghanaian SA. Dermatophytoses in outpatients attending the Dermatology Center of Avicenna Hospital in Qazvin,

- Iran. *Mycoses*. 2007;51(2):155-60.
7. Gräser Y et al. Molecular taxonomy of *Trichophyton mentagrophytes* and *T. tonsurans*. *Med Mycol*. 1999;37(5):315-30.
  8. Weitzmani I, Summerbell R C. The dermatophytes. *Clin Microbiol Rev*. 1995;8(2):240-59.
  9. Turin Let al. Fast, simple and highly sensitive double-round polymerase chain reaction assay to detect medically relevant fungi in dermatological specimens. *Eur J Clin Invest*. 2000;30(6):511-18.
  10. Kanbe T et al. PCR based identification of common dermatophyte species using primer sets specific for the DNA topoisomerase II genes. *J Dermatol Sci*. 2003;32(2):151-61.
  11. Gräser Y et al. Identification of common dermatophytes (*Trichophyton*, *Microsporum*, *Epidermophyton*) using polymerase chain reactions. *Br J Dermatol*. 1998;138(4):576-82.
  12. Liu D et al. Use of arbitrarily primed polymerase chain reaction to differentiate *Trichophyton* dermatophytes. *FEMS Microbiol Lett*. 1996;136(2):147-50.
  13. Mochizuki Tet al. Random amplification of polymorphic DNA is useful for the differentiation of several anthropophilic dermatophytes. *Mycoses*. 1997;40(11-12):405-9.
  14. Sakata Y, Ushigami T, Anzawa K, Mochizuki T. Molecular epidemiology of *Trichophyton tonsurans*, the causative dermatophyte of the tinea gladiatorum epidemic in Japan between 2011 and 2015. *Jpn J Infect Dis*. 2018;71(2):140-4.
  15. Mochizuki T et al. Genetic homogeneity of *Trichophyton mentagrophytes* var. *interdigitale* isolated from geographically distant regions. *J Med Vet Mycol*. 1996;34(2):139-43.
  16. Mirhendi SH et al. PCR-restriction enzyme method based on the polymorphism in ribosomal-DNA for identification of the most important dermatophyte species in Iran. *Iran J Dermatol*. 2007;10(41):219-28.
  17. Rezaei-Matehkolaei A et al. Use of single-enzyme PCR-restriction digestion barcode targeting the internal transcribed spacers (ITS rDNA) to identify dermatophyte species. *Iran J Public Health*. 2012;41(3):82-94.
  18. Larone DH. *Medically Important Fungi: A Guide to Identification*. 4th edition. Washington D.C., USA: ASM Press. Chapter III:333-57.
  19. Chen M et al. Epidemiology of fungal infections in China. *Front Med*. 2018;12(1):58-75.
  20. Erbagci Z et al. A prospective epidemiologic survey on the prevalence of onychomycosis and dermatophytosis in male boarding school residents. *J Am Acad Dermatol*. 2005;159(3):347-52.
  21. Kamiya A et al. PCR and PCR-RFLP techniques targeting the DNA topoisomerase II gene for rapid clinical diagnosis of the etiologic agent of dermatophytosis. *J Dermatol Sci*. 2004;34(1):35-48.
  22. Ganlin H et al. Identification of common species of dermatophytes by PCR- RFLP. *J Huazhong Univ Sci Technolog Med Sci* 2005;25(4):458-60.
  23. Zamani S et al. Epidemiological trends of dermatophytosis in Tehran, Iran: a five-year retrospective study. *J Mycol Med*. 2016;26(4):351-8.
  24. Mirzahoseini H et al Application of PCR-RFLP to rapid identification of the main pathogenic dermatophytes from clinical specimens. *Iran J Public Health*. 2009;38(1):18-24.

FOR REPRINT QUERIES PLEASE CONTACT: [INFO@EMJREVIEWS.COM](mailto:INFO@EMJREVIEWS.COM)

# Treatment with Hyaluronic Acid Injections in a Patient with Craniosynostosis

<b>Authors:</b>	*Daniel Alejandro Muszalski, <sup>1</sup> Luciana Yacomotti <sup>2</sup> 1. Department of Dermatology, DermaBaires, Buenos Aires, Argentina 2. Medical Director, GC Skin, Los Angeles, California, USA *Correspondence to <a href="mailto:consultoriordermabaires@gmail.com">consultoriordermabaires@gmail.com</a>
<b>Disclosure:</b>	The authors have declared no conflicts of interest.
<b>Received:</b>	27.05.21
<b>Accepted:</b>	13.01.22
<b>Keywords:</b>	Craniosynostosis, fillers, frontal region, hyaluronic acid, temporal region.
<b>Citation:</b>	EMJ Dermatol. 2022; DOI/10.33590/emjdermatol/21-00118.



## Abstract

**Case report:** A case of a 25-year-old White female left with residual bone deformity after surgical correction of craniosynostosis during childhood is presented here. The significant psychological discomfort from her deformity caused the patient to experience clinical depression and social phobia.

**Objectives:** The use of soft tissue fillers has grown in popularity for minimally invasive cosmetic procedures. The authors discuss the use of hyaluronic acid (HA) as an available treatment option for the reconstructive volumisation of postsurgical bony deformities in patients with congenital craniosynostosis.

**Discussion:** Although fat graft techniques have previously been described, to the best of the authors' knowledge, this is the first report of HA fillers as an available treatment option for the reconstructive volumisation of residual bony deformities in patients with craniosynostosis. The negative emotional impact of facial deformities can be dramatically improved by these procedures, making HA a valuable option in providing patients with a highly acceptable cosmetic result.

**Conclusions:** HA can be successfully used as a non-surgical alternative to correct bone deformities of any aetiology. It is a relatively simple and effective technique that leads to cosmetically acceptable results. The authors emphasise the importance of training to gain an in-depth knowledge of the facial anatomy. Intravascular injections in the forehead and temporal fossa can lead to skin necrosis or blindness, therefore it is imperative to perform safe and proper facial aesthetics injections and to manage possible complications before injections.



## Key Points

1. This article is important because it shows that a minimally invasive treatment with a very safe product such as hyaluronic acid can treat patients with facial deformities (such as this case of progressive facial hemiatrophy), providing them with a better quality of life from the aesthetic point of view.

2. This manuscript presents a clinical case of a patient with progressive facial hemiatrophy, who was treated with hyaluronic acid fillers.

3. With in-depth training in facial anatomy, it is possible to inject patients who consult for facial deformities and improve their quality of life with a minimally invasive procedure, since these pathologies are highly stigmatising and have a negative impact on their self-esteem. Also, in case of a vascular event, hyaluronic acid can be reversed with hyaluronidase.

## INTRODUCTION

Craniosynostosis is a condition in which one or more sutures in a baby's skull fuse together prematurely, causing growth problems of the brain and skull. Premature closure of the sutures can also cause deformities of the facial bones and skull. Craniosynostosis may arise as part of a genetic syndrome (e.g., Apert, Crouzon, Pfeiffer, Saethre–Chotzen), but it occurs more frequently as an isolated defect.<sup>1</sup>

A full range of surgical options are available for craniosynostosis treatment, from strip craniectomy to whole-vault cranioplasty. The main goal of surgery is to reduce intracranial pressure and treat the resulting craniofacial asymmetries. However, the most common complication after craniosynostosis surgery is an incomplete correction of deformities, which can sometimes lead to aesthetic and psychological problems that impact the patient's self-esteem.<sup>2</sup> It is, therefore, essential to treat these patients using a multidisciplinary approach.<sup>3</sup> Implementing a long-term assessment is essential to develop additional treatments.

Various tools that restore volume in a defined area to treat residual craniosynostosis deformities have been described, including autologous fat transfer. This technique is minimally invasive and is a good alternative for improving fronto-orbital asymmetries in residual craniosynostosis deformities.<sup>4,5</sup> Augmentation using the patient's fat, which was first documented in the 20<sup>th</sup> century, can be employed to replace volume after trauma.

## CASE REPORT

Here, a case of a 25-year-old female with a history of congenital craniosynostosis is reported. The patient underwent corrective surgery at a young age, although her records are not available for review. The frontotemporal bone deformity was the patient's chief complaint. Several plastic surgeons evaluated the patient: none came up with an optimal treatment plan, instead she was referred to various psychiatrists and psychologists. The patient was diagnosed with depression and social phobia and was started on several antidepressant medications. The patient's quality of life was severely impaired, and they ended up having to work from home.

After assessing the patient, the authors came up with a treatment plan consisting of hyaluronic acid (HA) fillers. The treatment was used to improve frontotemporal deformity and was performed in two sessions, 15 days apart. High elastic modulus (G') HA (20 mg/mL) was used in this case, since the thickness of the skin allowed it. An advantage of using high viscosity HA fillers is that they have a longer duration of effect, up to 18 months. However, intermediate or low G' HA (15.0–17.5 mg/mL) is also a good option as the filler can be evenly distributed with a gentle massage.

The authors decided to use needles instead of cannulas for technical reasons, modifying the angle of entry into the skin according to the injection site. Prior injection aspiration was performed at each point to minimise the chance of intravascular occlusion. The supratrochlear and supraorbital foramina were both identified

to avoid deep injection near them. The boluses injected were always small in order to reduce the occurrence of inadvertent intravascular injection. A supraperiosteal injection on the temporal region was performed, 1 cm above the orbital rim on the temporal fusion line and 1 cm lateral to this point, using the 'one up, one over' technique to identify the safest point when injecting the temporal fossa.

Pre-procedure (Figure 1), immediate post-procedure (Figure 2), and 18 months post-procedure (Figure 3) photographs were then taken.

## DISCUSSION

HA fillers are a promising alternative to consider for the treatment of cranial bone deformities in patients with craniosynostosis and other aetiologies. The use of autologous fat injections for the correction of bone deformities has been previously reported.<sup>5</sup> Recent data by Coleman et al.<sup>6</sup> suggest an improved duration of correction with autologous fat transfer. However, it is not clear whether autologous fat is an ideal soft tissue filling agent, particularly given its highly variable duration of correction. Additionally, fat grafting procedures most often involve surgery with some amount of anaesthesia; this approach requires surgical liposuction to harvest adipose tissue and several sessions to achieve the desired results.

Although fat graft techniques have previously been described, to the best of the authors' knowledge, this is the first report of HA fillers as an available treatment option for reconstructive volumisation of residual bony deformities in patients with craniosynostosis. One of the main advantages of HA fillers is their easy reversibility, which is vital in the event of accidental intravascular injection, as hyaluronidase could revert the consequent tissue damage or eventual amaurosis. In this case report, the authors chose a cross-linked, high G' HA (20 mg/mL) that can last up to 18 months. Surprisingly, the correction lasted longer than expected, remaining intact at the 18-month follow-up.

Lazzeri et al.<sup>7</sup> reviewed 29 articles describing 32 patients with iatrogenic blindness: in 15 patients, blindness occurred after fat injection; in the other

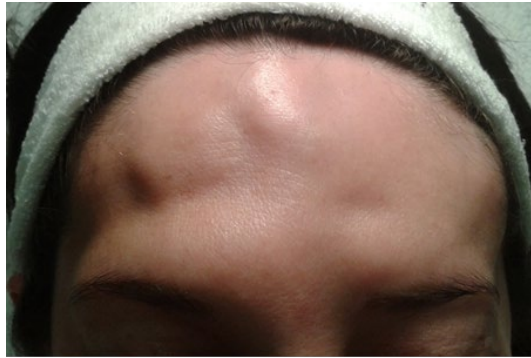17 patients, it followed the injection of various other materials, including silicone oil, calcium hydroxyapatite, bovine collagen, and HA, with blindness occurring after HA injections in two out of these 17 patients.<sup>7</sup> Furthermore, Chatrath et al.<sup>8</sup> studied a total of 190 cases of filler-induced blindness, the primary cause of which was due to autologous fat injections (90 cases; 47%), with the second most common cause attributed to HA injections (53 cases; 28%).<sup>8</sup>

Goodman et al.<sup>9</sup> found that accidental intravascular injection, even among very experienced injectors, was high. Although 71% had 11 years or more of experience, 62% of these injectors experienced an inadvertent intravascular injection, which reaffirms that anatomical knowledge is essential to minimise these complications.<sup>9</sup> The authors recommend that injections of the frontotemporal region should be performed by physicians with extensive knowledge of the local anatomy. Intravascular injections and extrinsic compressions are more frequently associated with skin necrosis, and studies have shown that small amounts of filler can occlude wide arterial paths. The equation for the volume of a cylinder ( $\pi r^2 h$ ) tells us that just 0.01 mL of a product would be enough to fill 5.00 cm of a 0.05 cm diameter vessel, assuming that it did not dilate.<sup>10</sup> Intra-arterial injections in the frontotemporal region, supraorbital artery, supratrochlear artery, or the anterior or frontal branch of the superficial temporal artery can also potentially deliver the filling directly to the ophthalmic artery, and from there to the central retinal artery, resulting in amaurosis.<sup>11-13</sup>

For skin preparation, chlorhexidine plus alcohol was used to achieve the best antibacterial coverage.<sup>14,15</sup> While the use of cannulas is considered safer for injection, the authors decided to use 27-gauge needles due to bone irregularities in the patient.<sup>15-18</sup>

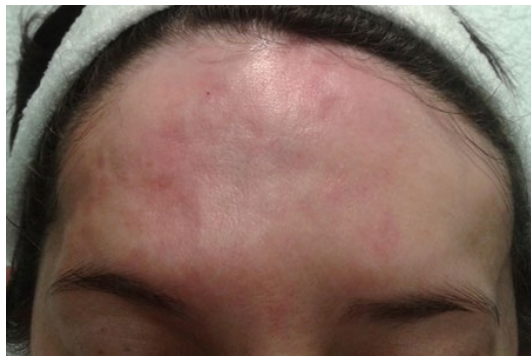The needle was directed oblique to the skin (at a 45° angle) to prevent filler from leaking out through the puncture site and being deposited above the frontal muscle, with the eventual need of removal with hyaluronidase.<sup>16</sup> After the needle was inserted, the syringe plunger was withdrawn. At least 5 seconds should pass to observe if blood aspirates into the needle hub to reduce the risk of intravascular injection,

Figure 1: A pre-procedure photograph of the patient.



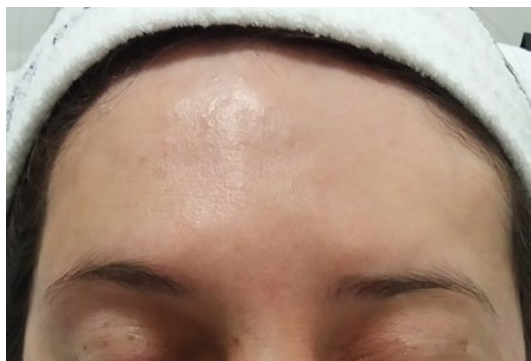*Bone irregularity at the frontal and temporal levels, with depressions of different depths, are evidenced by the shadows generated.*

Figure 2: A photograph of the patient taken immediately post-procedure.



*An improvement in bone irregularity and depressions is evident, although transient erythema still persisted in the patient due to recent treatment.*

Figure 3: A photograph of the patient taken 18 months post-procedure.



*The final result with the disappearance of bone irregularity and depressions can be seen here.*

although this aspiration time is controversial, and many authors recommend waiting 10 seconds.<sup>19,20</sup> The authors of this study recommend a safety margin of 2 cm above the supraorbital and supratrochlear foramen (superior orbital border).<sup>21,22</sup> The multiple supraperiosteal bolus injection techniques were applied with a small amount of filler (0.1 mL) as avoiding larger boluses minimises tissue damage in the event of inadvertent intravascular injection or extrinsic vascular compression. Lower volumes injected per point will also significantly decrease the chance of amaurosis by intravascular injection.<sup>23</sup> Some authors recommend boluses of less than 0.84 mL in the periorbital region, and boluses less than 0.03 mL in regions close to the supratrochlear foramen.<sup>24-26</sup> Other authors state that, by injecting aliquots <0.10 mL in the facial soft tissues, they can already overcome the entire volume of the supratrochlear artery from the injection site at the glabella to the level of the orbital apex.<sup>26</sup>

Supraperiosteal injection on the temporal region was performed 1 cm above the orbital rim on the temporal fusion line, and 1 cm lateral to this point using the 'one up, one over' technique: this is the safest point when injecting the temporal fossa. The needle was inserted perpendicular to

the skin, at a 90° angle down to the periosteum. Prior to injection, the plunger was retracted, and, in the absence of blood, 0.40–0.50 mL of HA was injected. With the use of the 'one up, one over' technique, the filler injected into the temporal fossa generated a tissue displacement effect instead of diffusion. This injection technique was previously studied on cadavers using CT scans.<sup>27</sup>

## CONCLUSION

The authors believe that, among the currently available filling materials, HA is an excellent option for treating cranial deformities in patients with craniosynostosis. One of the main advantages of HA fillers is the possibility of reversibility in the event of accidental intra-arterial injection. The authors stress that injections using autologous fat, calcium hydroxyapatite, polylactic acid, and acrylates are not amenable to this treatment and should be used with extreme caution in high-risk areas, such as those outlined by Beleznyay et al.<sup>28</sup> Finally, the authors highlight the importance of having a deep anatomical knowledge and managing for the eventual complications of injectors before performing these procedures.

## References

- Pelc A, Mikulewicz M. Saethre-Chotzen syndrome: case report and literature review. *Dent Med Probl.* 2018;55(2):217-25.
- Persing JA. MOC-PS(SM) CME article: management considerations in the treatment of craniosynostosis. *Plast Reconstr Surg.* 2008;121(Suppl 4):1-11.
- Warren SM et al. Parameters of care for craniosynostosis: craniofacial and neurologic surgery perspectives. *Plast Reconstr Surg.* 2012;129(3):731-7.
- Castro-Govea Y et al. Volumetric lipoinjection of the fronto-orbital and temporal complex with adipose stem cells for the aesthetic restoration of sequelae of craniosynostosis. *Arch Plast Surg.* 2018;45(2):128-34.
- Rivoalan F. [An oxycephaly deformation corrected with a fat tissue transplant]. *Ann Chir Plast Esthet.* 2012;57(6):618-21. (In French).
- Coleman SR. Long-term survival of fat transplants: controlled demonstrations. *Aesthetic Plast Surg.* 1995;19(5):421-5.
- Lazzeri D et al. Blindness following cosmetic injections of the face. *Plast Reconstr Surg.* 2012;129(4):995-1012.
- Chatrath V et al. Soft-tissue filler-associated blindness: a systematic review of case reports and case series. *Plast Reconstr Surg Glob Open.* 2019;7(4):e2173.
- Goodman GJ et al. Experience and management of intravascular injection with facial fillers: results of a multinational survey of experienced injectors. *Aesthetic Plast Surg.* 2016;40(4):549-55.
- Townshend A. Blindness after facial injection. *J Clin Aesthet Dermatol.* 2016;9(12):E5-7.
- Sykes JM. Applied anatomy of the temporal region and forehead for injectable fillers. *J Drugs Dermatol.* 2009;8(Suppl 10):s24-7.
- Loh KT et al. Prevention and management of vision loss relating to facial filler injections. *Singapore Med J.* 2016;57(8):438-43.
- Tansatit T et al. Periorbital and intraorbital studies of the terminal branches of the ophthalmic artery for periorbital and glabellar filler placements. *Aesthetic Plast Surg.* 2017;41(3):678-88.
- Bertarini F, Muszalski D. Antisépticos en procedimientos invasivos estéticos y no estéticos. 2020. Available at: <https://piel-l.org/blog/48011>. Last accessed: 20 January 2022.
- Diomedi A, et al. [Antiseptics and disinfectants: aiming at rational use. Recommendations of the advisory committee on healthcare associated infections. Sociedad Chilena de Infectología]. *Rev Chilena Infectol.* 2017;34(2):156-74. (In Spanish).
- Sundaram H et al. Blunt-tipped microcannulas for the injection of soft tissue fillers: a consensus panel assessment and recommendations. *J Drugs*

- Dermatol. 2012;11(8):s33-9.
17. van Loghem JAJ et al. Cannula versus sharp needle for placement of soft tissue fillers: an observational cadaver study. *Aesthet Surg J.* 2017;38(1):73-88.
  18. Funt D, Pavicic T. Dermal fillers in aesthetics: an overview of adverse events and treatment approaches. *Clin Cosmet Investig Dermatol.* 2013;6:295-316.
  19. Karimi K et al. Microcannula utilization for injectable facial fillers: standard of care? *American J Cosmet Surg.* 2018;35(4):189-97.
  20. Casabona G. Blood aspiration test for cosmetic fillers to prevent accidental intravascular injection in the face. *Dermatol Surg.* 2015;41(7):841-7.
  21. Cong LY et al. Topographic analysis of the supratrochlear artery and the supraorbital artery: implication for improving the safety of forehead augmentation. *Plast Reconstr Surg.* 2017;139(3):620e-7e.
  22. van Loghem J et al. Consensus on the use of hyaluronic acid fillers from the cohesive polydensified matrix range: best practice in specific facial indications. *Clin Cosmet Investig Dermatol.* 2021;14:1175-99.
  23. Almeida RT et al. Hyaluronic acid in the rejuvenation of the upper third of the face: review and update. Part 2: temporal and supraorbital regions. *Surg Cosmet Dermatology.* 2017;9(2):113-21.
  24. Woodward JA. Periocular fillers and related anatomy. *Cutis.* 2016;98(5):330-5.
  25. Coleman SR. Avoidance of arterial occlusion from injection of soft tissue fillers. *Aesthet Surg J.* 2002;22(6):555-7.
  26. Khan TT et al. An anatomical analysis of the supratrochlear artery: considerations in facial filler injections and preventing vision loss. *Aesthet Surg J.* 2016;37(2):203-8.
  27. Lamb JP et al. Abstract: three-dimensional CT validation of suprapariosteal temple Volumization with hyaluronic acid filler techniques. *Plast Reconstr Surg Glob Open.* 2018;6(9 Suppl):166.
  28. Beleznyay K et al. Avoiding and treating blindness from fillers: a review of the world literature. *Dermatol Surg.* 2015;41(10):1097-117.

FOR REPRINT QUERIES PLEASE CONTACT: [INFO@EMJREVIEWS.COM](mailto:INFO@EMJREVIEWS.COM)


# Trichotillomania with Giant Gastric Trichobezoar in a Female Child: A Case Report

## Authors:

\*Walaa Fadhil Abbas,<sup>1</sup> Tamrazova Olga Borisovna,<sup>2,3</sup> Molochkov Anton Vladimirovich,<sup>4</sup> Dzyadchik Alexander Valerievich,<sup>3</sup> Stadnikova Antonina Sergeevna<sup>3</sup>

1. Department of Dermatovenerology with Course Cosmetology, Peoples' Friendship University of Russia (RUDN), Moscow, Russia
2. Federal State Autonomous Educational Institution of Higher Education, Peoples' Friendship University of Russia (RUDN) of the Ministry of Education and Science of the Russian Federation, Moscow, Russia
3. Children's City Clinical Hospital ZA Bashlyaeva, Moscow Department of Health, Russia
4. Moscow Regional Research Clinical Institute MF Vladimirsky, Russia

\*Correspondence to walaafadil1@gmail.com



## Disclosure:

The authors have declared no conflicts of interest.

## Received:

23.12.21

## Accepted:

08.02.22

## Keywords:

Alopecia, obsessive compulsive disorders (OCD), trichobezoar, trichotillomania (TTM).

## Citation:

EMJ Dermatol. 2022; DOI/10.33590/emjdermatol/21-00275. <https://doi.org/10.33590/emjdermatol/21-00275>.

## Abstract

Trichotillomania is defined by the Diagnostics and Statistic Manual of Mental Disorders (DSM-5) as an individual repetitively pulling of their own hair, which may be an unconscious action or intentional. The disease is considered one of the anxiety disorders as it has some obsessive-compulsive features. Many patients with this disorder go to a dermatologist for the first time with a complaint of hair loss (alopecia), and many of them deny the self-pulling behaviour. In rare circumstances, this psychological problem may coexist with a complication called gastric trichobezoar, like in this unusual case presentation, which is an accumulation of the patient's hair in their stomach. It can be huge, presenting as a 'tail' extending into the duodenum and leading to what is referred to in the literature as 'Rapunzel syndrome'. Gastric trichobezoars are most often seen in teenage females. Trichophagia has only been previously confirmed in one-third of these patients, but this is usually a late presentation, occurring after much hair eating for many years.

## Key Points

1. Trichotillomania is an anxiety disorder-related behaviour where an individual repetitively pulls their own hair and can be complicated by subsequent gastric trichobezoar, particularly if the underlying trichotillomania is not recognised or addressed in a timely manner.

2. This case shares a complicated presentation with multi-specialty involvement: psychiatry, dermatology, and gastric surgery. Diagnostic delay in alopecia can be due to confirmation challenges, as many patients and their families deny any obsessive-compulsive behaviours, and this delay may have significant consequences, such as gastric obstruction following protracted trichophagia.

3. Clinicians should always consider the psychological and emotional background of any toddler or adolescent presenting with a non-specific and unexplained long-standing skin rash or skin appendage changes (hair and nails).

## INTRODUCTION

Trichotillomania (TTM) is a mental illness characterised by self-inflicted skin abnormalities. It is strongly linked to anxiety disorders. The American Psychiatric Association's (APA) Diagnostic and Statistical Manual of Mental Disorders (DSM-5) classifies it as an impulse control disorder.

DSM-5 criteria for TTM include hair loss as a result of frequent plucking out of one's hair; frequent attempts to reduce or eliminate hair pulling; the disruption results in clinically substantial distress or impairment in essential social, occupational, or other aspects of functioning; another medical problem that cannot be the source of hair tying or loss (e.g., a dermatological condition); and the symptoms of another mental disorder that do not adequately explain the hair pulling (e.g., in body dysmorphic disorder, attempts are made to correct a perceived imperfection or deficiency in appearance).<sup>1</sup>

This disease has a 1% lifetime prevalence across the board. In adulthood, females are more likely to experience this (ratio: 4:1). More children suffer from this condition than adults, but it is a gender equal disease. The average age of onset is between 10 and 13 years old.<sup>1</sup> Clinically, it appears as foci of hair loss, without signs of scarring or skin change, and does not follow a characteristic pattern. Hair of variable lengths and thickness is observed within the affected area on the scalp, on the eyebrows, and on the upper eyelashes. It must be differentiated primarily from the focal forms of alopecia areata.<sup>2</sup>

The scalp is the most common site for hair pulling, followed by the eyebrows, eyelashes, pubic area, trunk, and extremities.<sup>3</sup> Hair pull tests are almost always negative; however, if more than

five hairs are extracted, the test is considered positive. Dermoscopy features include hairs of various lengths, hairs that are irregularly coiled, short hairs with split ends, and flame hairs.<sup>4</sup> Histology shows intrafollicular fissures and haemorrhages in early phases. Granulomatous changes and/or perifollicular fibrosis may be seen in chronic stages. Other specific signs such as tricheomalacia (injured twisted follicles),<sup>2</sup> a rare but sometimes serious complication, or trichobezoar (gastric hair ball) may be reported as in this unique case. It may cause intestinal obstruction, gastric or intestinal bleeding or perforation, acute pancreatitis, and jaundice.<sup>5</sup>

## CASE REPORT

An 11-year-old female was brought to the emergency room of the Children's Clinical Hospital ZA Bashlyeva, Moscow, Russia. With a history of periodic moderate abdominal pain for a duration of 2 weeks, the complaint worsened and became severe the day before the appointment, accompanied by nausea and vomiting. They were a little anxious and afebrile. Their vital indicators were all within normal limits.

Physical examination revealed an epigastric mass and a diffusely tender abdomen, but soft. Rebound tenderness was negative. Abdominal ultrasound showed no air-fluid levels, hepatomegaly, and signs of cholecystitis; however, the stomach looked bloated and was filled with echogenic material, which caused acoustic shadowing in the back. An oesophagogastroduodenoscopy was then performed; the stomach was filled with a massive formation of intertwined hair. A stomach X-ray with contract media revealed heterogeneous dense stomach contents throughout the entire volume (Figure 1). A trichobezoar was diagnosed.

Their white blood count was 14,000 with a left shift; haemoglobin: 10 gm/dL; and serum iron: 3.2 µmol/L. Their pancreatic enzyme lipase slightly was elevated, liver enzymes were normal, and serum electrolytes revealed hyponatraemia, which were all found in the laboratory investigation. As the patient prepared for operative laparotomy, a trichobezoar weighing 2.5 lbs was successfully removed (Figure 2). The patient's postoperative recovery was uncomplicated.

On a post-operative dermatological consultation, a doctor found zones of bizarre thinning of sparse hair (diffuse alopecia) with variable lengths, mainly in the frontoparietal areas. The skin of the scalp was smooth and soft, without scaling, erythaema, or damage. There was no scarring or atrophy (Figure 3).

The hair pull test from the edges of alopecia was negative. A Woods' light exam to exclude fungal infections was also negative. Trichoscopy findings: decreased hair density, broken hairs of variable lengths, and trichoptilosis (split ends). Short vellus hairs, exclamation marks, or yellow dots were not seen. A blood test found that the patient was nutritional deficit (iron, serum ferritin, zinc, and vitamin B12) and their thyroid hormones were normal. On fungal scraping, there was no growth. A scalp biopsy was not completed. Examination of eyelashes and eyebrows revealed no damage. Other parts of the skin, nails, oral mucosa, and genitalia remain unchanged.

Their family history of alopecia was unremarkable except for their father (42-years-old), who was diagnosed with androgenic alopecia due to frontotemporal recession. Finally, the diagnosis of TTM was confirmed and a shampoo was described for thin hair treatment (DermoCapillaire [Eucerin, Birmingham, UK] or Selencin [Russia]) and thymuskin serum. Also, the patient was prescribed multivitamins with iron supplements for toddlers for their nutritional deficit (NovaFerrum [Greenville–Spartanburg–Anderson, South Carolina, USA]) Their parents were advised to prepare a healthy meal filled with essential vitamins. Then, the patient was discharged with recommendations to follow a TTM treatment programme.

After that, the patient was referred for mental evaluation and consultation. The patient was agitated and lacked co-operation, as well as weak eye contact. When they became obsessed and other family members were not watching, such as at midnight or when they were alone, the patient admitted to pulling out their hair and eating it. They denied other behaviours such as nail or lip biting and picking skin. Furthermore, no signs of these actions were detected on clinical evaluation. They were in primary school and had high grades and no social communication issues with their classmates or teachers.

Their parents were completely unaware of their hair-eating habit (trichophagia). Despite this, their mother admitted that they noticed the changes in their daughter's hair 2 years ago but did not ask for dermatological consultation because of the nature of patient's parents' work. The patient's mother said that they took their daughter to the outpatient clinic after several months, where the doctor suspected malnutrition as a susceptible cause of hair thinning as the patient was under weight and BMI was 18.49. So, the doctor sent the patient to do several blood tests, which revealed iron, zinc, and vitamin D deficiencies. The patient's mother then decided that these were the causes and that they should take care of their daughter's diet. The patient's mother did not return to the dermatology clinic to complete the consultation and diagnosis.

The psychiatrist revealed that the patient did not fully meet the diagnostic criteria for TTM as an obsessive-compulsive disorder (OCD) as defined by the DSM-5 as they did not try to reduce or eliminate hair pulling. In addition to that, their disorder did not significantly affect their social and educational life. However, the other three criteria were present in this patient, including repetitive hair pulling; no other dermatological condition can be the source of her hair loss; and no other psychological problems can better explain this disorder.

Exploring the other family members was unremarkable except for a history of 'nervous breakouts or feeling down', which sometimes required anxiolytic medications, so a family history of similar or related disorders was negative. As a result of a long history of hair pulling and hair eating, which had disastrous



Figure 1: Stomach X-ray with contract media, which revealed heterogeneous, dense stomach contents throughout the entire volume.

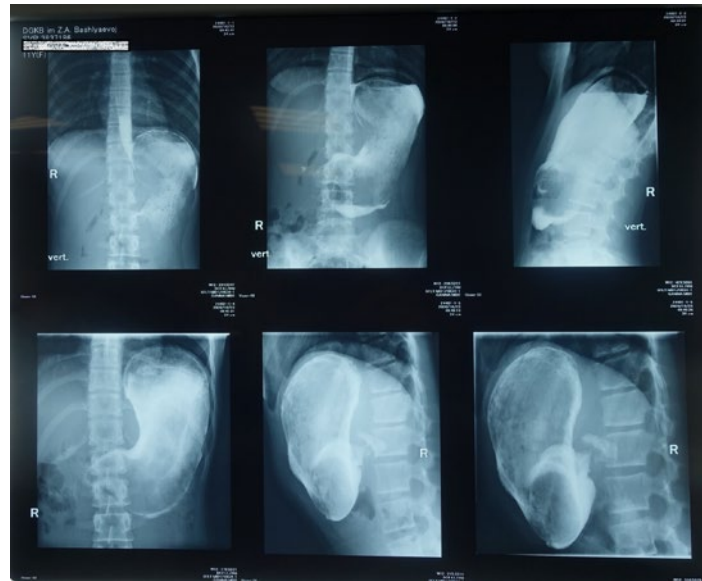

Figure 2: Massive formation of intertwined hair.

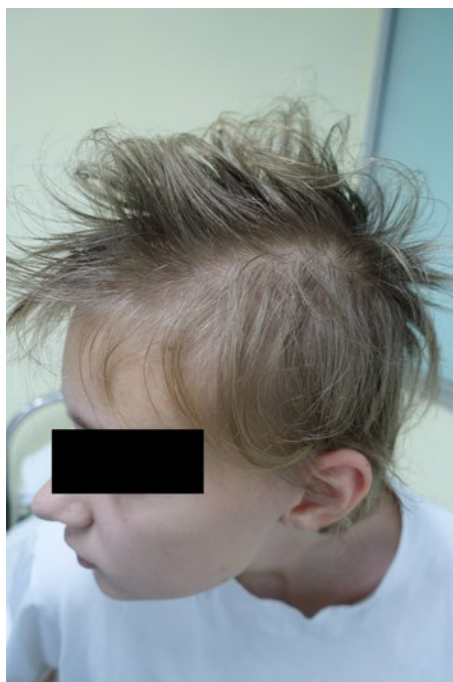

consequences, the doctor recommended selective serotonin reuptake inhibitors such as low-dose fluoxetine (Prozac [Eli Lilly and Company, Indianapolis, Indiana, USA] 10 mg/day) and N-acetylcysteine (1,200 mg/day) for 12 weeks, as well as cognitive-behavioural therapy. The patient and their parents were warned that long-term regular follow-up is crucial for successful management and to prevent recurrence.

## DISCUSSION

In 1889, a French dermatologist coined the term TTM (from the Greek tricho, meaning hair; tillo, meaning pull; and mania, which means excessive enthusiasm). Infantile or early-onset TTM usually resolves on its own or with simple interventions.<sup>6</sup> When it occurs later in life, during adulthood, or in elderly patients, it is associated with a poor prognostic outcome. Genetic abnormalities and environmental

**Figure 3: Zones of bizarre thinning of sparse hair (diffuse alopecia) with variable lengths, mainly in the frontoparietal areas.**



influences have been linked to TTM and other OCD-related disorders in twin studies.<sup>7</sup> There have been reports of structural and functional brain changes. Many neuroimaging studies have revealed abnormalities such as thickening of the right inferior frontal gyrus and decreased cerebellar volumes.<sup>8</sup> TTM is frequently associated with other pathomimic behaviours such as nail biting (onychophagia), picking skin at pimples, picking the nose, biting lips, and chewing cheeks.<sup>9</sup> Hair pulling may or may not be done with full awareness. This behaviour can also be obvious while the patient is engaged in other activities such as watching television, studying, and conversing. It is also prevalent during panic episodes and anxiety. Chronic pulling may lead to permanent hair loss and secondary bacterial infections. A trichoscopy and skin biopsy, along with a detailed and accurate history, can help to differentiate the disease from other types of alopecia such as alopecia areata, telogen effluvium, and androgenic alopecia, as well as fungal infections. A biopsy can reveal a high number of catagen and telogen hairs (due to chronic pulling), with no signs of inflammation, dystrophic fractured hair shafts, melanin and

keratin casts, plugging of dilated hair follicles, perifollicular haemorrhage, and a relatively normal dermis.

OCD is a common psychiatric health problem in which a person experiences unwanted urges and intrusive thoughts, and uses repetitive behaviours to temporarily relieve these feelings, which are unpleasant due to the anxiety caused by these uncontrollable thoughts. It can affect people of all ages and of any sex. Many patients experience symptoms as early as puberty. OCD is distressing, disrupts daily life, and can be a social stigma. On the other hand, long-term monitoring and treatment can help keep the disease under control.

A trichobezoar is a mass of hair that accumulates in the gastrointestinal tract. Baudomant described the first case in the literature in 1779, and Schonbern conducted the first surgical removal in 1883. In 'Rapunzel syndrome', the foreign material extends through the pylorus into the small intestine, which may lead to significant complications.<sup>10</sup> Gastrointestinal trichobezoars are rare, making up about 6% of all bezoars.<sup>11</sup> It is frequently seen in adolescent females with

psychiatric or intellectual disabilities, neglect, depression, anxiety, and emotional or family stress.<sup>12</sup> A gastric endoscopy can detect this uncommon consequence in less than 1% of all individuals with nonspecific abdominal symptoms. Phytobezoars (vegetables), pharmacobezoars (drugs), and trichobezoars (hair) are the three main categories of bezoars.<sup>13</sup>

The treatment is largely psychological. The dermatologist can prescribe shampoos and serums to help with hair growth and loss, as well as topical mild steroids to reduce inflammation if it is present. Also included is the correction of any nutritional deficiencies that may exist. Habit reversal training and cognitive behavioural therapy are commonly prescribed in psychiatric treatment programmes for TTM. The following are the components of habit reversal therapy: first, the patient should be taught to be aware of their actions (hair pulling). Then, the patient should force themselves to resist the urge to pull their hair and instead engage in other activities. The final component is social support from close friends and family, which encourages the patient to persevere. Selected serotonin reuptake inhibitors have been shown to be effective in recent research. More recent data showed that olanzapine and quetiapine had some beneficial effects.<sup>14</sup> Furthermore, management with N-acetylcysteine produced favourable results.<sup>14</sup>

## CONCLUSION

This intriguing and unusual case highlights a number of critical and underappreciated clinical facts. Unfortunately, the link between psychocutaneous disorders and surgical emergencies has been grossly underappreciated. An increased understanding of psychological disorders and their dermatological manifestations, particularly in children and teenagers, can aid in the early detection of TTM and trichophagia, as well as the prevention of serious life-threatening complications such as trichobezoar.

Trichobezoar should be considered as an uncommon differential diagnosis in children and teenagers, with or without a clear history of TTM and trichophagia, and regardless of family history of psychiatric disorders.

A multidisciplinary team approach involving dermatologists, psychiatrists, and general surgeons is critical for proper diagnosis and management, resulting in better patient outcomes. Furthermore, one of the most important methods for improving understanding and management of this complex entity is education of family members. Long-term follow-up is recommended as a routine part of treatment.

## References

- Grant JE, Chamberlain SR. Trichotillomania. *Am J Psychiatry*. 2016;173(9):868-74.
- Ferrando J, Ramon Grimault, "Acquired Hair Disorders," Ferrando J, Ramon Grimault (eds.), *Pediatric Hair Disorders: An Atlas and Text* (2017), London: Taylor & Francis Group, pp.99-122.
- Diaz A, Miteva M, "Trichotillomania," Miteva M et al. (eds.), *Alopecia* (2019), New York: Elsevier, pp.95-100.
- Chandran NS et al. Trichotillomania in children. *Skin Appendage Disord*. 2015;1(1):18-24.
- Hassan I et al. Psychodermatoses in children. *Indian J Paediatr Dermatol*. 2019;20(4):306-14.
- Otberg N, Shapiro J, "Cicatricial Alopecias," Kang S et al. (eds.), *Fitzpatrick's Dermatology* (2019), New York: McGraw-Hill Education, pp.1525-33.
- Monzani B et al. The structure of genetic and environmental risk factors for dimensional representations of DSM-5 obsessive-compulsive spectrum disorders. *JAMA Psychiatry*. 2014;71(2):182-9.
- Slikboer R et al. Systematic review of published primary studies of neuropsychology and neuroimaging in trichotillomania. *J Int Neuropsychol Soc*. 2018;24(2):188-205.
- Tamrazova OB, Gureeva MA. Pathomimia in children. *Vestnik dermatologii i venerologii*. 2017;93(3):76-84.
- Naik S et al. Rapunzel syndrome reviewed and redefined. *Dig Surg*. 2007;24(3):157-61.
- Kwok AMF. Trichobezoar as a cause of pediatric acute small bowel obstruction. *Clin Case Rep*. 2019;8(1):166-70.
- Caiazzo P et al. The Rapunzel syndrome. Report of a case. *G Chir*. 2016;37(2):90-4.
- Kazanowski M et al. The giant in the stomach - trichobezoar. *Prz Gastroenterol*. 2013;8(5):330-2.
- Kellner M. Drug treatment of obsessive-compulsive disorder. *Dialogues Clin Neurosci*. 2010;12(2):187-97.


# Case Report of Epstein–Barr Virus-Induced Autoimmune Vitiligo in Nigeria

## Authors:

Michael Akolawole,<sup>1,2</sup> \*Oluwasola Ayosanmi,<sup>1,3</sup> Olanrewaju Adeniran,<sup>1</sup> Ifeanyi Chukwu Onuoha,<sup>4</sup> Osaho Omoregie,<sup>5</sup> Esosa Omoregie<sup>6</sup>

1. Supreme Dermatology and Specialist Hospital, Abuja, Nigeria
2. The Limi Hospital, Abuja, Nigeria
3. College of Pharmacy and Nutrition, University of Saskatchewan, Saskatoon, Canada
4. University of Cincinnati Medical Center, Ohio, USA
5. NHS Education Scotland, UK
6. Health Education England, NHS England, UK

\*Correspondence to [osa355@usask.ca](mailto:osa355@usask.ca)



## Disclosure:

The authors have declared no conflicts of interest.

## Received:

24.12.21

## Accepted:

15.02.22

## Keywords:

Epstein–Barr virus, depigmentation, hypopigmentation, vitiligo.

## Citation:

EMJ Dermatol. 2022; DOI/10.33590/emjdermatol/21-00274.  
<https://doi.org/10.33590/emjdermatol/21-00274>.

## Abstract

Vitiligo is an acquired skin depigmenting disorder resulting from melanocytes loss in the epidermis, associated with an autoimmune aetiopathophysiology. However, there are limited data about the association between vitiligo and Epstein–Barr virus (EBV). Hence, the authors present a case of a 43-year-old male who had progressive symmetrical hypopigmented macules, sometimes coalescing to patches that were generalised but predominantly on the face and torso, with scanty involvement of proximal and distal extremities of the body. The diagnosis of vitiligo was made clinically, and seborrhoeic dermatitis was considered as a differential. Since the patient had been offered treatment for seborrhoeic dermatitis using antifungal with no relief and extensive depigmentation, the authors' working diagnosis was vitiligo and was confirmed with histology. To establish the likely cause of the condition, viral serology for HIV, Cytomegalovirus, herpes, and EBV were completed, but only EBV serology was abnormal. Therefore, the authors report this case to encourage clinicians to consider EBV infection in the aetiology and predisposition for vitiligo to help explore other pathology that the virus may cause.

## Key Points

1. Vitiligo is a progressive, acquired depigmenting disorder that presents through circumscribed white macules, papules, and depigmented patches in the skin. It can have significant psychological impact on affected patients.

2. Aetiopathogenesis of vitiligo is multifactorial, including autoimmune disorders, which have been linked to some viral infections.

3. This case of a 43-year-old male diagnosed with vitiligo clinically and on histopathology was associated with Epstein–Barr viral infection, and 3-month treatment addressed both the vitiligo (psoralen and ultraviolet A, melatonin, and topical steroids) and the EBV infection (valaciclovir, spironolactone, and ivermectin).

## CASE REPORT

A 43-year-old male from Nigeria had progressively symmetrical hypopigmented macules, sometimes coalescing to patches, which were prominent in the face, forehead, trunk, and back. On physical examination, the lesion was generalised, but the facial manifestation was of the utmost concern to the patient. There were lesions in the torso with scanty involvement of proximal and distal extremities of the body (Figure 1).

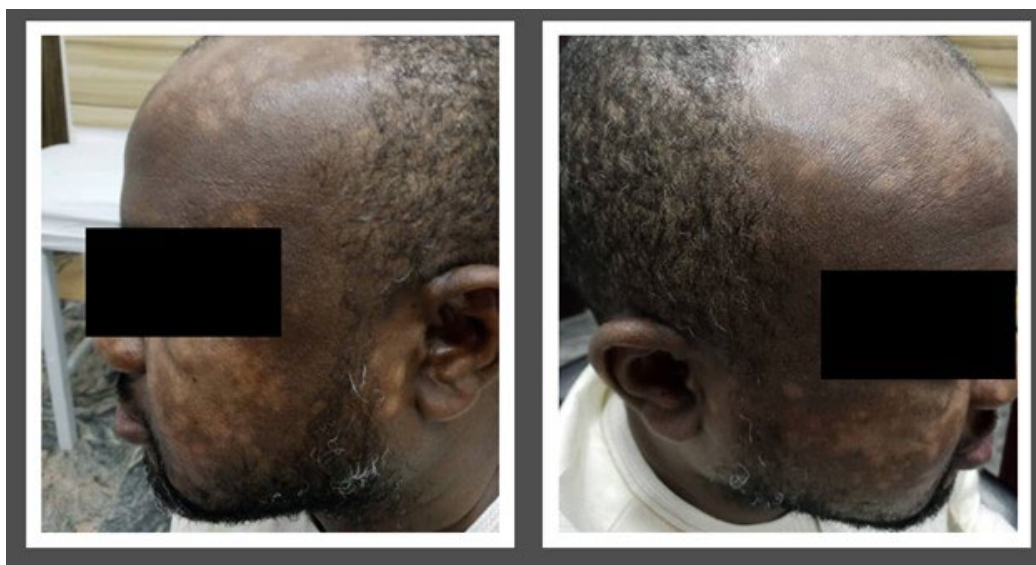### Investigation

The diagnosis of vitiligo was first made clinically based on history and physical examination. However, the authors considered seborrhoeic dermatitis as a differential diagnosis as a result of the extensive facial and forehead lesions.

On further review of the prior unsuccessful treatments received by the patient, the authors observed that seborrhoeic dermatitis was initially treated unsuccessfully. Another differential is eruptive hypomelanosis, an exanthem suspected to be related to viral infections. However, eruptive hypomelanosis is commonly found in young children aged 2–10 years, with an associated flu-like symptom. The authors' case was completely different from eruptive hypomelanosis.

Clinically, the extensive depigmentation and hypopigmentation in the face and trunk strongly suggested a diagnosis of vitiligo. Thus, a skin biopsy was completed to establish the diagnosis and for histological diagnosis of vitiligo. The histology report revealed a total absence of functioning melanocytes in the lesions

Figure 1: Facial manifestation of vitiligo with multiple hypopigmentations.



(Figure 2). There was depigmentation juxtaposed with hypopigmentation, suggestive of an ongoing destructive process. Some melanin dissoluteness at the superficial dermis was engulfed by macrophages. There was associated mononuclear, perivascular, and inflammatory cell infiltrate. The epidermal architecture was not significantly altered.

To establish the likely cause of the condition, viral serology for *Cytomegalovirus* IgM and IgG, herpes simplex virus IgG, antinuclear antibodies, and Epstein–Barr virus (EBV) were completed, but only the EBV serology was abnormal (Table 1).

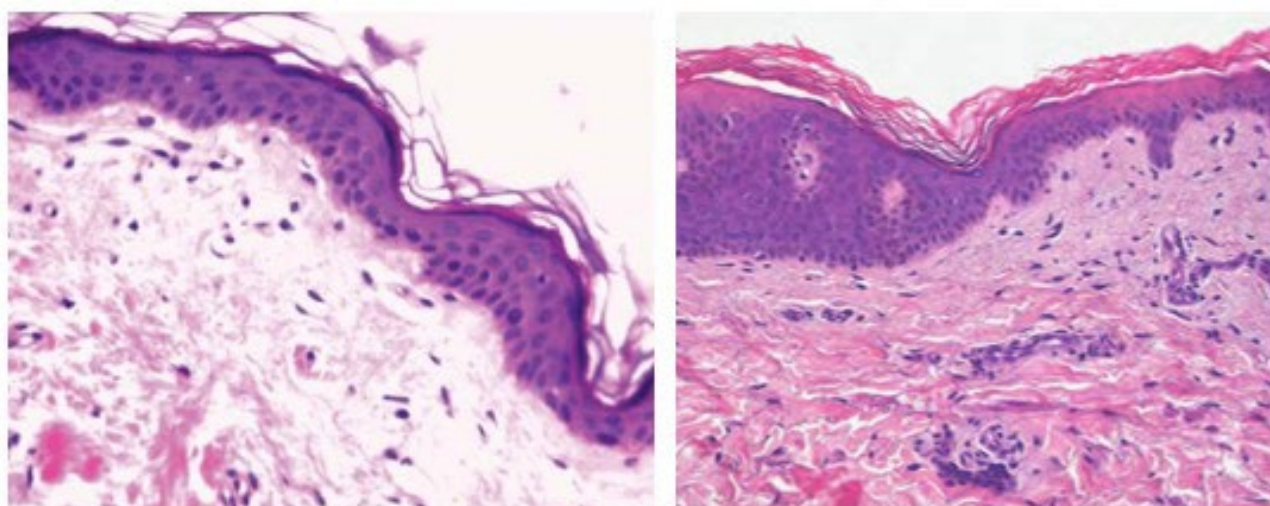
The patient was treated with psoralen and ultraviolet A, melatonin, and topical steroids. In addition, to treat the EBV infection, they were placed on valaciclovir, spironolactone, and ivermectin, based on evidence supporting their efficacies.<sup>1–3</sup> The patient progressively recovered within 3 months of treatment. Another serology test after 3 months of treatment revealed a reduction of the EBV values from 1.43 to 1.08. However, a complete viral clearance is expected to take a longer time.

## DISCUSSION

Vitiligo is an acquired depigmenting disorder that is progressive and has multifactorial aetiopathogenesis. It usually presents with the appearance of circumscribed white macules, papules, and depigmented patches in the skin.<sup>4</sup> Empirical evidence shows that vitiligo significantly impacts patients' emotions and psychology to varying degrees.<sup>5</sup> While coping may be easier for those who have the disorder in the non-exposed part of their skin, the psychological trauma may be profound in exposed areas such as their face, as seen in the authors' patient. For the authors' patient, the presence of this lesion in their face led to low self-esteem, emotional destabilisation, social anxiety, and avoidance of public places. They also claimed to have spent much money on treatment with no significant changes. Hence, a desire to establish the cause and permanent solution motivated his presentation.

A close differential to the facial presentation of vitiligo is seborrhoeic dermatitis, a chronic inflammatory skin disease impacting the regions of the body rich in sebaceous glands. It is

**Figure 2: Histopathological features of vitiligo-like hypopigmentation, showing irregular epidermal hyperplasia.**



A) Scanty perivascular inflammatory infiltrates were detectable in the superficial dermis. The reduction of melanocytes was confirmed by S100 staining (haematoxylin and eosin: x20).

B) The total absence of melanin in the basal layer of the epidermis and the absence of melanocytes is compatible with vitiligo (haematoxylin and eosin: x400).

Table 1: Serology test of the patient's specimen showing Epstein–Barr virus abnormality.

Test	Result	Unit	Reference range	Normal or abnormal
CMV IgM	0.40	Index value	0–0.89	Normal
CMV IgG	0.30	Index value	0–0.89	Normal
EBV quantitation	1.43	Index value	0–0.89	Abnormal
HSV1 IgG	0.50	Index value	0–0.89	Normal
ANA	0.09	Index value	Adult: 0–0.89	Normal

ANA: antinuclear antibodies; CMV: Cytomegalovirus; EBV: Epstein–Barr virus; HSV1: herpes simplex virus 1.

common in the scalp, face, and upper trunk. In adults, seborrhoeic dermatitis results in a chronic remitting and relapsing disease.<sup>6</sup> Based on the closeness of this differential, the authors' patient received initial treatment for seborrhoeic dermatitis in another facility before presenting at their dermatology clinic. However, the treatment for seborrhoeic dermatitis was unsuccessful, as the patient noticed an extensive increase in the lesions. While the authors cannot establish a possibility of the wrong diagnosis by the initial clinical assessor, they considered a diagnosis of vitiligo with a possibility of the Koebner phenomenon as the explanation for the extensive facial manifestation. Mufutau et al.<sup>7</sup> earlier noted that the Koebner phenomenon, induced by seborrhoeic dermatitis, may be a perpetrating factor in vitiligo, with an attendant challenge in the treatment of the patients.

Therefore, the authors deemed it necessary to go beyond clinical judgment in diagnosing this case. The histology result confirmed their suspicion, yet the authors explored the possible association of a viral infection with vitiligo. A finding of the EBV in the serology assay prompted a need to report this case as a lesson for clinicians, especially in resource-poor countries. Thus, this report could guide the clinicians on some of the management approaches to vitiligo.

Vitiligo is more common in Africa relative to other parts of the world. Globally, a prevalence rate ranging between 0.2–2% has been reported.<sup>9</sup> However, a meta-analysis reported a higher rate

in Africa and predominance among females.<sup>9</sup> In Nigeria, the prevalence ranged from 0.96 in Northwest Nigeria to 5% in the South.<sup>10,11</sup> Another Nigerian study reported the facial presentation of vitiligo as the most prevalent among Nigerians.<sup>11</sup>

The aetiopathogenesis of vitiligo is multifactorial. Several studies have established a strong correlation between autoimmune disorders and the development of vitiligo.<sup>4,8–13</sup> As a result of the established association between viral infections and many autoimmune disorders, recent attention has been drawn to investigating the viral cause of vitiligo. For example, Grimes et al.<sup>14</sup> reported *Cytomegalovirus* positivity in patients with vitiligo.

Primary infection with EBV is mostly asymptomatic until the individual reaches adolescence or adulthood, where it can manifest as infectious mononucleosis.<sup>3</sup> EBV is linked to various malignancies, including Burkitt lymphoma, nasopharyngeal carcinoma, Hodgkin lymphoma, and lymphoproliferative disease, irrespective of the individual's immune status.<sup>8</sup> The virus usually becomes latent in memory B cells. The EBV genome replicates when B cells divide using the host DNA polymerase, leading to reactivation. Therefore, valaciclovir has been shown to block the viral replication and decrease the latent EBV load at a rate equivalent to the half-life of memory B cells.<sup>3</sup>

To the best of the authors' knowledge, their report would be the first to report a positive EBV serology in a subject from Nigeria, with

a histologically confirmed clinical diagnosis of vitiligo. The finding of EBV in this patient suggests a need to pay more attention to the viral association of vitiligo in immunocompetent individuals.

Vitiligo is a recurring depigmenting condition with a possibility of the development of the Koebner phenomenon in up to one-third of the patients.<sup>7</sup> Koebner phenomenon, which is the presence of new skin lesions at a distant site, has been reported to worsen treatment and prevent recovery in patients. Infections are identified as one of the causes of Koebner phenomenon.<sup>15</sup> Hence, identifying EBV in this patient may explain the possibility of this phenomenon.

Although the authors' patient was initially treated for seborrhoeic dermatitis with no improvement, an index of suspicion to establish the diagnosis of vitiligo and possible associated risk factors provide an opportunity for proper treatment of the condition. While the authors may not be able to establish a causal relationship between EBV and vitiligo, due to the chronic nature of

the disease, they did show an association. Although their patient denied any prior diagnosis of infectious mononucleosis, Burkitt lymphoma, and other related malignancies, establishing the presence of EBV and providing treatment may proactively prevent a future manifestation of any of the EBV-related disorders. However, regular monitoring of the clearance of the EBV viral load in his system for one year is necessary.

A limitation of the authors' report is that they only reported EBV based on the serology assay. They could not complete PCR testing and viral quantification testing due to the paucity of funds. One major limitation in their practice setting is that the serology testing for these viruses is not readily available, and the cost is not covered by insurance. Hence, patients would need to pay out of pocket. With more reports like this one, the authors anticipate increasing awareness, supporting the advocacy for serological and PCR testing for some viral aetiology of certain autoimmune conditions.


## References

- Xu L et al. A new therapy in Epstein-Barr virus-associated lymphoproliferative disease: a case report and a revision of the literature. *Italian J Ped.* 2019;45(1):135.
- Verma D et al. Spironolactone blocks Epstein-Barr virus production by inhibiting EBV SM protein function. *Proc Nat Acad Sci* 2016;113(13):3609-14.
- Hoshino Y et al. Long-term administration of valacyclovir reduces the number of Epstein-Barr virus (EBV)-infected B cells but not the number of EBV DNA copies per B cell in healthy volunteers. *J Virol.* 2009;83(22):11857-61.
- Guerra L et al. Vitiligo: pathogenetic hypotheses and targets for current therapies. *Curr Drug Met.* 2010;11(5):451-67.
- Kent G, Al'Abadie M. Psychologic effects of vitiligo: a critical incident analysis. *J Am Acad Derm.* 1996;35(6):895-8.
- Borda LJ, Wikramanayake TC. Seborrheic dermatitis and dandruff: a comprehensive review. *J Clin Invest Derm.* 2015;DOI:10.13188/2373-1044.1000019.
- Oripelaye M et al. Seborrheic dermatitis induced Koebnerization: a probable outcome determinant in vitiligo. *Intern Med.* 2017;7(242):2.
- Krüger C, Schallreuter KU. A review of the worldwide prevalence of vitiligo in children/adolescents and adults. *Int J Dermatol.* 2012;51(10):1206-12.
- Zhang Y et al. The prevalence of vitiligo: a meta-analysis. *PLoS ONE.* 2016;11(9):e0163806.
- Onayemi O et al. Prevalence of different skin conditions in an outpatients' setting in north-western Nigeria. *Int J Derm.* 2005;44(1):7-11.
- Ayanlowo O et al. Characteristics of vitiligo in Lagos, Nigeria. *West Afr J Med.* 2009;28(2):118-21.
- Altraide DD et al. Vitiligo: a hospital-based study in Southern Nigeria. *PH Med J.* 2009;4(2).
- Nnoruka E. Skin diseases in south-east Nigeria: a current perspective. *Int J Dermatol.* 2005;44(1):29-33.
- Grimes PE et al. Cytomegalovirus DNA identified in skin biopsy specimens of patients with vitiligo. *J Am Acad Derm.* 1996;35(1):21-6.
- Sanchez DP, Sonthalia S. Koebner Phenomenon (2021) [Internet]. Treasure Island, Florida: StatPearls Publishing. 2021. Available from: <https://www.ncbi.nlm.nih.gov/books/NBK553108/>.

FOR REPRINT QUERIES PLEASE CONTACT: [INFO@EMJREVIEWS.COM](mailto:INFO@EMJREVIEWS.COM)



# Severe Sunburn-Like Adverse Cutaneous Drug Reaction in a Patient on Treatment with Rifaximin: A Rare Case of Acute Phototoxic Drug Reaction



<b>Authors:</b>	*Vikram K. Mahajan, <sup>1</sup> Suman Singh, <sup>2</sup> Priyanka Thakur, <sup>1</sup> Amisha Kukreja, <sup>1</sup> Rohit Negi <sup>1</sup>
	1. Department of Dermatology, Venereology and Leprosy, Dr. Rajendra Prasad Government Medical College, Kangra (Tanda), India 2. Department of Pathology, Dr. Rajendra Prasad Government Medical College, Kangra (Tanda), India *Correspondence to vkm1@rediffmail.com
<b>Disclosure:</b>	The authors have declared no conflicts of interest.
<b>Acknowledgements:</b>	The authors would like to sincerely thank the patient for their consent.
<b>Received:</b>	23.10.21
<b>Accepted:</b>	14.01.22
<b>Keywords:</b>	Adverse cutaneous drug reaction, photosensitivity, rifaximin, sunburn.
<b>Citation:</b>	EMJ Dermatol. 2022; DOI/10.33590/emjdermatol/21-00233. <a href="https://doi.org/10.33590/emjdermatol/21-00233">https://doi.org/10.33590/emjdermatol/21-00233</a> .

## Abstract

This paper describes an unreported case of a rifaximin-induced phototoxic reaction in an otherwise healthy 24-year-old female (skin type: V). The patient developed malaise, chills, and facial swelling with accompanying redness and itching that began within a day of initiating treatment with rifaximin (200 mg twice daily), and progressively increased over the next 3–4 days. The patient revealed that they had been lying in the sun for hours due to the chills they were experiencing. Over the next 10 days they developed an exaggerated, acute, sunburn-like phototoxic reaction, with blistering over the exposed skin. A skin biopsy showed no evidence of vasculopathy, endothelial damage, or extravasation of red blood cells. The patient was treated successfully with oral prednisolone (30 mg per day for a week), topical mometasone furoate (0.1%) cream applied twice daily, levocetirizine (5 mg per day taken orally), zinc oxide (20.0%) cream applied every 3 hours during daytime, and strict sun avoidance. The possible pathomechanism of rifaximin-induced sunburn is also discussed here.

## Key Points

1. This case describes a 24-year-old female who developed a rifaximin-induced phototoxic reaction, with symptoms including malaise, chills, and progressive facial swelling with redness and itching, followed by an exaggerated, acute, sunburn-like phototoxic reaction after sun exposure.
2. Treatment with oral prednisolone, topical mometasone furoate cream, levocetirizine, zinc oxide, and strict sun avoidance was successful in improving the phototoxic reaction.
3. While the pathomechanism of rifaximin-induced acute sunburn is not yet understood, dermatologists must remain vigilant as rifaximin is increasingly prescribed.

## INTRODUCTION

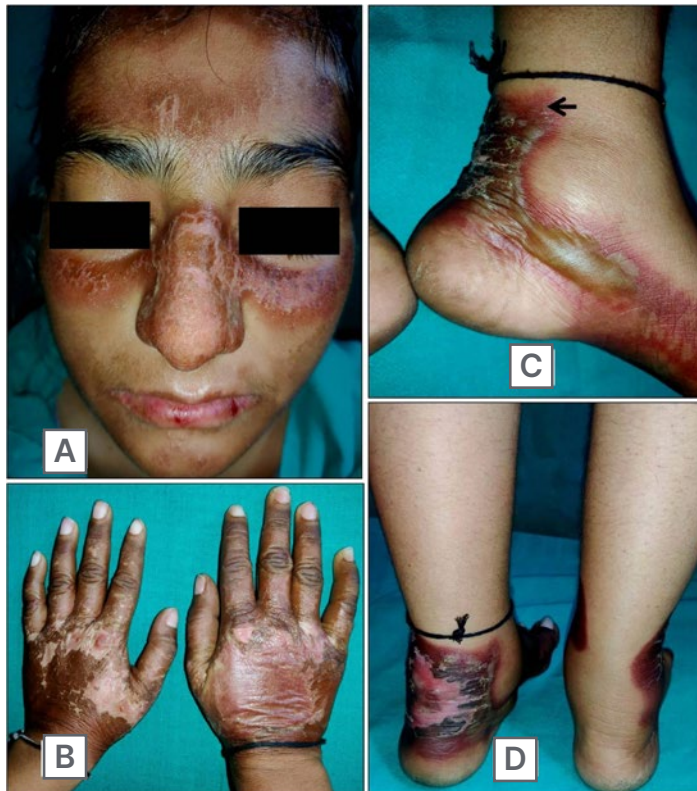Drug-induced photosensitivity is an adverse cutaneous reaction caused by a simultaneous exposure to potentially photosensitising drugs (via topical application or parenteral administration) and ultraviolet (UV) radiation or visible light. Clinically, drug-induced photosensitivity manifests as either a photoallergic drug reaction or a phototoxic drug reaction.<sup>1,2</sup> In a photoallergic drug reaction, the photosensitising drug in the skin absorbs light photons to form a photoproduct, which binds to a soluble or membrane-bound protein to form an antigen. This reaction is immune-mediated and develops in only a small number of exposed individuals, depending on the presence of immunologic reactivity from previous sensitisation. The phototoxic drug reaction is non-immune-mediated and occurs in all individuals. Clinically, it is essentially an exaggerated sunburn response characterised by sharply demarcated painful erythema, oedema, and blistering over the exposed skin. The potentially photosensitising systemic drugs include: tetracyclines, sulfonamides, fluoroquinolones, thiazides, sulfonylurea antidiabetics, non-steroidal anti-inflammatory drugs, psoralens, pirofenidone, efavirenz, and taxanes.<sup>2-6</sup> The chemicals used in topical antiseptic agents, fragrances, tanning lotions, sunscreens, and various cosmetics are other common causes of photosensitivity.<sup>7</sup> This paper reports a rare case of an acute phototoxic drug reaction from rifaximin and discusses the possible pathomechanism involved.

## CASE REPORT

A 24-year-old female was hospitalised with multiple erythematous acrofacial photodermatitis, which was causing pain and a burning sensation. Historically, they had previously developed gastroenteritis and were treated with rabeprazole (20 mg per day), levosulpiride (75 mg per day), and rifaximin (200 mg twice daily). As their nausea improved, they stopped taking rabeprazole plus levosulpiride after their second dose, and continued rifaximin in the prescribed doses. The patient developed malaise, fever (not documented), chills, and facial swelling, with accompanying redness and itching that began within a day of initiating the treatment and was progressively increasing over the next 3–4 days. The patient also revealed that they had been lying in the sun for hours due to the chills they were experiencing.

Over the next 10–12 days, the facial rash increased, and similar lesions associated with pain and intense burning had also appeared over the dorsum of their hands and feet. The patient related that the onset of their abdominal symptoms was incidental. Their personal and family histories were unremarkable, they were not taking any medication, and they had no previous history suggestive of any drug sensitivity, lupus, or other photosensitive disorder. A cutaneous examination ([Figure 1](#)) showed mild oedema and intense diffuse erythema, marked by well-demarcated darkening, cracking, and peeling, which varied in intensity and was limited to the directly sun-exposed skin over the forehead, malar area, lower lip, chin, presternal skin, the dorsa of hands, around ankles, and the borders of the feet and adjoining soles, with blistering in places. The mucosae were normal, except for the

Figure 1: Photographs of the patient's acute sunburns, characterised by diffuse erythema.

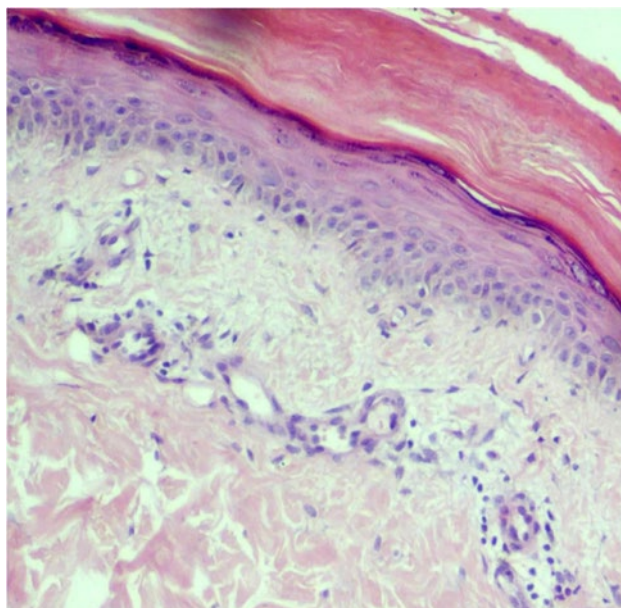


*This is marked by the darkening, cracking, and desquamation of the skin in variable intensity, involving the sun-exposed sites: **A**) the forehead, malar area, lower lip, and chin; **B**) the dorsa of the hands; **C**) the borders of feet and adjoining sole; and **D**) around the ankles. Similar lesions were present over the toes and presternal skin. Note the sharp demarcation of all of these lesions. The blistering around the ankle in **C**) suggests early severe acute phase, and the arrow in this image indicates the site of biopsy.*

lower lip, which displayed erythema, fissuring, and a small amount of crusting. The hair, nails, palms, and other systemic examinations were normal. Due to the possibility of a rifaximin-induced acute phototoxic reaction, all of the previous treatments were stopped. The haemogram, hepatorenal and thyroid function tests, antinuclear antibody titres, 24-hour urinary proteins, chest X-ray, and urinalysis showed no abnormality. Histology from the erythematous skin lesion over the ankle showed hyperkeratosis, mild spongiosis, and a perivascular inflammatory cell infiltrate composed of lymphocytes and occasional neutrophils in the upper dermis (Figure 2). There was no evidence of vasculopathy, endothelial damage, or extravasation of red blood cells. Direct immunofluorescence was not performed because of financial constraints.

The patient was treated with oral prednisolone (30 mg per day for a week), topical mometasone furoate (0.1%) cream applied twice daily, levocetirizine (5 mg per day taken orally), zinc oxide (20.0%) cream every 3 hours during daytime, and strict sun avoidance. A review carried out 4 weeks after hospital discharge showed that all lesions had resolved with hypopigmentation. The patient was advised to avoid sun exposure and to topically apply physical sunscreen (sun protection factor: 19) containing 7.5% micronised zinc oxide (Sunstop-19™ [Ajanta Pharma Ltd, Mumbai, India]) every 4 hours on all days. At a recent visit, approximately 6–7 months after their last review, the patient revealed that they did not continue treatment beyond one month or so. The patient showed no residual dyspigmentation or recurrence of photosensitivity, and they did not consent for phototesting or photopatch testing.

**Figure 2: A light microscope image of the erythematous skin lesion over the ankle of the patient using a haematoxylin and eosin stain (x40).**



*Histology showed hyperkeratosis, mild spongiosis, and a perivascular inflammatory cell infiltrate in the upper dermis composed of predominantly lymphocytes and occasional neutrophils. The absence of vasculopathy, endothelial damage or swelling, and the extravasation of red blood cells is notable.*

## DISCUSSION

Rifaximin is a semisynthetic, structural analogue of rifamycin and a non-systemic, site-specific gastrointestinal antibiotic. It reduces bacterial virulence and translocation, has anti-inflammatory properties, positively modulates the gut microbial flora, and induces eubiotic changes in the intestinal ecosystem. Rifaximin is effective for the treatment of travellers' diarrhoea, caused by *Escherichia coli*, and other gastrointestinal infective conditions, such as *Clostridium difficile* colitis. Additionally, it is useful for treating diarrhoea-predominant irritable bowel syndrome and reduces the risk of overt hepatic encephalopathy recurrence. Rifaximin is poorly absorbed after oral administration, does not significantly pass the gastrointestinal wall, and undergoes metabolism with >90.00% excretion in the faeces, negligible excretion of unchanged drug in urine, and <0.01% distribution in other tissues.<sup>8-10</sup>

Hypersensitivity reactions, such as anaphylaxis, angioedema, urticaria, pruritus, flushing, fatigue,

fever, chills, malaise, headache, gastrointestinal upset (abdominal pain, constipation), and respiratory tract infection, were common mild adverse effects in <2% of patients taking rifaximin in clinical trials and post-marketing reports.<sup>9</sup> While pruritus, rash, and cellulitis were common dermatological adverse effects in 1–10% of cases, sunburn was rare, occurring in only 0.1–1.0% of cases.<sup>9</sup> Although the authors could not perform a drug rechallenge, rifaximin could definitely be the cause of the patient's pruritus, and facial erythema and swelling, and could be associated with malaise, chills, facial oedema, and the rash that had developed within a day. However, the authors suggest that more progressive severe acute sunburn occurred as a result of undue sun exposure (temporal correlation). This seems most plausible as, clinically, the phototoxic drug reaction usually starts within few hours and reaches a peak between several hours to a few days after exposure, eventually forming hard, blackish, rough, brittle, cracked, and desquamating plaques, as was noted in this case.<sup>1</sup> Once treated, resolution occurred without recurrences after drug discontinuation (dechallenge), as per the

World Health Organization-Uppsala Monitoring Centre (WHO-UMC) causality assessment system scale.

The possibility of subacute cutaneous lupus erythematosus (SCLE) arising because of rabeprazole plus levosulpiride, which is known to aggravate pre-existing lupus or trigger new onset SCLE, could be excluded due to the fact that only two doses of the drug were ingested by the patient and there was no clinical or laboratory evidence of pre-existing lupus erythematosus. Moreover, it usually takes weeks to many months for drug induced-SCLE to develop after the initiation of the offending medication.<sup>11,12</sup>

The pathomechanism of rifaximin-induced sunburn is poorly understood due to the paucity of cases. In general, UVB rays (290–320 nm) can induce photosensitisation more efficiently than UVA rays (340–400 nm) in the absence of an exogenous photosensitiser. However, acute phototoxicity injury has been reported with exposure to UVA rays, even in sub-erythematous amounts.<sup>1</sup> Although UVA rays are more melanogenic than erythrogenic to produce acute erythema, the action spectrum for exogenous photosensitisers usually includes UVA rays that penetrate further than UVB, but less than visible light. However, the severity of photosensitivity is also dictated by factors such as gastrointestinal absorption, distribution and metabolism of the offending drug, skin colour, stratum corneum thickness in the host, and the amount of UV radiation and/or sun exposure.<sup>1</sup> Although rifaximin is primarily a site-specific gastrointestinal antibiotic, in pharmacokinetic studies, 18% of the radioactivity in plasma reflects systemic absorption and the potential for its accumulation, which can cause adverse effects in skin.<sup>9</sup>

The interaction of the photosensitising molecule, the non-ionising radiation, and the affected skin occurs either from oxygen-dependent or photodynamic reactions, as in porphyrin phototoxicity, or oxygen independent or non-photodynamic reactions, as in psoralen phototoxicity. Photo-induced cellular damage results from phototoxicity to either cellular DNA or RNA, as with psoralens, or mitochondria, as with tetracycline.<sup>1</sup> As the systemic photosensitising molecules reach the skin via the vasculature, the inflammatory changes remain limited to the dermis without keratinocyte apoptosis, whereas the dermal blood vessels are damaged in porphyrin-induced acute phototoxic reactions. However, any association of rifaximin-induced sunburn with the metabolism of porphyrins seems unlikely, which appears plausible in the absence of any significant epidermal or vascular changes noted at microscopic level, but dermal perivascular inflammation in this case corroborates the former. Overall, the exact pathomechanism of rifaximin-induced acute sunburn remains conjectural and open to debate. Nevertheless, dermatologists must remain vigilant of this rare cause of severe phototoxicity, as additional cases may be seen in the future with the increasing prescription of rifaximin.

## LIMITATIONS

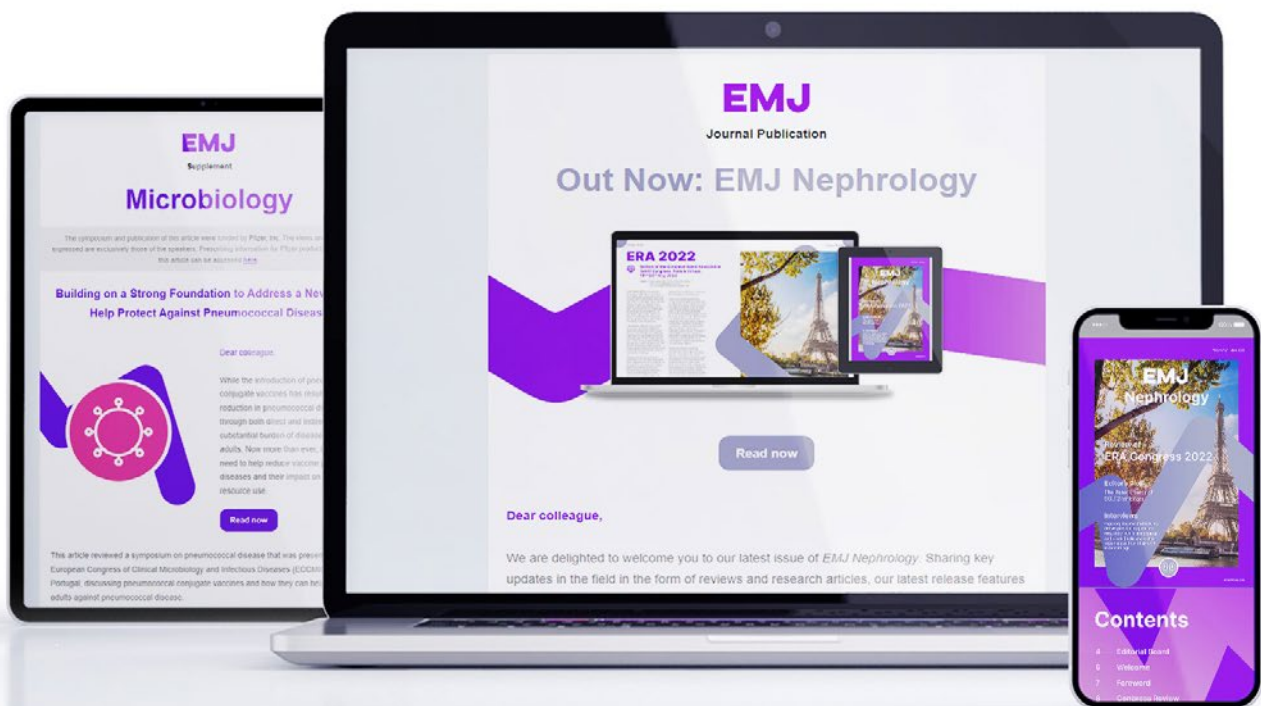The cause of gastroenteritis in this patient could not be ascertained. However, drug rechallenge, phototesting and photopatch testing, direct immunofluorescence, and immunological tests for extractable nuclear antigens or rheumatoid factor were not performed because of a lack of consent and financial constraints.

## References

- Epstein JH. Phototoxicity and photoallergy. *Semin Cutan Med Surg.* 1999;18(4):274-84.
- Lankerani L, Baron ED. Photosensitivity to exogenous agents. *J Cutan Med Surg.* 2004;8(6):424-31.
- Mahajan VK, Sharma NL. Photo-onycholysis due to sparfloxacin. *Australas J Dermatol.* 2005;46(2):104-5.
- Droitcourt C et al. Pirfenidone photosensitization in patients with idiopathic pulmonary fibrosis: a case series. *Br J Dermatol.* 2017;178(3): e222-3.
- Mahajan VK et al. Photodermatitis in a woman on antiretroviral therapy: report of a rare cutaneous adverse drug reaction of efavirenz and review of literature. *Int J Dermatol.* 2017;56(10):e200-2.
- Mahajan VK et al. Photodermatitis in a woman with infiltrating intraductal breast carcinoma: an uncommon adverse cutaneous drug reaction of paclitaxel revisited. *Indian J Pharmacol.* 2020;52(5):430-4.
- Jindal N et al. Evaluation of photopatch test allergens for Indian patients of photodermatitis: preliminary results. *Indian J Dermatol Venereol Leprol.* 2011;77(2):148-55.
- Ponziani FR et al. Eubiotic properties of rifaximin: disruption

- of the traditional concepts in gut microbiota modulation. *World J Gastroenterol.* 2017;23(25):4491-9.
9. Salix Pharmaceuticals, Inc. XIFAXAN® (rifaximin) highlights of prescribing information: FDA package insert. 2014. Available at: [https://www.accessdata.fda.gov/drugsatfda\\_docs/label/2014/021361s013lbl.pdf](https://www.accessdata.fda.gov/drugsatfda_docs/label/2014/021361s013lbl.pdf). Last accessed: 18 January 2022.
  10. Pimentel M. Review of rifaximin as treatment for SIBO and IBS. *Expert Opin Investig Drugs.* 2009;18(3):349-58.
  11. Keyes E et al. Drug-induced subacute cutaneous lupus erythematosus in previously diagnosed systemic lupus erythematosus patients: a case series. *JAAD Case Reports.* 2021;12:18-21.
  12. Patel NB et al. Proton pump inhibitor-induced subacute cutaneous lupus erythematosus. *J Allergy Clin Immunol Pract.* 2020;8(1):326-7.

FOR REPRINT QUERIES PLEASE CONTACT: [INFO@EMJREVIEWS.COM](mailto:INFO@EMJREVIEWS.COM)



# Receive our free newsletters and alerts

Get the latest updates on all our upcoming journals and receive first-class insights into ground-breaking news and advancements in medicine across multiple therapeutic areas.

[Join our mailing list](#)

[www.emjreviews.com](http://www.emjreviews.com)

**EMJ**