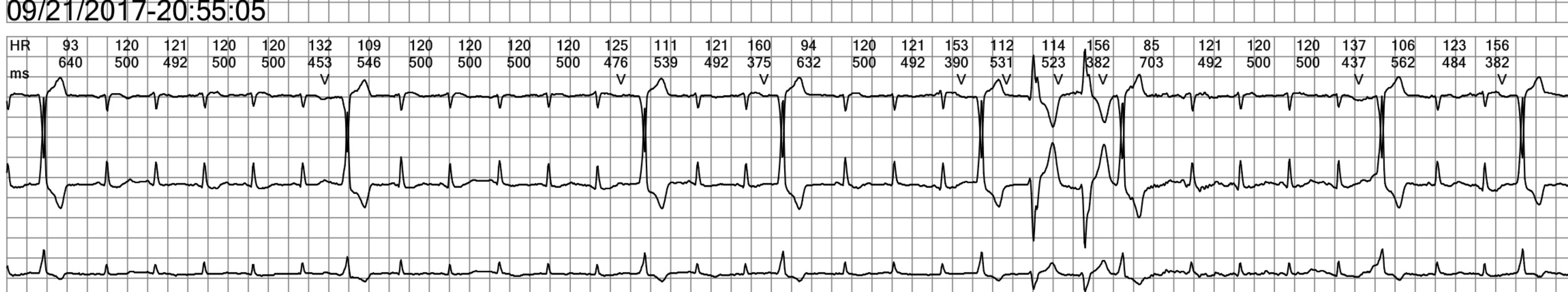
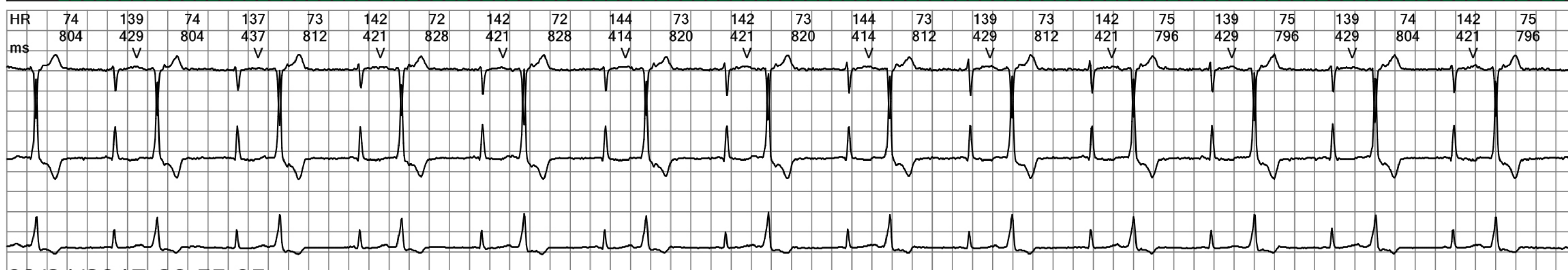
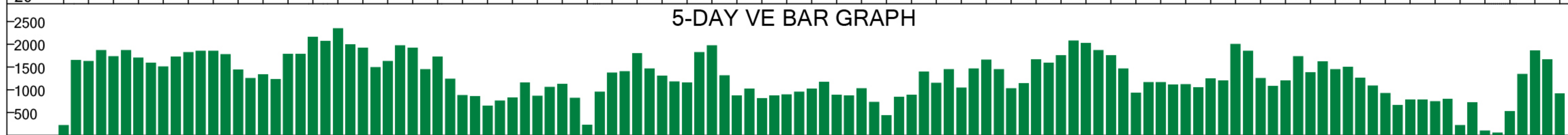
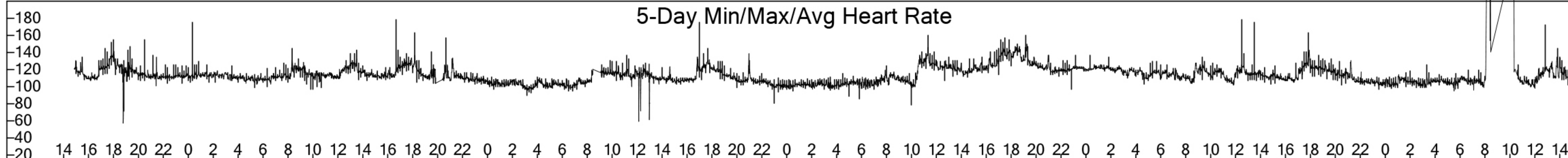


Patient Name:  
ID: 876 54 3210  
Age: 83 876 54 3210 Female Bed:  
Phone: 213 333 4444

Physician Name: admin  
Phone:  
E-Mail:

Medication/Comments: Crestor, Levo, Aspirin  
Symptom/indication: Dizzy  
ICD-10: I.44.9 & J.25.9



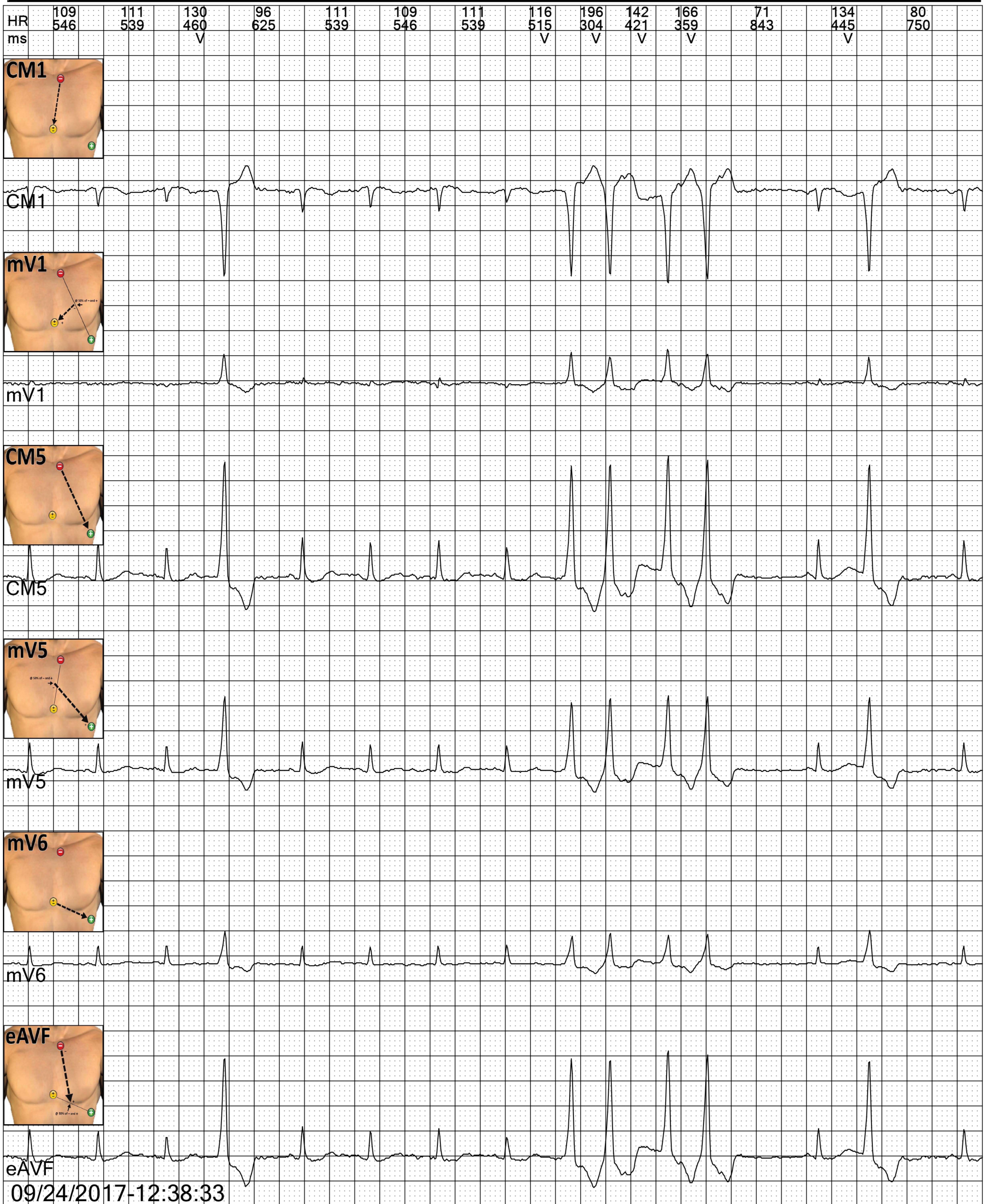09/23/2017-11:17:58

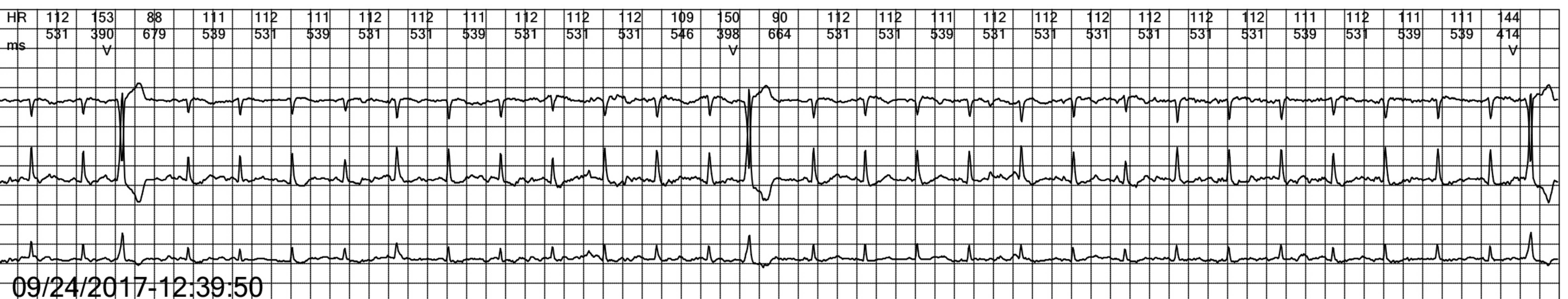
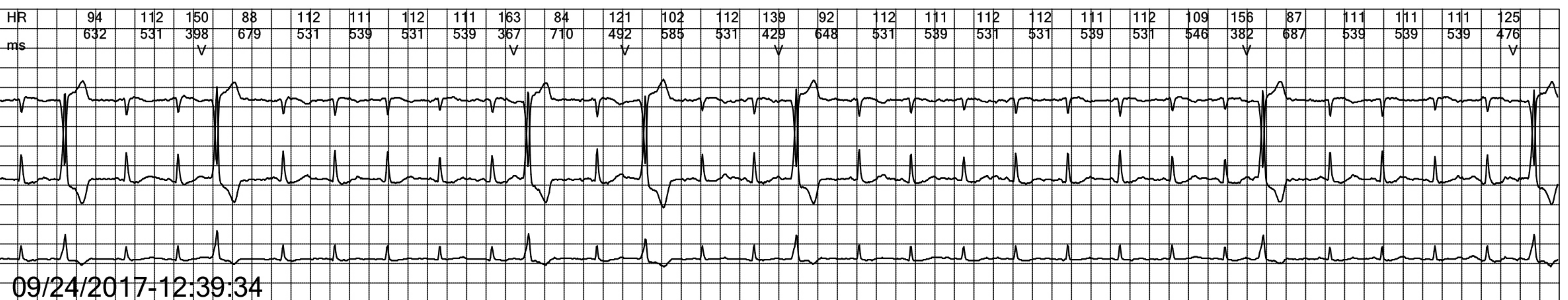
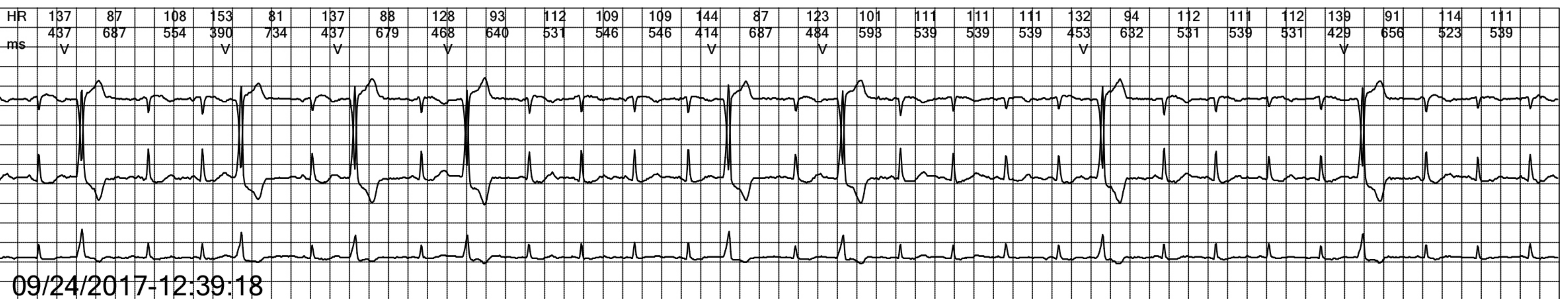
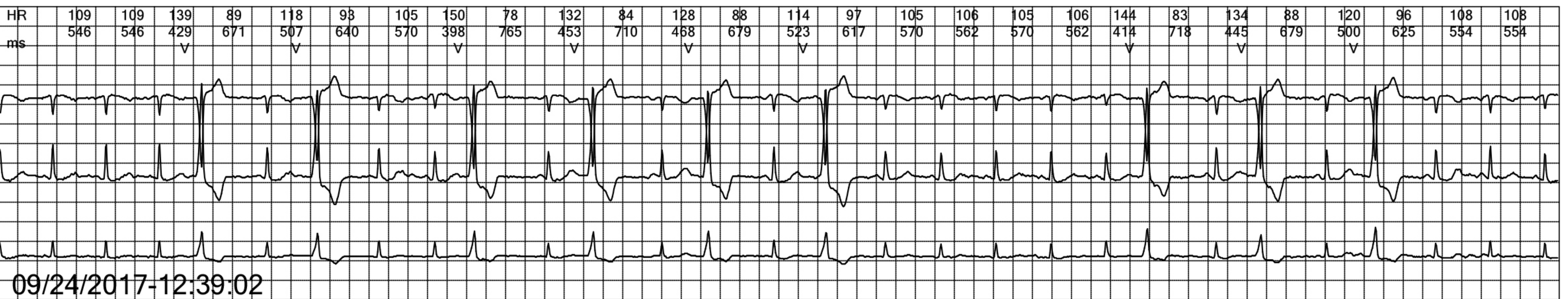
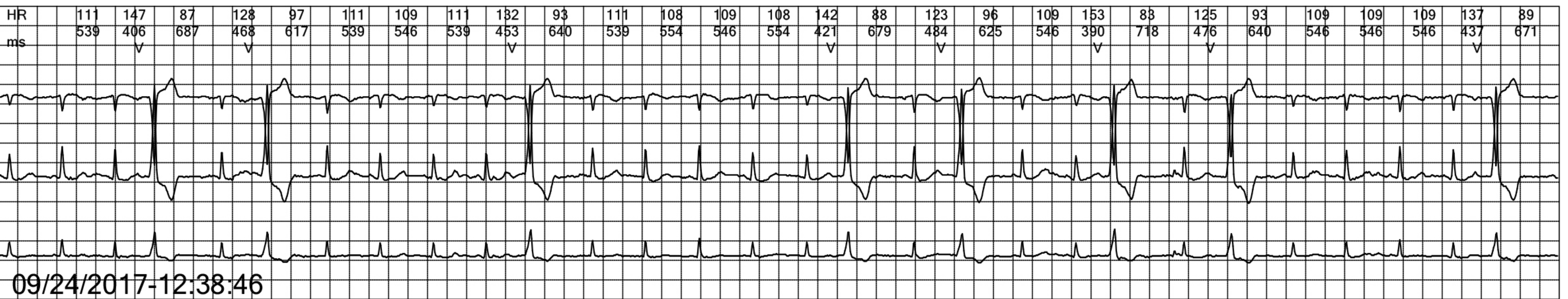
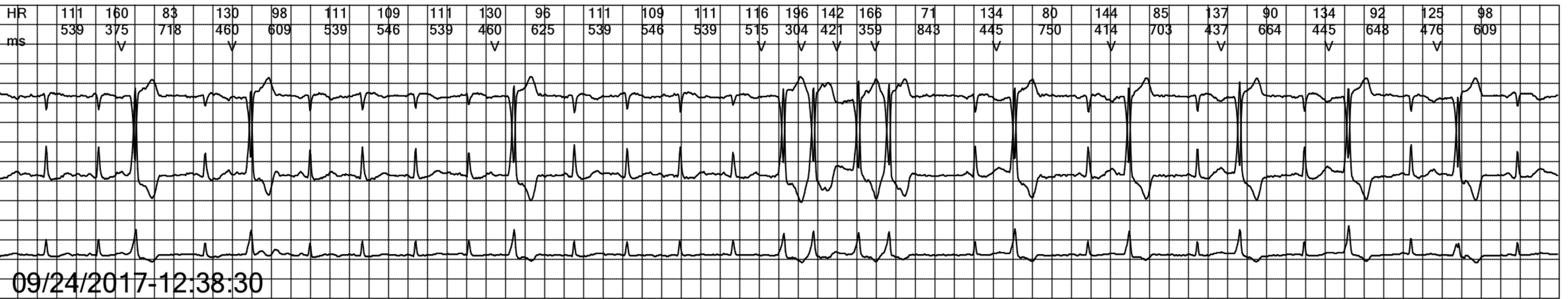
5-Day Comparisons	09/20 14:50	09/21 14:50	09/22 14:50	09/23 14:50	09/24 14:50	5-Day Average
AF Burden %	0.00%	0.00%	0.00%	0.00%	0.00%	0.00%
VE Burden %	30.09%(40394)	22.83%(29720)	19.17%(26217)	23.09%(34998)	20.00%(24874)	23.04%(31240)
SVE Burden %	0.04%(58)	0.02%(32)	0.02%(29)	0.01%(21)	0.03%(40)	0.02%(36)
Brady Burden %	1%	1%	0.00%	0.00%	0.00%	0.40%
Tachy Burden %	2.99%	6.11%	13.40%	35.49%	6.88%	12.97%
Min/AVG/Max HR (bpm)	59/100/128	58/95/123	67/95/133	88/105/134	58/96/127	66/98/129
ST Change	N/A	N/A	N/A	N/A	N/A	N/A
QTc	0 ms	0 ms	0 ms	0 ms	428 ms	428 ms
Longest Pause	0.00 s	0.00 s	0.00 s	0.00 s	0.00 s	N/A
Longest WCT	3@169 bpm	3@157 bpm	4@133 bpm	4@155 bpm	3@153 bpm	N/A
Blood Pressure	142/81	150/85		152/86	151/85	148/84
Respiration Rate/minute	9	8		8	8	8
SPO2	93	94		93	92	93
TEMP	97.1	97.1		97.1	97.1	97

CONCLUSIONS

Minimum Heart Rate was 58 bpm, Average Heart Rate was 98 bpm, and Maximum Heart Rate was 134 bpm.  
 Pauses more than 2.50 seconds were 0. ST episode minutes were 0.  
 Sinus Bradycardia minutes were 6; and Sinus Tachycardia minutes were 934.  
 Ventricular Ectopy was 157126, with 2071 V-Pairs and 32 V-Runs.  
 SupraVentricular Ectopy was 180, with 5 SV-Runs.  
 Atrial Fib Burden was 0.00%.

VE Burden for 6-days was an average burden of > 21% per day. Consider an ablation procedure.





09/24/2017-12:00

