

# UVEITIS IN EBOLA VIRUS DISEASE



Lessons learned in the 2014-2016 West African outbreak.

BY STEVEN YEH, MD, AND JESSICA SHANTHA, MD

The West African Ebola virus disease (EVD) outbreak of 2014 through 2016 was unprecedented in magnitude, with more than 28,600 cases and nearly 17,000 EVD survivors who remain at risk for ongoing morbidity due to myriad potential health sequelae of acute EVD.<sup>1</sup> The constellation of post-EVD sequelae has been dubbed post-Ebola virus disease syndrome, a term applied to a broad array of systemic health conditions that include arthritis, abdominal pain, mental health disorders, Ebola virus (EBOV) persistence in immune-privileged organs,<sup>2</sup> and ophthalmic complications including uveitis and optic neuropathy.<sup>3-5</sup>

The high prevalence of uveitis in EVD survivors, the clinical spectrum of disease, and the potential for EBOV persistence in ocular fluids and tissues raise important individual, public, and global health considerations. Ongoing clinical, translational, and basic science investigations are providing lessons in uveitis pathogenesis related to EBOV and potentially also providing clues to the infectious and inflammatory consequences of other ocular pathogens.

## EPIDEMIOLOGY AND RISK FACTORS

Before the most recent outbreak, little was known about the link between EVD and uveitis. One report from the Democratic Republic of the Congo described four EVD survivors with photophobia, pain, and blurred vision, which were attributed to uveitis.<sup>6</sup> Although the patients in this report experienced resolution of symptoms after treatment with topical

corticosteroids and cycloplegia, detailed information related to the severity of their disease presentation, secondary structural complications, and long-term outcomes were not reported.

During the current outbreak, the estimated prevalence of uveitis in EVD survivors in retrospective series has varied from 13% to 34%.<sup>2,3,7</sup> In Liberia, we and our coauthors identified uveitis in 22% of EVD survivors. Most of these patients presented with posterior uveitis (12 of 21 patients) or panuveitis (6 of 21 patients).<sup>3</sup> Consistent with these observations, two of eight repatriated US health care workers also presented with vision-threatening uveitis that eventually responded to therapy.<sup>4,8</sup>

The risk factors associated with uveitis development have been evaluated in retrospective cohort studies of EVD survivors. Factors identified include the

severity of acute EVD (as defined by viral load) and conjunctival injection during active EVD.<sup>2,7</sup> Further studies are needed regarding host- and disease-related factors that may be associated with uveitis.

## CLINICAL SPECTRUM OF DISEASE

A spectrum of uveitis, including anterior, intermediate, posterior, and panuveitis, has been observed in the convalescent phase of EVD.<sup>2,3,7,9,10</sup> In addition, the severity of disease at presentation varies between patients and between eyes in patients with bilateral disease. Some patients have anterior uveitis, which may be self-limited without therapy; by contrast, severe, aggressive panuveitis has been reported in a repatriated US health care worker who recovered from life-threatening acute EVD.<sup>5</sup> Approximately 3 months after EVD diagnosis, this patient developed a hypertensive anterior uveitis that

## AT A GLANCE

- ▶ The term post-Ebola virus disease syndrome applies to a broad array of systemic conditions and ophthalmic complications including uveitis and optic neuropathy.
- ▶ The high prevalence of uveitis in Ebola virus disease (EVD) survivors, the clinical spectrum of disease, and the potential for Ebola virus persistence in ocular fluids and tissues raise important health considerations.
- ▶ Lessons learned from the recent EVD outbreak in relation to ocular inflammation and viral persistence may be helpful in studying outbreaks of other emerging infectious diseases.

progressed to intermediate uveitis, severe scleritis, and subsequently to aggressive panuveitis with iris heterochromia. During disease progression, live EBOV was identified by reverse transcription polymerase chain reaction (RT-PCR) and cultured from the aqueous humor. A combination of systemic and local corticosteroid therapy and the investigational oral antiviral agent favipiravir eventually led to disease resolution, although disease recurrences were observed during long-term follow-up.<sup>4</sup>

In West Africa, blindness has been observed in some EVD survivors due to structural complications associated with uveitis, including cataract, hypotony, tractional retinal detachment (TRD), and phthisis bulbi (Figure 1). It is not known whether invasive ophthalmic procedures can be safely performed for visually significant cataract and TRD in these patients, given the risk of EBOV persistence in ocular fluids. Studies are under way to address these questions. The answers will be important in light of the number of patients with uveitis who require surgical care for cataract and vitreoretinal disease.<sup>11,12</sup>

Besides the wide spectrum of uveitis observed, other types of ocular inflammation, including episcleritis and interstitial keratitis, have been reported in a cohort of 341 EVD

## IN WEST AFRICA, BLINDNESS HAS BEEN OBSERVED IN SOME EVD SURVIVORS DUE TO STRUCTURAL COMPLICATIONS ASSOCIATED WITH UVEITIS, INCLUDING CATARACT, HYPOTONY, TRD, AND PHTHISIS BULBI.

survivors in Guinea.<sup>9</sup> Although uncommon, neuro-ophthalmic complications including optic neuropathy, ocular motility disorders, and nystagmus have been described.<sup>3</sup> The precise etiology of the development of optic neuropathy in these cases is unknown: that is, whether it is due to a primary optic nerve process or vascular insufficiency.

Some survivors have reported vision loss during acute EVD infection while hospitalized in the Ebola treatment unit (ETU) setting. Others have reported vision loss up to 2 months after discharge from the ETU. Future prospective evaluation of patients during acute EVD or shortly after clearance of EBOV from their blood will allow eye care providers to better understand the timing and spectrum of uveitis at patients' initial presentation.

Because of resource limitations and lack of eye care providers in many parts of West Africa, many patients have been examined after long-standing ocular inflammation in which structural complications and vision loss have already been observed (Figure 2). In our series of patients in Liberia, nearly 40% of patients showed visual impairment and 60% had developed blindness in their affected eye, underscoring the tremendous impact of vision loss due to uveitis.<sup>3</sup>

### PATHOGENESIS OF UVEITIS IN EVD

In a previous report from the Democratic Republic of the Congo regarding uveitis in EVD survivors, an immune-mediated hypersensitivity response was thought to be the likely driving factor behind uveitis.<sup>6</sup> After the discovery of EBOV in the aqueous

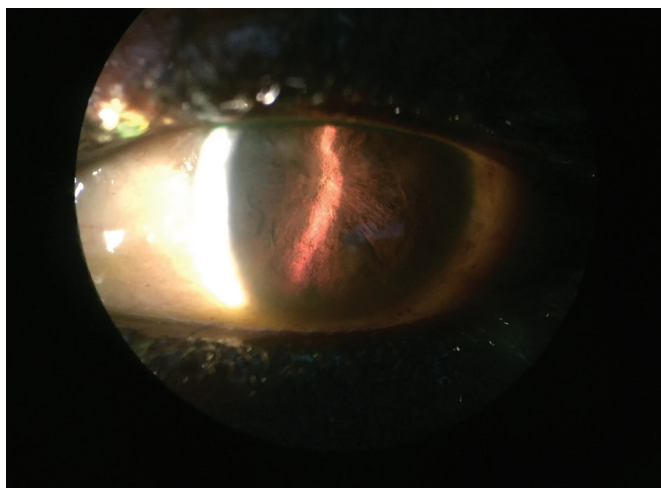


Figure 1. Slit-lamp photograph shows complete pupillary seclusion in an EVD survivor with chronic uveitis and hypotony.

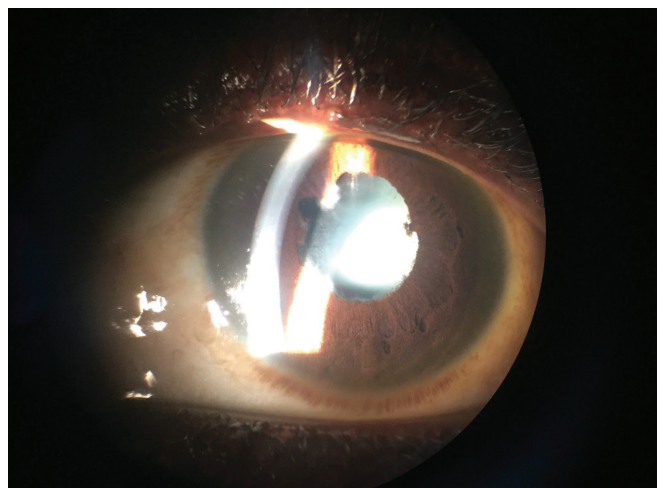
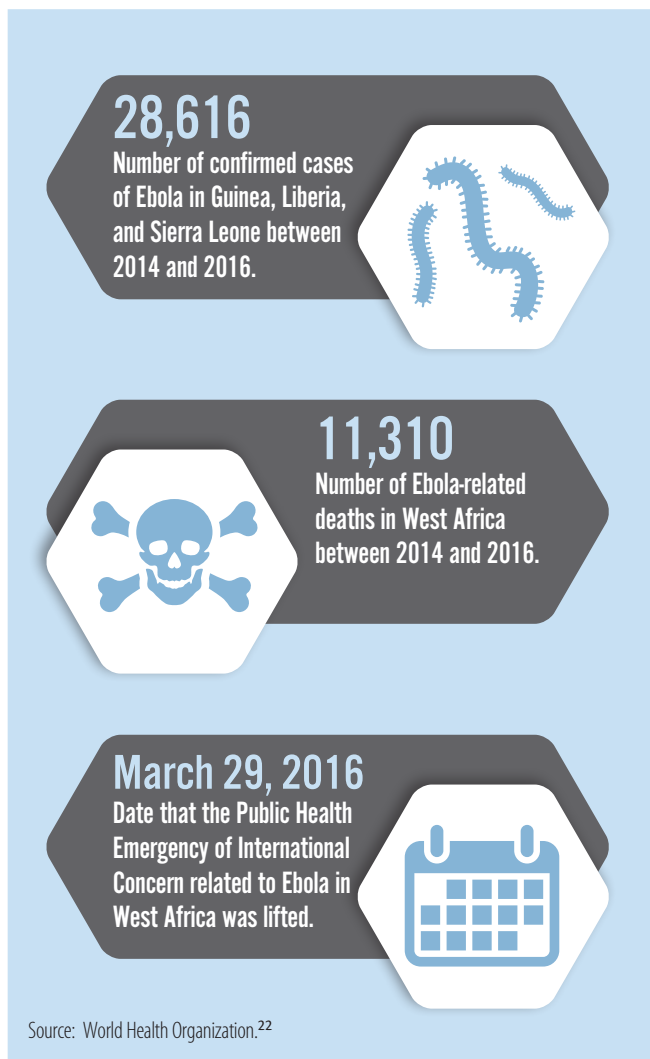


Figure 2. Slit-lamp photograph with an iPhone shows diffuse posterior synechiae and a cataract due to untreated uveitis in an EVD survivor.



humor 100 days after diagnosis of acute EVD, the role of direct lytic viral infection was established in uveitis in EVD survivors.<sup>5</sup> Clinical features and ophthalmic imaging have demonstrated intraocular inflammation and tissue edema involving the iris, ciliary body, and choroid as contributing factors as well. Recent clinical, translational, and basic science studies have improved our understanding of this disease syndrome.

#### **VIRAL PERSISTENCE IN IMMUNE-PRIVILEGED ORGANS**

In the most recent West African EVD outbreak, viral persistence in immune-privileged organs (ie, eye, central nervous system, reproductive organs, and semen) was described.<sup>13,14</sup> Given that EBOV transmission events have occurred (ie, sexual transmission<sup>15</sup> and transplacental transmission<sup>16</sup>), there is an ongoing public health risk with any exposure to fluids from immune-privileged locations (eg, cerebrospinal fluid, semen, and aqueous and vitreous humors), particularly when the status of EBOV persistence is not known.

Moreover, the recent outbreak has shown evidence of

longer duration of EBOV persistence than has previously been described, leading to changes in consensus guidelines related to public health issues such as the duration of time after EVD when patients may safely have unprotected sex. Specifically, EBOV persistence in semen in US health care workers has been found to be positive in RT-PCR and cultures at 290 and 70 days, respectively, after acute EVD infection.<sup>13</sup>

Among EVD survivors who have developed visually significant cataract, we have been conducting a study—the Ebola Virus Persistence in Ocular Tissues and Fluids Study, or EVICT—to evaluate the aqueous humor for viral persistence using EBOV RT-PCR.<sup>12</sup> We have previously reported that 22 survivors tested negative for EBOV by RT-PCR, and 16 individuals from this cohort who had cataracts underwent vision restorative cataract surgery.<sup>11</sup> Although this cohort was limited in size, the findings demonstrated safety, feasibility, and the potential for vision restoration via cataract surgery in EVD survivors.

Basic science investigations have been particularly informative in relation to the potential for EBOV persistence. Zeng and colleagues recently identified EBOV persistence in monocyte reservoirs within the vitreous cavity in a nonhuman primate (NHP) EVD survivor model.<sup>17</sup> EBOV could be identified at the vitreoretinal interface consistently in this NHP model and was associated with the presence of uveitis, retinitis, and gliotic tissue. In the laboratory, Smith et al have demonstrated that retinal pigment epithelium is susceptible to direct EBOV infection, supports viral replication, and releases virus in high titers.<sup>18</sup>

Given negative findings in aqueous humor and positive EBOV findings in the vitreous fluid of an NHP survivor animal model, further studies are needed regarding the appropriateness of vitreoretinal surgery in EVD survivors. This will be vital information in the West African region for both EVD survivors and patients without a history of EBOV infection.

#### **SYSTEMIC AND OCULAR INFLAMMATION**

The precise systemic and ocular immunologic environment in patients with EVD uveitis has been incompletely studied. However, the repatriation of US health care workers to Emory University during the height of the West African EVD outbreak provided an opportunity to evaluate the systemic immunologic status of EVD survivors.<sup>19</sup> In four EVD patients, robust immune responses were observed during acute EVD. However, after clearance of EBOV from plasma, immunologic activation was sustained, even at 1 month after the patients' discharge from the hospital. In addition, a repatriated health care worker from Liberia with predominantly intermediate uveitis demonstrated systemic markers of inflammation, including elevated erythrocyte sedimentation rate, perinuclear-antineutrophil cytoplasmic antibody (ANCA)-positive laboratory testing, and immunoglobulin G and immunoglobulin M antibody elevations, which were deemed nonspecific.<sup>8</sup>

## IMPLICATIONS

Before the 2014-2016 EVD outbreak, the limited number of EVD survivors and the sporadic nature of outbreaks, predominantly in rural locations in Central Africa, made it extremely difficult to systematically assess sequelae in EVD survivors. The recent West African outbreak has brought to light many important scientific and public health issues related to EBOV persistence, immunologic responses in EVD survivors, and opportunities to study EBOV reservoirs and seek more effective countermeasures.

From a global health standpoint, unfortunate gaps remain in care related to basic health services and subspecialty health services, including ophthalmic care. Case fatality rate due to EVD approximated 74% in Sierra Leone,<sup>20</sup> but in health care workers who were repatriated to the United States and European countries case fatality rate was 19%.<sup>21</sup> Similarly, the proportion of patients with severe vision impairment or blindness owing to uveitis was approximately 40% and 60%, respectively,<sup>3</sup> whereas the US health care workers who reportedly developed uveitis showed no evidence of permanent visual impairment, with the caveat that far fewer cases of EVD and subsequent uveitis have been documented in that population.<sup>4,8</sup>



## APPLICATION OF LESSONS LEARNED

To address the disparities in fatality rates and vision impairment between patients and repatriated health care workers, our Emory Eye Center team has developed multiple collaborations in order to develop educational symposia and to conduct research initiatives related to eye disease. We hope that these investigations will provide scientific rationale and data to drive clinical care.

In addition, fully investigating clinical and scientific implications in a large cohort of EVD survivors will help address many issues, including:

- determining the mechanisms of entry into and clearance of EBOV from the eye;
- determining whether EBOV may be harbored in the eye or other immune-privileged locations; and

- devising proper management strategies and developing appropriate therapeutics.

Other viral outbreaks continue to emerge, including Zika, West Nile, chikungunya, and dengue. There is the potential that lessons learned from EVD related to ocular inflammation and viral persistence will be helpful in studying these and other emerging infectious diseases of outbreak significance. ■

1. Vetter P, Kaiser L, Schibler M, Ciglenecki I, Bausch DG. Sequelae of Ebola virus disease: the emergency within the emergency. *Lancet Infect Dis*. 2016;16(6):e82-e91.
2. Tiffany A, Vetter P, Mattia J, et al. Ebola virus disease complications as experienced by survivors in Sierra Leone. *Clin Infect Dis*. 2016;62(11):1360-1366.
3. Shantha JG, Crozier I, Hayek BR, et al. Ophthalmic manifestations and causes of vision impairment in Ebola virus disease survivors in Monrovia, Liberia. *Ophthalmology*. 2017;124(2):170-177.
4. Shantha JG, Crozier I, Varkey JB, et al. Long-term management of panuveitis and iris heterochromia in an Ebola survivor. *Ophthalmology*. 2016;123(12):2626-2628.e2.
5. Varkey JB, Shantha JG, Crozier I, et al. Persistence of Ebola virus in ocular fluid during convalescence. *N Engl J Med*. 2015;372(25):2423-2427.
6. Kibadi K, Mupapa K, Kuvula K, et al. Late ophthalmologic manifestations in survivors of the 1995 Ebola virus epidemic in Kikwit, Democratic Republic of the Congo. *J Infect Dis*. 1999;179 (Suppl 1):S13-14.
7. Mattia JG, Vandy MJ, Chang JC, et al. Early clinical sequelae of Ebola virus disease in Sierra Leone: a cross-sectional study. *Lancet Infect Dis*. 2016;16(3):331-338.
8. Chancellor JR, Padmanabhan SP, Greenough TC, et al. Uveitis and systemic inflammatory markers in convalescent phase of Ebola virus disease. *Emerg Infect Dis*. 2016;22(2):295-297.
9. Hereth-Hebert E, Bah MO, Etard JF, et al. Ocular complications in survivors of the Ebola outbreak in Guinea. *Am J Ophthalmol*. 2017;175:114-121.
10. Steptoe PJ, Scott JT, Baxter JM, et al. Novel retinal lesion in Ebola survivors, Sierra Leone, 2016. *Emerg Infect Dis*. 2017;23(7):1102-1109.
11. Shantha JG, Teshome M, Mattia J, Garry RF, Vandy MJ, Yeh S. Ebola Virus Persistence in Ocular Tissues and Fluids (EVICT) II Study: cataract surgery and RT-PCR outcomes in Ebola virus disease survivors. Poster presented at: Association for Research in Vision and Ophthalmology Annual Meeting; May 7-11, 2017; Baltimore.
12. Yeh S, Shantha JG, Mattia J, Garry RF, Vandy MJ. Ebola Virus Persistence in Ocular Tissues and Fluids (EVICT) Study: baseline characteristics and primary findings from ocular fluid of Ebola survivors in Sierra Leone. Poster presented at: Association for Research in Vision and Ophthalmology Annual Meeting; May 7-11, 2017; Baltimore.
13. Uyeiki TM, Erickson BR, Brown S, et al. Ebola virus persistence in semen of male survivors. *Clin Infect Dis*. 2016;62(12):1552-1555.
14. Deen GF, Knust B, Broutet N, et al. Ebola RNA persistence in semen of Ebola virus disease survivors - preliminary report. *N Engl J Med*. 2017;377(15):1428-1437.
15. Christie A, Davies-Wayne GJ, Cordier-Lassalle T, et al. Possible sexual transmission of Ebola virus - Liberia, 2015. *MMWR Morb Mortal Wkly Rep*. 2015;64(17):479-481.
16. Muehlenbachs A, de la Rosa Vazquez O, Bausch DG, et al. Ebola Virus disease in pregnancy: clinical, histopathologic, and immunohistochemical findings. *J Infect Dis*. 2017;215(1):64-69.
17. Zeng X, Blancett CD, Koistinen KA, et al. Identification and pathological characterization of persistent asymptomatic Ebola virus infection in rhesus monkeys. *Nat Microbiol*. 2017;2:17113.
18. Smith JR, Todd S, Ashander LM, et al. Retinal pigment epithelial cells are a potential reservoir for Ebola virus in the human eye. *Transl Vis Sci Technol*. 2017(4):6:12.
19. McElroy AK, Akondy RS, Davis CW, et al. Human Ebola virus infection results in substantial immune activation. *Proc Natl Acad Sci U S A*. 2015;112(15):4719-4724.
20. Schieffelin JS, Shaffer JG, Goba A, et al. Clinical illness and outcomes in patients with Ebola in Sierra Leone. *N Engl J Med*. 2014;371(22):2092-2100.
21. Uyeiki TM, Mehta AK, Davey RT Jr, et al. Clinical management of Ebola virus disease in the United States and Europe. *N Engl J Med*. 2016;374(22):636-646.
22. World Health Organization. Situation report: Ebola virus disease. [http://apps.who.int/iris/bitstream/10665/208883/1/ebolasitrep\\_10Jun2016\\_eng.pdf?ua=1](http://apps.who.int/iris/bitstream/10665/208883/1/ebolasitrep_10Jun2016_eng.pdf?ua=1). June 10, 2016. Accessed December 20, 2017.

### JESSICA G. SHANTHA, MD

■ Assistant Professor, Section of Vitreoretinal Surgery and Diseases, Section of Uveitis and Vasculitis, Emory Eye Center, Emory University School of Medicine, Atlanta, Georgia

■ [jgshantha@gmail.com](mailto:jgshantha@gmail.com)

■ Financial disclosure: None acknowledged

### STEVEN YEH, MD

■ M. Louise Simpson Associate Professor and Director of the Uveitis and Vasculitis Section at the Emory Eye Center, Emory University School of Medicine, and Associate Professor, Emory Global Health Institute, both in Atlanta, Georgia

■ [steven.yeh@emory.edu](mailto:steven.yeh@emory.edu)

■ Financial disclosure: None acknowledged