



ISSN: 2230-9926


Available online at <http://www.journalijdr.com>

IJDR

International Journal of Development Research

Vol. 11, Issue, 02, pp. 44696-44701, February, 2021

<https://doi.org/10.37118/ijdr.21163.02.2021>



RESEARCH ARTICLE

OPEN ACCESS

FACIAL PATTERN OF CHILDREN WITH MICROCEPHALY

Camila da Silva Novaes*¹, Ivigna Ferraz Neves Oliveira², Janaína Taiza Araújo de Jesus³, Joelson Ferreira Santana³, Maria da Conceição Andrade de Freitas⁴, Marina Ferraz Neves Oliveira⁴, Rita de Cássia Dias Viana Andrade⁴ and Taylline das Mercês Gonçalves⁵

¹Universidade Estadual do Sudoeste da Bahia/UESB, Jequié/BA, Brasil, 45208-707; ²Colegiado de Odontologia, Centro Universitário UniFTC, Vitória da Conquista/BA, Brasil, 45027-333; ³Universidade Estadual do Sudoeste da Bahia/UESB, Jequié/BA, Brasil, 46190-000; ⁴Departamento de Saúde, Universidade Estadual do Sudoeste da Bahia/UESB, Jequié/BA, Brasil, 40170-400; ⁵Universidade Estadual do Sudoeste da Bahia/UESB, Jequié/BA, Brasil, 45208-361

ARTICLE INFO

Article History:

Received 01st December, 2020

Received in revised form

19th December, 2020

Accepted 20th January, 2021

Published online 28th February, 2021

Key Words:

“Deciduous Teeth”.

“Face”. “Microcephaly”.

“Craniofacial Abnormalities”.

*Corresponding author:

Camila da Silva Novaes

ABSTRACT

Oral health care involves dental development, the stomatognathic system, and craniofacial growth in early childhood in order to significantly reduce corrective measures. However, what about individuals with microcephaly? The present study explores the morphological diagnosis of the faces of these children. The study population corresponded to seven Brazilian children with microcephaly, without other associated syndromes with the complete deciduous dentition. The data collection consisted of the analysis of the facial characteristics obtained from clinical records and photos from the front and lateral views of the face at rest. There was a predominance of the dolichofacial type (100%) in the frontal norm analysis. In the lateral norm analysis, there was a predominance of Standard II children (85.71%) compared to Standard I (14.29%) children. The proportion of severe Microcephaly (-3 SD) was higher in males ($P = 0.04$). There was no association between the severity of microcephaly and the facial type ($P > 0.05$), although the Standard II pattern was more prevalent in severe microcephaly (100% of cases). The recommendation for the longitudinal monitoring of the mandibular growth vector of these individuals is essential, which is significant for the diagnosis and prognosis of the orthopedic treatment while there is still craniofacial growth.

Copyright © 2020, Camila da Silva Novaes et al. This is an open access article distributed under the Creative Commons Attribution License, which permits unrestricted use, distribution, and reproduction in any medium, provided the original work is properly cited.

Citation: Camila da Silva Novaes, Ivigna Ferraz Neves Oliveira, Janaína Taiza Araújo de Jesus, Joelson Ferreira Santana, Maria da Conceição Andrade de Freitas, Marina Ferraz Neves Oliveira, Rita de Cássia Dias Viana Andrade and Taylline das Mercês Gonçalves, 2021. “Facial pattern of children with microcephaly”, *International Journal of Development Research*, 11, (02), 44696-44701.

INTRODUCTION

Microcephaly is a clinical condition in which the child presents significant reduction in the occipitofrontal circumference of the head when compared to others of the same sex and age. In addition to craniofacial disproportion, it can lead to joint malformation in the limbs, changes in neuropsychomotor growth and development, as well as hearing and visual deficiencies (DEVAKUMAR et al., 2018; FRANCE et al., 2020; WHO, 2016). In Brazil, in 2016, the Ministry of Health adopted operational definitions based on the cephalic perimeter (CP) measurement in accordance with WHO, creating a normative reference for the first 24-48h of life, using the InterGrowth parameters for both sexes. In this new CP reference table, the standard measure for the newborn (NB) is 31.5 cm for girls and 31.9 cm for boys (INTERGROWTH-21st, [n.d.]; BRAZIL, MINISTRY OF HEALTH, 2017; WHO, 2016). The World Health Organization defines Microcephaly cases as NB with a CP lower than -2 standard

deviations (SD), i.e., more than 2 SD below the mean for gestational age and sex. Severe Microcephaly cases are NB with a cephalic perimeter of less than -3 SD, i.e., more than 3 SD below the mean for gestational age and sex (WHO, 2016). From the moment it is formed, during the embryonic period, until it reaches its definitive dimension, in the skeletal maturity, the face emerges from the base of the skull, driven in the three space dimensions. In individuals with no congenital malformations involving the face, there is a genetic determinism for the facial configuration, which ends up being a product of the morphogenetics. Extragenetic factors become more important when congenital malformations mutilate the anatomy (CAPELOZZA FILHO, 2005; LEWIS; ROCHE; WAGNER, 1985; SILVA FILHO, 1989). In early childhood, the face has not yet reached its definitive dimensions. The maxilla and mandible have not reached yet their final dimensions and will exhibit considerable growth until skeletal maturity. However, the tendency is for the facial configuration to remain constant during growth, which is why, at this stage, it must be identified, defining the facial pattern of the individual. Facial analysis consists of morphological analysis of the

face by the arrangement of its soft tissues. This analysis expresses the spatial organization of the basal bones, maxilla, and mandible by facial geometry, identifying skeletal balance or discrepancy (SILVA FILHO et al., 2008; ENLOW; HANS, 1998). However, although craniofacial growth and development are directly associated with genetic factors, they are strongly influenced by the functional pattern of the orofacial musculature. In this context, can this congenital malformation interfere with growth and development? At what magnitude and in which direction will growth express itself? The reviewed literature demonstrates the occurrence of changes in the chronology and sequence of tooth eruption, as well as alterations in the facial muscle tone, breathing, and swallowing in infant children born at term, diagnosed with microcephaly at birth, associated with the Zika virus congenital syndrome (D'AGOSTINO et al, 2020; FARIA, FEITOSA & CANUTO, 2020; RIBEIRO et al, 2020). Regarding craniofacial development, recent studies have reported differences when comparing children with microcephaly associated with the Zika virus congenital syndrome with those in the control group, without microcephaly, at the same age of 24 months. In the craniofacial analysis, cephalometric measurements were significantly lower in children with microcephaly, showing an indication of possible delay in craniofacial growth (Carvalho-Sauer et al, 2020; RIBEIRO et al, 2020). In this context of increase in the number of cases of microcephaly in Brazil and based on the scientific knowledge that the facial pattern is maintained during growth, the identification of patterns of face morphology still in the early childhood, in children with microcephaly is an important contribution. These patterns result from the arrangement of the soft tissues of the face and their identification contribute significantly for health professionals to adequately perform preventive and intervening measures on these individuals. These actions are key points for defining a realistic prognosis and preparation of a health care protocol. This research aimed to analyze the morphological characteristics of the resting face at the stage of complete deciduous dentition of children with microcephaly, living in Jequié and neighboring municipalities of Bahia, Brazil.

MATERIAL AND METHODS

This is a clinical study with a cross-sectional approach that was conducted after approval by the Ethics Committee of the Universidade Estadual do Sudoeste da Bahia (UESB) under the protocol n° 3.932.364/2019, in accordance with the recommendations of the Declaration of Helsinki. The norms of the guidelines for observational studies described by Von Elm et al (2009) were followed. The study population involved newborn (NB) children diagnosed with microcephaly, from both sexes, Brazilian nationality, 3 to 6 years old, and with complete deciduous dentition. As inclusion criteria, all children should have clinical records, front and lateral facial pictures at rest and intraoral photographs obtained from the documentation file of the UESB Dentistry Unit. Children diagnosed with syndromes were not included in the study, as well as those with the presence of a permanent tooth that was partially or totally erupted. The diagnosis of Microcephaly (NB born at term with a cephalic perimeter lower than -2 standard deviations for his/her gestational age and sex) or Severe Microcephaly (NB born at term with a cephalic perimeter of less than -3 standard deviations for his/her gestational age and sex) was obtained from the medical records, as well as the data on sex, age, and color/race (IBGE, 2000; INTERGROWTH-21st, [n.d.]; WHO, 2016). The classification of the complete deciduous dentition was obtained from the clinical records and from the analysis of intraoral photos of these children. The facial examination of each child consisted of the clinical morphological analysis, in frontal and lateral views, present in the upper, middle, and lower facial thirds. The sagittal and vertical facial traits were based on the pattern developed by Capelozza Filho (2005). In the sagittal analysis the face can be grouped into three distinct patterns: Standard I, Standard II, and Standard III. Pattern I reflects a facial balance, in which the maxilla and mandible are well disposed, presenting a harmonious face. In addition, they exhibit facial symmetry, proportion, and balance between facial thirds, good

zygomatic projection, pleasant nasolabial angle, passive or discrete interlabial space, harmonious labiomentonian curvature, and well-defined chin-neck line and angle. Pattern II is defined by a positive sagittal step between the maxilla and mandible resulting from mandibular deficiency and/or upper dental protrusion, revealing an excess of facial convexity. In contrast, Pattern III exhibits a negative sagittal step between the maxilla and mandible due to mandibular prognathism and/or maxillary protrusion, with reduced facial convexity. In frontal view, the face was classified in three morphological types: dolichofacial, mesofacial, and brachyfacial. In the dolichofacial configuration, the vertical dimensions of the face prevail over the horizontal dimensions, resulting in a longer silhouette. In the brachyfacial configuration, the transverse dimensions exceed the vertical dimensions, making up a wider face. The equivalence of the transverse and vertical dimensions characterizes the face as mesofacial. The three configurations described must exhibit characteristics such as symmetry, proportionality between the facial thirds, and passive lip seal with compatibility between the length of the soft lip and the length of the lower third of the face.

The Long Face and Short Face Patterns are discrepancies observed in the vertical plane, representing the extrapolation of the normal face in frontal view. The Long Face Pattern depicts a specific feature: the lips do not touch, the patient has exposure of the resting anterior teeth and smiling gums caused by the excess of the lower third of the face, including the jaw (CAPELOZZA FILHO, 2005). In this research, the patients classified as dolichofacials were included in the "Long Face" pattern while the brachyfacial patients exhibited the "Short Face" pattern. The analysis of the face morphology at rest was recorded through extraoral photographs of the children with Microcephaly, selected from charts specially designed for this purpose, as well as the registration data, the stage of the deciduous dentition, and the facial traits of these patients. The reproducibility was evaluated through intra-examiner agreement, performed through the Kappa test. Two researchers with orthodontic training (LMAF; MCAF) were trained, calibrated, and a pilot study with 5 medical records was conducted. Data collection started after an "almost perfect" inter-examiner agreement (Kappa > 0.80). The data were analyzed using the Statistical Package for the Social Sciences SPSS version 21.0 (SPSS Inc., Chicago, USA). The descriptive statistics were calculated by means of the central tendency measurement as well as the frequency of sex and microcephaly classification. The inferential analysis between the type of Microcephaly and the independent variables (clinical factors) were determined by the Fischer's Exact test, with a 5% significance level.

RESULTS AND DISCUSSION

A total of 13 medical records of children with the diagnosis of microcephaly were identified in the file of the Dentistry Unit at the UESB during the research period. Among these documents, one child was diagnosed with Cri-du-Chat syndrome (n=1), two had partial irruption of the first permanent molars (n=2), one presented incomplete deciduous dentition (n=1), and two did not contemplate the age proposed in this study (n=2). Therefore, 7 children between 3 and 5 years old (mean age = 3.6 y + 0.22) were analyzed, 3 males (42.8%) and 4 females (57.2%), brown, at the stage of complete deciduous dentition, with 2 (28.5%) children being diagnosed with microcephaly and 5 (71.5%) with severe microcephaly according to WHO classification (Table 1). After the morphological analyses of the face at rest, seen in frontal view, all the children were disproportional in the upper facial third in relation to the other two thirds due to a significant reduction in the occipitofrontal circumference of the head. Besides this narrowing of the cephalic perimeter, six children presented a flat forehead (Fig. 1ab) and a child with frontal prominence (Fig. 2ab). The seven children were classified according to the frontal facial type in brachyfacial, mesofacial, or dolichofacial. In this study, all the children were classified as dolichofacial (Table 2) (Fig. 3). Regarding the sagittal standards, one was considered Standard I (14.29%) (Fig. 4) and six were Standard II

Table 1. Data of the selected children according to age, sex, race (IBGE), dentition stage, and Microcephaly classification according to the WHO, in Jequié, Bahia, Brazil, 2020

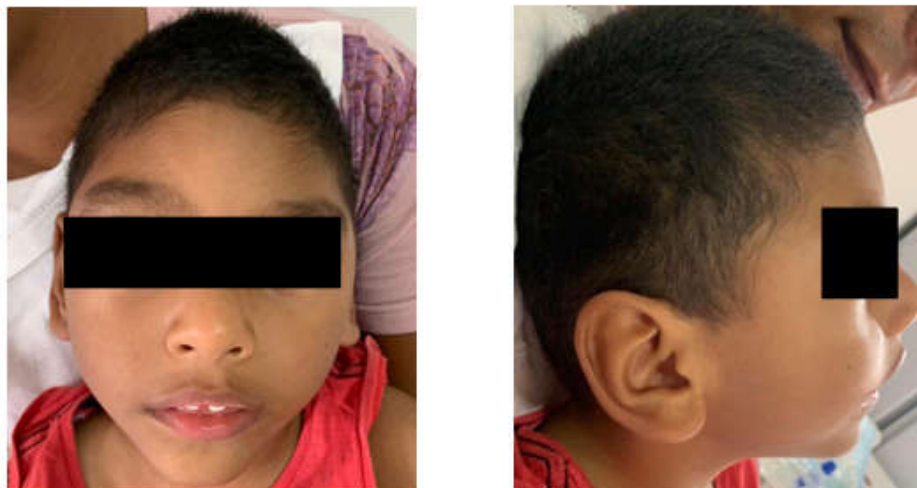Clinical Case	Age	Sex	Race	Dentition Stage	Microcephaly Classif. (CP/SD)
1	3y 8m	Female	Brown	Complete Deciduous	Severe microcephaly (-3SD)
2	4y 1m	Male	Brown	Complete Deciduous	Severe microcephaly (-3SD)
3	3y 7m	Male	Brown	Complete Deciduous	Severe microcephaly (-3SD)
4	3y 5m	Female	Brown	Complete Deciduous	Microcephaly (-2SD)
5	3y 4m	Female	Brown	Complete Deciduous	Microcephaly (-2SD)
6	3y 6m	Female	Brown	Complete Deciduous	Severe microcephaly (-3SD)
7	3y 6m	Male	Brown	Complete Deciduous	Severe microcephaly (-3SD)

Note: CP – Cephalic Perimeter; SD– Standard Deviation
Source: The authors

Table 2. Data on children selected according to age, sex, morphological characteristics of facial patterns, and types and classification of Microcephaly by the WHO. Jequié, Bahia, Brazil, 2020

Clinical Case	Age	Sex	Facial Type	Facial Pattern	Microcephaly Classif. (CP/SD)
1	3y 8m	Female	Standard II	Dolicofacial	Severe Microcephaly (-3SD)
2	4y 1m	Male	Standard II	Dolicofacial	Severe Microcephaly (-3SD)
3	3y 7m	Male	Standard II	Dolicofacial	Severe Microcephaly (-3SD)
4	3y 5m	Female	Standard I	Dolicofacial	Microcephaly (-2SD)
5	3y 4m	Female	Standard II	Dolicofacial	Microcephaly (-2SD)
6	3y 6m	Female	Standard II	Dolicofacial	Severe Microcephaly (-2SD)
7	3y 6m	Male	Standard II	Dolicofacial	Severe Microcephaly (-3SD)

Note: CP-Cephalic Perimeter; SD-Standard Deviation
Source: The authors



Source: The authors.

Figure 1. Facial photographs of patient at 3 years and 6 months old with severe Microcephaly with disproportion between the facial thirds

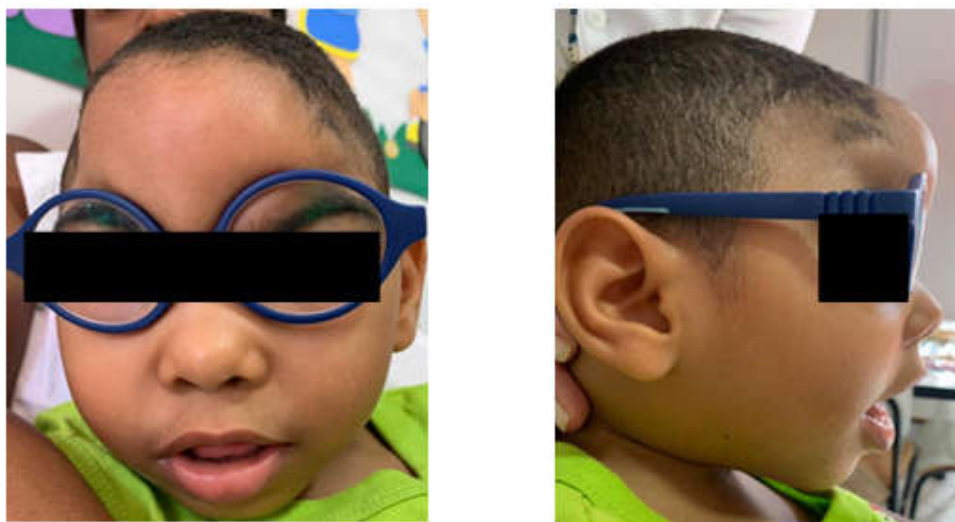
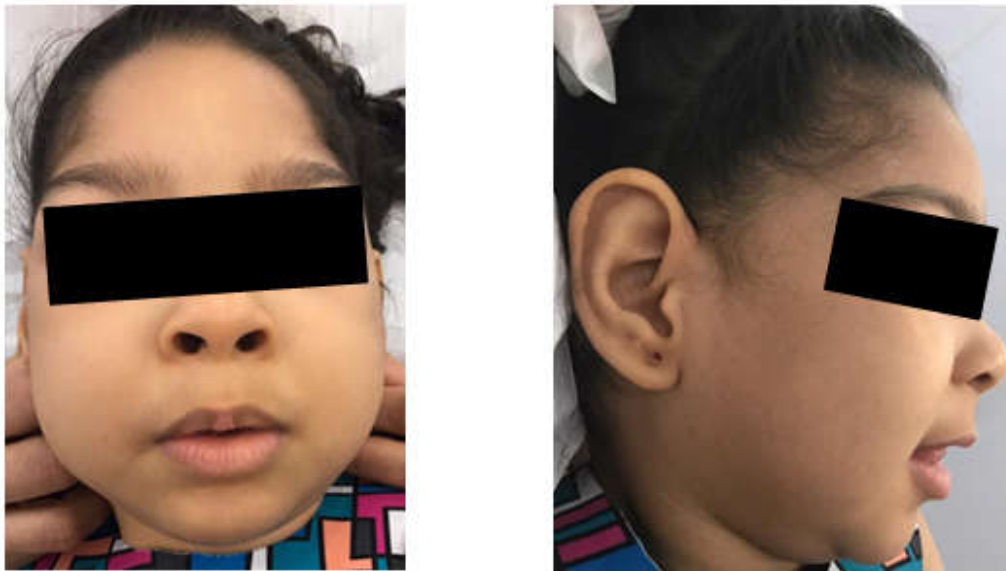
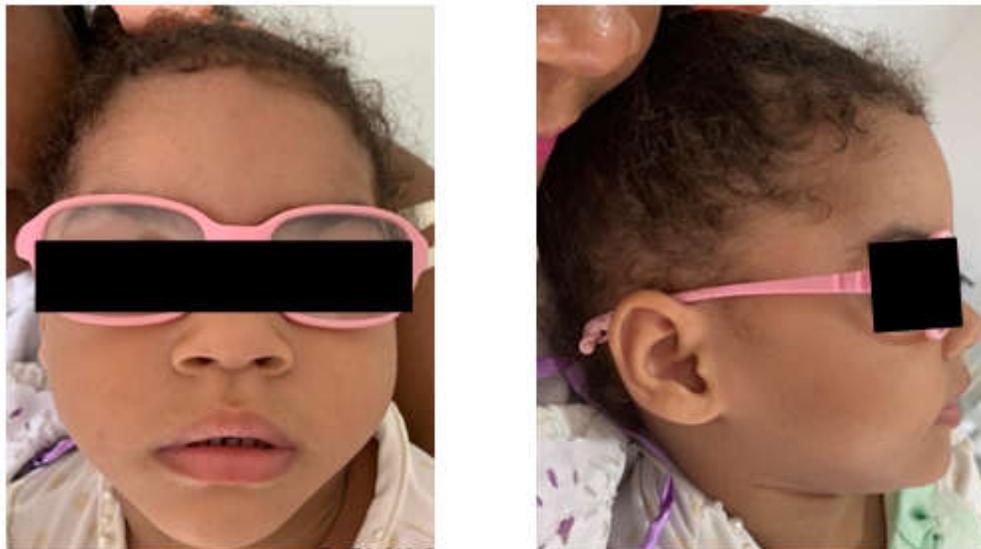Figure 2. Facial photographs of patient at 3 years and 7 months old with severe Microcephaly without equivalence of the facial thirds



Note: Upper third narrow and plane (aandb).
Source: The authors.

Figura 3. Facial photographs of patient with severe Microcephaly at 3 years and 6 months old. Pattern II, dolicocefal (aandb)



Source: The authors.

Figure 4. Facial photographs of patient with Microcephaly at 3 years and 5 months of age. Pattern I, dolicocefal (aandb)

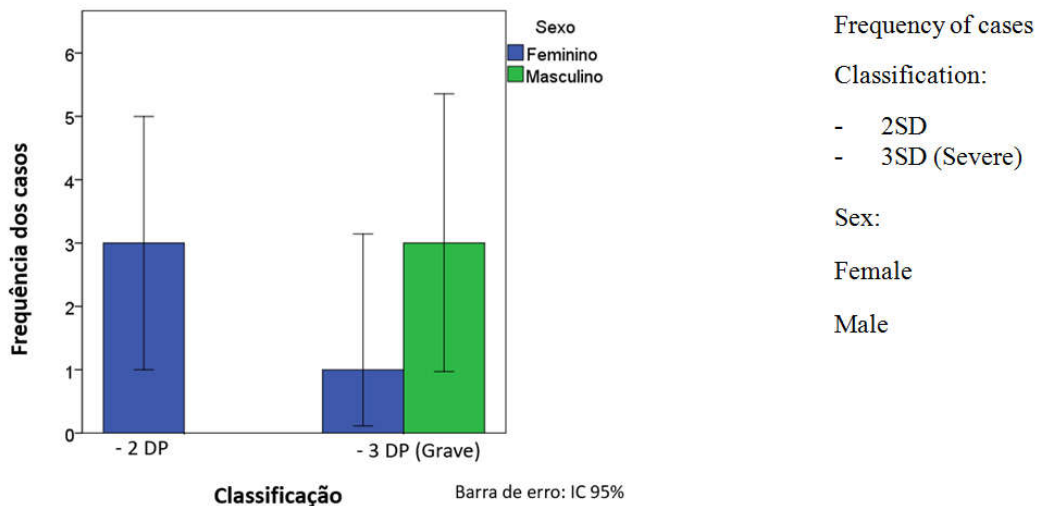


Figure 5. Rate of severity of microcephaly according to sex

(85.71%)(Fig. 3) (Table 2). The chin-neck line and angle analyses were not carried out because they were not defined in most facial photographs of the selected individuals. Fisher's exact statistical test was applied to evaluate potential associations between clinical parameters (sex, facial type, facial pattern) following the Microcephaly classification of the WHO (Table 2). The Fisher's exact test showed that the proportion of severe Microcephaly (-3 SD) was higher in males ($P = 0.04$) (Fig 5). No association was observed between the severity of microcephaly and facial type ($P > 0.05$), although the Type II pattern was more predominant in severe microcephaly (100% of cases). Several studies point out that although there are increases in craniofacial growth after early childhood, especially in the vertical and mandibular planes, deviations in the growth pattern may already be identified and we refer to intervening protocols in an attempt to re-establish a morphological environment conducive to the attempt to adequate craniofacial growth (ENLOW; HANS, 1998; SILVA FILHO et al., 2008; NIEMI et al., 2019). In accordance with these principles, this research analyzed the facial morphology of patients with a mean age of 3 years and 6 months ($SD = +0.22$) by using photographs, since it has proven to be the most feasible and ethical method for defining the facial features of children with microcephaly with neuropsychomotor impairment.

The most important limitations of this study may be represented by the small number of children studied, the absence of previous investigations, and the quality of facial photographs. Due to the neurological impairment of the children with microcephaly it was not possible to obtain the dental occlusion at the time of the photograph. The resting position was associated with orofacial muscle relaxation, clockwise mandibular rotation, and atypical lingual interposition. Regarding sexual dimorphism, this work showed a higher amount of Severe Microcephaly (-3SD) in males. Although 100% of cases with severe microcephaly had a predominance of Pattern II, no association was found between the severity of microcephaly and facial type ($P > 0.05$). This may be explained by the small sample size, which compromised the power to detect differences between these variables. It is worth noting that, although in this study the small size of the sample was a significant limiting variable, it is essential to highlight the importance of longitudinal monitoring of the mandibular growth vector of these patients, which is significant for the diagnosis and prognosis of craniofacial growth and development (Carvalho-Sauer et al., 2020; FRANCE et al., 2018). Ribeiro et al (2020), analyzing the functions of the stomatognathic system of babies with microcephaly, recommended future studies targeting the description of the orofacial functional status of microcephalic patients due to its importance in the understanding of craniofacial growth, as well as for speech development, swallowing, and chewing of children with microcephaly. Previous epidemiological surveys on facial morphology of Brazilian children without craniofacial anomalies and/or syndromes, with the deciduous dentition, found that in almost two thirds of the evaluated children there was a predominance of 69.9% (TRALDI et al., 2015) and 63.22% (SILVA FILHO et al., 2008) of Standard I in relation to Standards II and III. In the present study, with using a methodology similar to previous researches, the results obtained in the sagittal analysis of the face of children with microcephaly revealed a predominance of Standard II.

In this study, the morphological definition of Standard II in 85.71% of the children with microcephaly involved a disharmony in the sagittal relationship between the apical bases, with a positive sagittal gap between the maxilla and mandible. This resulted in an excess of facial convexity. The maxilla and/or upper incisors were projected forward in the sagittal direction, with a clockwise rotation of the mandible. These facial traits were also evaluated in a comparative study between children with deciduous dentition with/without a history of night snoring and absence/presence of passive lip seal, with a statistically significant increase in facial convexity being found in mouth-breathing children (NIEMI et al., 2019). In the frontal analysis of this study, the vertical dimensions of the face prevailed over the horizontal ones, classifying all children as dolichofacials. There was no passive lip seal with exposure of the anterior upper teeth and lingual interposition between the anterior teeth, revealing a potential

predisposition to a long face, evidenced by the increase of the lower third of the face in relation to the other two thirds. However, Silva Filho et al (2008) in an epidemiological survey with 2009 Brazilian children in the early childhood found that there was a predominance of the mesofacial type (64.56%) compared to the dolichofacial (21.90%) and brachyfacial (13.54%) types. The authors also evaluated the distribution of frontal facial types within the sagittal facial patterns, showing that the dolichofacial type tends to be more frequent in Pattern II. In the present study, there was an agreement on this clinical finding in 85.71% of the children with microcephaly. The greater the alteration of the orofacial structures, the more compromised the therapeutic evolution of the child with microcephaly might become, given the facial morphological limitations. It is important to emphasize the relevance of the early investigation of the growth and development of the face of these individuals in the sagittal and vertical planes. Additional research with a larger sample and functional evaluation of breathing, swallowing, and chewing are necessary to investigate the craniofacial morphology in order to provide early diagnosis and treatment of these children.

CONCLUSION

According to the results obtained in this study, the characterization of the Type II facial pattern, with a predominance of vertical growth, shows a disproportion of the apical bases, maxilla, and mandible, suggesting an early correction to improve the facial configuration of children with microcephaly. Orthopedic therapies are procedures adopted for the correction of this skeletal deviation while there is still craniofacial growth.

REFERENCES

- BRASIL; MINISTÉRIO DA SAÚDE. Orientações integradas de vigilância e atenção à saúde no âmbito da Emergência de Saúde Pública de Importância Nacional: procedimentos para o monitoramento das alterações no crescimento e desenvolvimento a partir da gestação até a primeira infância, relacionadas à infecção pelo vírus Zika e outras zoonoses infecciosas dentro da capacidade operacional do SUS [recurso eletrônico]. 2017. Available at: http://bvsms.saude.gov.br/publicacoes/orientacoes_emergencia_gestacao_infancia_zika.pdf. Accessed: 11/28/2020.
- CAPELOZZA FILHO, L. Diagnóstico em ortodontia. Maringá: Dental Press Editora, 2005.
- Carvalho-Sauer RCO, Costa MDCN, Paixão ES, de Jesus Silva N, Barreto FR, Teixeira MG. Cross-sectional study of the anthropometric characteristics of children with congenital Zika syndrome up to 12 months of life. *BMC Pediatr.* 2020 Oct 14;20(1):479. DOI: 10.1186/s12887-020-02365-6 PMID: 33054749; PMCID: PMC7557056. Accessed: 11/28/2020.
- D'Agostino ES, Chagas JRLP, Cangussu MCT, Vianna MIP. Chronology and sequence of deciduous teeth eruption in children with microcephaly associated to the Zika virus. *Spec Care in dentistry.* V. 4, N.1., p. 3-9, 2020. <https://doi.org/10.1111/scd.12435>
- Devakumar D, Bamford A, Ferreira MU, Broad J, Rosch RE, Groce N, Breuer J, Cardoso MA, Copp AJ, Alexandre P, Rodrigues LC, Abubakar I. Infectious causes of microcephaly: epidemiology, pathogenesis, diagnosis, and management. *Lancet Infect Dis.* 2018 Jan;18(1):e1-e13. DOI: 10.1016/S1473-3099(17)30398-5 Accessed: 11/28/2020.
- ENLOW, D.; HANS, M. *Noções básicas sobre crescimento facial.* 1ª ed. São Paulo: Santos, 1998.
- FARIA JKC; FEITOSA ALF; CANUTO MSBC. Achados miofuncionais orofaciais em crianças com microcefalia. *Distúrb Comun.* V. 32(3): 462-469, September, 2020. DOI: <https://doi.org/10.23925/2176-2724.2020v32i3p462-469>. Accessed: 12/13/2020.

- França TLB, Medeiros WR, Souza NL, Longo E, Pereira SA, França TBO, Sousa KG. Growth and Development of Children with Microcephaly Associated with Congenital Zika Virus Syndrome in Brazil. *Int J Environ Res Public Health*. 2018 Sep 13;15(9):1990. doi: 10.3390/ijerph15091990.PMID: 30216976; PMCID: PMC6164092. Accessed: 11/28/2020.
- IBGE. Censo 2000. p. 1–28, 2000. Available at: <https://www.ibge.gov.br/censo/censomundo.shtm>. Accessed: May 28, 2020.
- INTERGROWTH-21st. Sobre INTERGROWTH-21st (Portuguese) • Available at: <https://intergrowth21.tghn.org/about/sobre-intergrowth-21st-portuguese/>. Accessed: May 28, 2020.
- LEWIS, A.; ROCHE, A.; WAGNER, B. Puberal sours in cranial base and mandible. Comparisons with individuals. *Angle Orthodontist*, v. 55, p. 17–30, 1985.
- Niemi P, Markkanen S, Helminen M, Rautiainen M, Katila MK, Saarenpää-Heikkilä O, Peltomäki T. Association between snoring and deciduous dental development and soft tissue profile in 3-year-old children. *Am J Orthod Dentofacial Orthop*. 2019 Dec;156(6):840-845. doi: 10.1016/j.ajodo.2019.02.015. PMID: 31784018. Accessed: 12/14/2020.
- Ribeiro RA, Mattos A, Meneghim MC, Vedovello SAS, Borges TMD, Santamaria M. Oral and maxillofacial outcomes in children with microcephaly associated with the congenital Zika syndrome. *Eur J Orthod*. 2020 Jun 11:cjaa036. doi: 10.1093/ejo/cjaa036. Epub ahead of print. PMID: 32524144. <https://doi.org/10.1093/ejo/cjaa036> Accessed: 12/14/2020.
- SILVA FILHO, O. G. et al. Padrão facial nadentaduradecídua: Estudo epidemiológico. *Revista Dental Press de Ortodontia e Ortopedia Facial*, v. 13, n. 4, p. 45–59, 2008.
- SILVA FILHO, O. Padrão facial do paciente portador de fissura pré-forame incisivo unilateral completa. *Rev Bras Cirurgia*, v. 79, p. 197–200, 1989.
- Traldi A, Valdrighi HC, de Souza LZ, Vedovello SA. Evaluation of facial morphology and sagittal relationship between dental arches in primary and mixed dentition. *Dental Press J Orthod*. 2015 Jul-Aug;20(4):63-7. doi: 10.1590/2176-9451.20.4.063-067.oar. PMID: 26352847; PMCID: PMC4593532. Accessed: 11/28/2020.
- VON ELM, E. et al. The Strengthening the Reporting of Observational Studies in Epidemiology (STROBE) Statement: Guidelines for reporting observational studies. *UroToday International Journal*, v. 2, n. 2, p. 806, 2009.
- WHO. WORLD HEALTH ORGANIZATION. Screening, assessment and management of neonates and infants with complications associated with Zika virus exposure in utero Interim guidance, 2016. Available at: <http://www.who.int/csr/resources/publications/zika/assessment-infants/en/> Accessed: 12/14/2020.
