

# RETINA<sup>®</sup> SPECIALIST

VOL. 8, NO. 6 • NOVEMBER/DECEMBER 2022

**Retina Update: A deeper dive into anti-VEGF loss to follow-up** Page 8

**Page 10 North of the Border: Top 10 OCT terms in vitreoretinal surgery**



## ANTI-VEGF FOR RVO: Real-world Outcomes

*Why they don't measure up to clinical trial results.*

**Page 20**

### **Also Inside**

- Sickle cell retinopathy: Update on management – **Page 28**
- Lessons from the MEAD study: The potential for reversing DR – **Page 32**
- How AI may impact retinal practice – **Page 36**

### **Online Video**

- Where are the women on retina podiums? – **Page 9**
- Handling a GORE-TEX-sutured IOL – **Page 16**

0.18 mg

YUTIQ®

(fluocinolone acetonide  
intraocular implant) 0.18 mg

# Discover continuous calm in uveitis<sup>1</sup>

YUTIQ is designed to deliver a sustained release of fluocinolone for up to 36 months for patients with chronic non-infectious uveitis affecting the posterior segment of the eye<sup>1</sup>

- **Proven to reduce uveitis recurrence at 6 and 12 months<sup>1\*</sup>**  
At 6 months—18% for YUTIQ and 79% for sham for Study 1 and 22% for YUTIQ and 54% for sham for Study 2 ( $P < .01$ ). At 12 months—28% for YUTIQ and 86% for sham for Study 1 and 33% for YUTIQ and 60% for sham for Study 2.
- **Extended median time to first recurrence of uveitis<sup>1,2</sup>**  
At 12 months—NE<sup>†</sup> for YUTIQ/92 days for sham in Study 1; NE for YUTIQ/187 days for sham in Study 2.
- **Mean intraocular pressure (IOP) increase was comparable to sham<sup>1,2</sup>**  
Study was not sized to detect statistically significant differences in mean IOP.

For more  
information, visit

[YUTIQ.com](http://YUTIQ.com)

\*Study design: The efficacy of YUTIQ was assessed in 2 randomized, multicenter, sham-controlled, double-masked, Phase 3 studies in adult patients (N=282) with non-infectious uveitis affecting the posterior segment of the eye. The primary endpoint in both studies was the proportion of patients who experienced recurrence of uveitis in the study eye within 6 months of follow-up; recurrence was also assessed at 12 months. Recurrence was defined as either deterioration in visual acuity, vitreous haze attributable to non-infectious uveitis, or the need for rescue medications.

<sup>†</sup>NE=non-evaluable due to the low number of recurrences in the YUTIQ group.

## INDICATIONS AND USAGE

YUTIQ® (fluocinolone acetonide intraocular implant) 0.18 mg is indicated for the treatment of chronic non-infectious uveitis affecting the posterior segment of the eye.

## IMPORTANT SAFETY INFORMATION

### CONTRAINDICATIONS

**Ocular or Periocular Infections:** YUTIQ is contraindicated in patients with active or suspected ocular or periocular infections including most viral disease of the cornea and conjunctiva including active epithelial herpes simplex keratitis (dendritic keratitis), vaccinia, varicella, mycobacterial infections and fungal diseases.

**Hypersensitivity:** YUTIQ is contraindicated in patients with known hypersensitivity to any components of this product.

### WARNINGS AND PRECAUTIONS

**Intraocular Injection-related Effects:** Intraocular injections, including those with YUTIQ, have been associated with endophthalmitis, eye inflammation, increased or decreased intraocular pressure, and choroidal or retinal detachments. Hypotony has been observed within 24 hours of injection and has resolved within 2 weeks. Patients should be monitored following the intraocular injection.

**Steroid-related Effects:** Use of corticosteroids including YUTIQ may produce posterior subcapsular cataracts, increased intraocular pressure and glaucoma. Use of corticosteroids may enhance the establishment of secondary ocular infections due to bacteria, fungi, or viruses. Corticosteroids are not recommended to be used in patients with a history of ocular herpes simplex because of the potential for reactivation of the viral infection.

**Risk of Implant Migration:** Patients in whom the posterior capsule of the lens is absent or has a tear are at risk of implant migration into the anterior chamber.

### ADVERSE REACTIONS

In controlled studies, the most common adverse reactions reported were cataract development and increases in intraocular pressure.

**Please see brief summary of full Prescribing Information on adjacent page.**

**References:** 1. YUTIQ® (fluocinolone acetonide intraocular implant) 0.18 mg full US Prescribing Information. EyePoint Pharmaceuticals, Inc. May 2021. 2. Data on file.



YUTIQ, the YUTIQ logo, and the EyePoint logo are registered trademarks of EyePoint Pharmaceuticals, Inc.  
©2021 EyePoint Pharmaceuticals, Inc. All rights reserved.  
480 Pleasant Street, Suite B300, Watertown, MA 02472

08/2021  
US-YUT-2100061

**YUTIQ® (fluocinolone acetonide intravitreal implant) 0.18 mg, for intravitreal injection**  
**Initial U.S. Approval: 1963**

**BRIEF SUMMARY: Please see package insert for full prescribing information.**

**1. INDICATIONS AND USAGE.** YUTIQ® (fluocinolone acetonide intravitreal implant) 0.18 mg is indicated for the treatment of chronic non-infectious uveitis affecting the posterior segment of the eye.

**4. CONTRAINDICATIONS. 4.1. Ocular or Periocular Infections.** YUTIQ is contraindicated in patients with active or suspected ocular or periocular infections including most viral disease of the cornea and conjunctiva including active epithelial herpes simplex keratitis (dendritic keratitis), vaccinia, varicella, mycobacterial infections and fungal diseases. **4.2. Hypersensitivity.** YUTIQ is contraindicated in patients with known hypersensitivity to any components of this product.

**5. WARNINGS AND PRECAUTIONS. 5.1. Intravitreal Injection-related Effects.** Intravitreal injections, including those with YUTIQ, have been associated with endophthalmitis, eye inflammation, increased or decreased intraocular pressure, and choroidal or retinal detachments. Hypotony has been observed within 24 hours of injection and has resolved within 2 weeks. Patients should be monitored following the intravitreal injection [see Patient Counseling Information (17) in the full prescribing information]. **5.2. Steroid-related Effects.** Use of corticosteroids including YUTIQ may produce posterior subcapsular cataracts, increased intraocular pressure and glaucoma. Use of corticosteroids may enhance the establishment of secondary ocular infections due to bacteria, fungi, or viruses. Corticosteroids are not recommended to be used in patients with a history of ocular herpes simplex because of the potential for reactivation of the viral infection. **5.3. Risk of Implant Migration.** Patients in whom the posterior capsule of the lens is absent or has a tear are at risk of implant migration into the anterior chamber.

**6. ADVERSE REACTIONS. 6.1. Clinical Studies Experience.** Because clinical trials are conducted under widely varying conditions, adverse reaction rates observed in the clinical trials of a drug cannot be directly compared to rates in the clinical trials of another drug and may not reflect the rates observed in practice. Adverse reactions associated with ophthalmic steroids including YUTIQ include cataract formation and subsequent cataract surgery, elevated intraocular pressure, which may be associated with optic nerve damage, visual acuity and field defects, secondary ocular infection from pathogens including herpes simplex, and perforation of the globe where there is thinning of the cornea or sclera. Studies 1 and 2 were multicenter, randomized, sham injection-controlled, masked trials in which patients with non-infectious uveitis affecting the posterior segment of the eye were treated once with either YUTIQ or sham injection, and then received standard care for the duration of the study. Study 3 was a multicenter, randomized, masked trial in which patients with non-infectious uveitis affecting the posterior segment of the eye were all treated once with YUTIQ, administered by one of two different applicators, and then received standard care for the duration of the study. Table 1 summarizes data available from studies 1, 2 and 3 through 12 months for study eyes treated with YUTIQ (n=226) or sham injection (n=94). The most common ocular (study eye) and non-ocular adverse reactions are shown in Table 1 and Table 2.

**Table 1: Ocular Adverse Reactions Reported in ≥ 1% of Subject Eyes and Non-Ocular Adverse Reactions Reported in ≥ 2% of Patients**

ADVERSE REACTIONS	Ocular	
	YUTIQ (N=226 Eyes) n (%)	Sham Injection (N=94 Eyes) n (%)
Cataract <sup>1</sup>	63/113 (56%)	13/56 (23%)
Visual Acuity Reduced	33 ( 15%)	11 (12%)
Macular Edema	25 ( 11%)	33 (35%)
Uveitis	22 ( 10%)	33 (35%)
Conjunctival Hemorrhage	17 ( 8%)	5 ( 5%)
Eye Pain	17 ( 8%)	12 (13%)
Hypotony Of Eye	16 ( 7%)	1 ( 1%)
Anterior Chamber Inflammation	12 ( 5%)	6 ( 6%)
Dry Eye	10 ( 4%)	3 ( 3%)
Vitreous Opacities	9 ( 4%)	8 ( 9%)
Conjunctivitis	9 ( 4%)	5 ( 5%)
Posterior Capsule Opacification	8 ( 4%)	3 ( 3%)
Ocular Hyperemia	8 ( 4%)	7 ( 7%)
Vitreous Haze	7 ( 3%)	4 ( 4%)
Foreign Body Sensation In Eyes	7 ( 3%)	2 ( 2%)
Vitritis	6 ( 3%)	8 ( 9%)
Vitreous Floaters	6 ( 3%)	5 ( 5%)
Eye Pruritus	6 ( 3%)	5 ( 5%)
Conjunctival Hyperemia	5 ( 2%)	2 ( 2%)
Ocular Discomfort	5 ( 2%)	1 ( 1%)
Macular Fibrosis	5 ( 2%)	2 ( 2%)
Glaucoma	4 ( 2%)	1 ( 1%)
Photopsia	4 ( 2%)	2 ( 2%)

(continued)

**Table 1: Ocular Adverse Reactions Reported in ≥ 1% of Subject Eyes and Non-Ocular Adverse Reactions Reported in ≥ 2% of Patients**

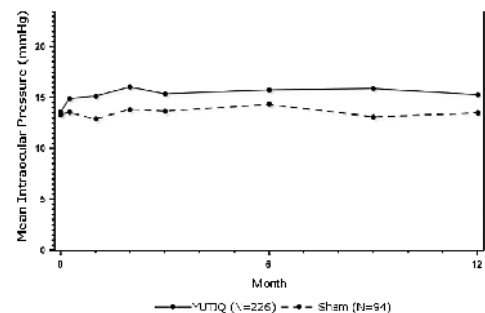
ADVERSE REACTIONS	Ocular	
	YUTIQ (N=226 Eyes) n (%)	Sham Injection (N=94 Eyes) n (%)
Vitreous Hemorrhage	4 ( 2%)	0
Iridocyclitis	3 ( 1%)	7 ( 7%)
Eye Inflammation	3 ( 1%)	2 ( 2%)
Choroiditis	3 ( 1%)	1 ( 1%)
Eye Irritation	3 ( 1%)	1 ( 1%)
Visual Field Defect	3 ( 1%)	0
Lacrimation Increased	3 ( 1%)	0
ADVERSE REACTIONS	Non-ocular	
	YUTIQ (N=214 Patients) n (%)	Sham Injection (N=94 Patients) n (%)
Nasopharyngitis	10 ( 5%)	5 (5%)
Hypertension	6 ( 3%)	1 ( 1%)
Arthralgia	5 ( 2%)	1 ( 1%)

1. Includes cataract, cataract subcapsular and lenticular opacities in study eyes that were phakic at baseline, 113 of the 226 YUTIQ study eyes were phakic at baseline; 56 of 94 sham-controlled study eyes were phakic at baseline.

**Table 2: Summary of Elevated IOP Related Adverse Reactions**

ADVERSE REACTIONS	YUTIQ (N=226 Eyes) n (%)	Sham (N=94 Eyes) n (%)
IOP elevation ≥ 10 mmHg from Baseline	50 (22%)	11 (12%)
IOP elevation > 30 mmHg	28 (12%)	3 (3%)
Any IOP-lowering medication	98 (43%)	39 (41%)
Any surgical intervention for elevated IOP	5 (2%)	2 (2%)

**Figure 1: Mean IOP During the Studies**



**8. USE IN SPECIFIC POPULATIONS. 8.1 Pregnancy. Risk Summary.** Adequate and well-controlled studies with YUTIQ have not been conducted in pregnant women to inform drug associated risk. Animal reproduction studies have not been conducted with YUTIQ. It is not known whether YUTIQ can cause fetal harm when administered to a pregnant woman or can affect reproduction capacity. Corticosteroids have been shown to be teratogenic in laboratory animals when administered systemically at relatively low dosage levels. YUTIQ should be given to a pregnant woman only if the potential benefit justifies the potential risk to the fetus. All pregnancies have a risk of birth defect, loss, or other adverse outcomes. In the United States general population, the estimated background risk of major birth defects and miscarriage in clinically recognized pregnancies is 2% to 4% and 15% to 20%, respectively. **8.2 Lactation. Risk Summary.** Systemically administered corticosteroids are present in human milk and can suppress growth, interfere with endogenous corticosteroid production. Clinical or nonclinical lactation studies have not been conducted with YUTIQ. It is not known whether intravitreal treatment with YUTIQ could result in sufficient systemic absorption to produce detectable quantities of fluocinolone acetonide in human milk, or affect breastfed infants or milk production. The developmental and health benefits of breastfeeding should be considered, along with the mother's clinical need for YUTIQ and any potential adverse effects on the breastfed child from YUTIQ. **8.4 Pediatric Use.** Safety and effectiveness of YUTIQ in pediatric patients have not been established. **8.5 Geriatric Use.** No overall differences in safety or effectiveness have been observed between elderly and younger patients.

Manufactured by:  
 EyePoint Pharmaceuticals US, Inc., 480 Pleasant Street, Watertown, MA 02472 USA  
 Patented.



# RETINA SPECIALIST

19 Campus Blvd., Suite 101  
Newtown Square, PA 19073  
Telephone (610) 492-1000  
Fax (610) 492-1039

Editorial inquiries (610) 492-1000  
Advertising inquiries (610) 492-1011  
E-mail [retinaspecialist@jobson.com](mailto:retinaspecialist@jobson.com)

## EDITORIAL STAFF

### EDITOR-IN-CHIEF

Walter Bethke  
[wbethke@jobson.com](mailto:wbethke@jobson.com)

### CHIEF MEDICAL EDITOR

Charles C. Wykoff, MD, PhD  
[ccwmd@houstonretina.com](mailto:ccwmd@houstonretina.com)

### EDITOR

Richard Mark Kirkner  
[rkirkner@jobson.com](mailto:rkirkner@jobson.com)

### SENIOR ART DIRECTOR

Jared Araujo  
[jaraujo@jhihealth.com](mailto:jaraujo@jhihealth.com)

### GRAPHIC DESIGNER

Lynne O'Connor  
[lyoconnor@webmd.net](mailto:lyoconnor@webmd.net)

### AD PRODUCTION MANAGER

Karen Lallone  
[klallone@jobson.com](mailto:klallone@jobson.com)

## EDITORIAL BOARD

Ashkan M. Abbey, MD, Dallas  
David R.P. Almeida, MD, PhD, MBA, Erie, Pa.  
Caroline R. Baumal, MD, Boston  
Lisa Olmos de Koo, MD, MBA, Seattle  
Justis P. Ehlers, MD, Cleveland  
Avni P. Finn, MD, MBA, San Jose, Calif.  
Mrinali Gupta, MD, Newport Beach, Calif.  
Paul Hahn, MD, PhD, Teaneck, N.J.  
Jason Hsu, MD, Philadelphia  
Amir Kashani, MD, Baltimore  
Efreem D. Mandelcorn, MD, FRCS, Toronto  
Jonathan L. Prenner, MD, Edison, N.J.  
Carl D. Regillo, MD, FACS, Philadelphia  
Philip J. Rosenfeld, MD, PhD, Miami  
Akshay S. Thomas, MD, MS, Nashville, Tenn.

## EDITORIAL CONTRIBUTORS

Kevin J. Blinder, MD, St. Louis  
Alyssa C. Bonnell, MD, Seattle  
Yavuz Cakir, MD, Cleveland  
Michael N. Cohen, MD, Philadelphia  
Carl J. Danzig, MD, Boca Raton, Fla.  
Justis P. Ehlers, MD, Cleveland  
Tina Felfeli, MD, Toronto  
Michael Grinton, MD, FRCOphth, Toronto  
Arshad Khanani, MD, Reno, Nev.  
K. Matthew McKay, MD, Seattle  
Bhadra U. Pandya, Toronto  
Adrienne W. Scott, MD, Baltimore  
Abdulla Shaheen, MD, Miami  
Meera D. Sivalingam, MD, Philadelphia  
Loka Thangamathesvaran, MD, Baltimore  
Maxwell J. Wingelaar, MD, St. Louis



Jobson Medical Information

# What's in a number?

It's the age-old beauty of perspective. Is your glass half-full or half-empty?

One in 43 eyes, or 2.3 percent. That's the proportion of patients with a Port Delivery System with ranibizumab (Susvimo) who had a septum dislodgement, according to a provider letter from Genentech/Roche. Most of those incidents came in the context of a refill-exchange procedure.

Along with data from a simulated aging analysis that showed the risk of septum dislodgement may increase with additional refill-exchanges, Genentech/Roche decided to voluntarily recall the device.

I've implanted dozens of these into patients with a variety of exudative retinal diseases in multiple clinical trial programs. The majority are very happy with their outcomes.

But, what percentage of unwanted outcomes is too high? Since the recall, most of these patients have chosen to delay additional refill-exchanges as long as possible to theoretically extend the life-span of the device.


Different patients and physicians can view the same risk-benefit ratio quite differently. For example, in the OAKS and DERBY Phase III trials, we observed a 12.2 percent rate of exudative age-related macular degeneration development with monthly pegcetacoplan compared to 3.1 percent with sham through two years.<sup>1</sup> Is this risk too high?

Some physicians, myself included, believe that, in the absence of any other treatment, most patients will accept a potential side effect of wet AMD during treatment of geographic atrophy, knowing we can monitor and treat them as needed.

However, some physicians believe this risk profile, combined with the modest treatment effect of 16 to 22 percent reduction in GA growth through two years, may not be worth the benefit. With the Food and Drug Administration action date for pegcetacoplan set for early next year, it will be interesting to see how providers and patients interpret this risk-benefit ratio.

Artificial intelligence, as Yavuz Cakir, MD, and Justis P. Ehlers, MD, explore on page 36, may eventually help us determine which patients may benefit most from pharmacotherapy for GA and who may be most likely to develop exudative AMD.

Similarly, differences in perspective can lead to different approaches to rhegmatogenous retinal detachment repair.<sup>2</sup> If two approaches achieve the same visual acuity outcome but one has a higher single-operation success rate while requiring more time and longer patient recovery, which would you choose? Which would your patient choose? Some surgeons are inclined to add a scleral buckle. Others see a large number needed to treat and decide against the hassle and increased recovery time. Same data; different applications.

How numbers impact your practice may depend on your perspective. 

## REFERENCES

- Wykoff CC. Treatment of Geographic atrophy secondary to AMD with pegcetacoplan: Two-year outcomes from the randomized Phase 3 DERBY and OAKS Trials. Paper presented at American Academy of Ophthalmology Retina Subspecialty Day, Session RET10; Chicago, IL; September 30, 2022.
- Ryan EH, Mittra RA. Surgeon judgment and the role of scleral buckle in addition to vitrectomy in eyes with retinal detachments. *Ophthalmol Retina*. 2022;6:869.

WET AMD EYE

## ANTI-VEGF

Therapy yields better long-term VA results when wet AMD detected with good VA<sup>1</sup>

FELLOW EYE

## 20/79 VA

Mean VA of fellow eyes at wet AMD diagnosis according to real-world data<sup>1</sup>

# Over 60% of wet AMD “fellow eyes” lose too much vision<sup>1</sup>— even with frequent treatment visits

## Detect Early. Treat Early.

ForeseeHome is a **remote monitoring** program for at-risk wet AMD fellow eyes that helps **detect conversion** at 20/40 or better in 83% of patients.<sup>2</sup>

- ✓ FDA Cleared
- ✓ Medicare Covered

ForeseeHOME™  
AMD Monitoring Program



Introduce your patients to ForeseeHome during an injection visit and offer them an extra level of protection.

Our Monitoring Center works with your staff to easily implement an “inject and protect” protocol into your practice workflow that requires minimal effort or additional time.

## The Key to Successful Home Monitoring

NOTAL VISION MONITORING CENTER



Engagement & Education

Benefits Verification & Authorization

Continuous Monitoring



Practice Workflow Implementation

Remote Patient Management

Vision Alert Management



ForeseeHome is a registered trademark, and the ForeseeHome AMD Monitoring Program and logo and the Notal Vision logo are trademarks of Notal Vision. © 2021 Notal Vision, Inc. All rights reserved.

References: 1. Ho AC, Kleinman DM, Lum FC, et al. Baseline Visual Acuity at Wet AMD Diagnosis Predicts Long-Term Vision Outcomes: An Analysis of the IRIS Registry. *Ophthalmic Surg Lasers Imaging Retina*. 2020;51:633-639. 2. Real-World Performance of a Self-Operated Home Monitoring System for Early Detection of Neovascular AMD (ForeseeHome device), presented by Allen Ho, American Society of Retina Specialist Meeting 2020.

See website for FDA Indication for Use.

SM-125. 2



GET STARTED TODAY

1-855-600-3112

Mon-Fri, 8 AM to 6 PM EST

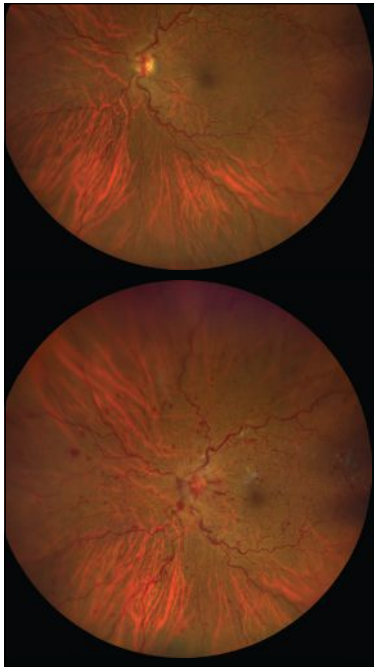
[www.foreseehome.com/doctor](http://www.foreseehome.com/doctor)

A PUBLICATION BY **REVIEW**  
OF OPHTHALMOLOGY

# RETINA SPECIALIST

NOVEMBER/DECEMBER 2022 • VOL. 8, NO. 6

## FEATURES



**20**  
**Anti-VEGF for RVO:  
A look at real-world  
results**  
They don't necessarily align with what clinical trials have reported, pointing to a need for more durable therapies.  
**By Abdulla Shaheen, MD, and  
Carl J. Danzig, MD**

**28**  
**Sickle cell retinopathy: An update on management**

Laser photocoagulation is the gold standard, but adjunct anti-VEGF and systemic therapies may help improve retinopathy.

**By Loka Thangamathesvaran, MD, and Adrienne W. Scott, MD**

**32**  
**Lessons from MEAD: The potential for reversing DR**

The dexamethasone implant has shown efficacy in DME, but recent evidence shows a signal for treating diabetic retinopathy.

**By Maxwell J. Wingelaar, MD, and Kevin J. Blinder, MD**

**36**  
**How AI may impact retinal practice**

Artificial intelligence has shown potential for helping us to manage the multitudes with geographic atrophy and diabetes.

**By Yavuz Cakir, MD, and Justis P. Ehlers, MD**

## DEPARTMENTS

**4** **Editor's Page**

What's in a number?

**By Charles C. Wykoff, MD, PhD**

**8** **Retina Update**



Online Video

A deeper dive into loss to follow-up; Where are women on retina podiums?

**10** **North of the Border**

Top 10 OCT terms for vitreoretinal surgery

**Edited by Efrem Mandelcorn, MD, FRCSC**

**13** **Retina Rounds**

Can we spare the OR?

**Edited by Lisa C. Olmos deKoo, MD, MBA**

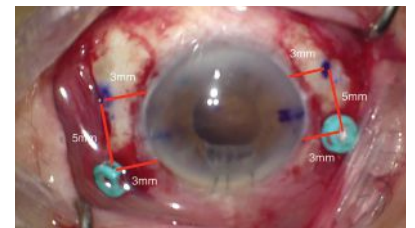
**16** **Surgical Pearl Video**



Online Video

Handling a GORE-TEX-sutured IOL

**Edited by Paul Hahn, MD, PhD**



**40** **Social Media Specialist**

Climate change and social media

**By David R.P. Almeida, MD, MBA, PhD**

**41** **Conference Review**

AAO highlights: ILM peel in DR

and more

**By Avni P. Finn, MD, MBA**

**44** **Clinical Trial Closeup**

Axitinib implant shows early

potential for treating nAMD

**Edited by Richard Mark Kirkner**



IVERIC  
BIO

DEVELOPING  
TRANSFORMATIVE  
THERAPIES  
FOR RETINAL DISEASES

---

We are focused on developing treatments for patients suffering from retinal diseases with significant unmet medical needs.

**Geographic Atrophy | Stargardt Disease | Inherited Retinal Diseases**

Learn more at [IvericBio.com](https://IvericBio.com)

## A deeper dive into anti-VEGF loss to follow-up: Study identifies risk factors

An analysis of almost 200,000 patients undergoing treatment with anti-VEGF drugs for neovascular age-related macular degeneration is the largest study to date of why some don't come back for injections and potentially the first to identify risk factors for what's known as loss to follow-up.<sup>1</sup>

Raul Khurana, MD, of Northern California Retina Vitreous Associates in Mountain View, presented the study at the American Academy of Ophthalmology Retina Subspecialty Day.

A previous study found that loss to follow-up (LTFU) rates were 22 percent.<sup>2</sup> "That's very alarming and that's why we did the analysis," Dr. Khurana tells *Retina Specialist*.

"What was interesting is, we did find risk factors for it," Dr. Khurana says.

### Study design and findings

The study used the IRIS (Intelligent Research in Sight) registry to evaluate follow-up and treatment in 553,722 patients diagnosed with nAMD from 2013 through 2015, 191,694 of whom had received anti-VEGF treatments through 2018.

LTFU was defined as not returning for a visit more than 12 months after the last intravitreal injection. Overall, 11 percent of the patients were considered loss to follow-up.

"We found things such as advancing age, as patients above the age of 75 had a higher chance of being loss to follow-up," Dr. Khurana says. The rates rose steadily after age 76, with highest rates among patients age 90 years and older; they were three times more likely to miss appointments (overall risk 2.95,  $p < 0.001$ ).

"We found that patients who had unilateral disease were 2.5 times more likely to be loss to follow-up than those who had bilateral disease," Dr. Khurana adds ( $p < 0.001$ ).

The study also found men were more likely to be LTFU, as were Latinos and African Americans than White patients.

"Our hope is that by identifying these patients earlier we can hopefully find a better way of having them maintain their care," Dr. Khurana says.

### Expert comment

Jason Hsu, MD, co-author of the previous study Dr. Khurana cited,

notes that the rate this study found was half what his group reported.

"It makes sense given the IRIS registry is generally able to track patients if they move from one practice to another as long as the other practice is part of the registry," Dr. Hsu says in submitted comments. "The fact that one in nine patients will get an injection and not return for a year or more emphasized the fact that we still have a long way to go to improve treatment adherence and outcomes."

Dr. Khurana disclosed relationships with Genentech/Roche, Apellis, Chengdu Kanghong Pharmaceuticals Group, Clearside Biomedical, EyePoint Pharmaceuticals, Opthea and Regeneron. Dr. Hsu disclosed relationships with Gyroscope Therapeutics, Iveric bio, Bausch + Lomb, OccuRx, Genentech/Roche and Aldreyra Therapeutics.

### REFERENCES

1. Khurana RN, Li C, Lum F. Loss to follow up in patients with neovascular AMD treated with anti-VEGF therapy in the United States. Poster 337 presented at the American Academy of Ophthalmology, Retina Subspecialty Day, Chicago, IL; September 30, 2022.
2. Obeid A, Gao X, Ali FS, et al. Loss to follow-up among patients with neovascular age-related macular degeneration who received intravitreal anti-vascular endothelial growth factor injections. *JAMA Ophthalmol*. 2018;136:1251-1259.

### IN BRIEF

**Apellis Pharmaceuticals** has submitted an amended New Drug Application (NDA) for **pegcetacoplan**, resulting in a delay for the drug's Prescription Drug User Fee Act (PDUFA) action date from November 26 to February next year. Pegcetacoplan is an investigative drug to treat geographic atrophy in age-related macular degeneration.

**Outlook Therapeutics** reports that the Food and Drug Administration has accepted its Biologics License Application for **ONS-5010/Lytenava**, an investigational ophthalmic formulation of bevacizumab.

The FDA set a PDUFA date of August 29, 2023.

**Iveric bio** has submitted to the FDA the first part of its NDA for a rolling review of **avacincaptad pegol (Zimura)**, its complement factor 5 (C5) inhibitor for the treatment of GA secondary to AMD. The drug candidate already has FDA Fast Track designation.

The FDA has granted **Regeneron Pharmaceuticals** pediatric exclusivity for **Eylea** (afibercept) that extends the period of U.S. market exclusivity an additional six months through May 17, 2024. Regeneron says the determination is based on data from two Phase III trials in retinopathy of prematurity in preterm infants.



# Where are the women in retina? Not at the podium, study reports

**W**omen ophthalmologists have been underrepresented as speakers and presenters at professional meetings, but among ophthalmology subspecialties, retina lags behind most others in the proportion of women to men speakers.

And since COVID-19, the disparity has worsened, according to a retrospective analysis of 50 ophthalmology conferences with almost 8,000 speakers presented at the American Academy of Ophthalmology.<sup>1</sup>

“We looked at keynote speakers, panel moderators and paper presenters and there was a statistically significant large difference between men presenters and women presenters in each of these categories,” lead study author Seema Emami, MD, senior ophthalmology resident at the University of Toronto, tells *Retina Specialist*.

The study evaluated conferences all over the world and found the disparity in every region and every subspecialty except for pediatric and neuro-ophthalmology. “So it was quite pervasive,” she says.

The study reviewed the largest ophthalmic conferences across eight subspecialties and nine regions in 2020 and 2021, identifying speaker gender by pronouns used in speaker biographies or by first name or photograph. It identified gender in 99 percent of 7,964 speakers.

## Disparities at retina podiums

Overall, men held 67 percent of the speaking roles. Nearly half of speaker panels had 70 percent men or greater. Women comprise about 40 percent of ophthalmology trainees in North America, Dr. Emami adds.

## View the Video

Seema Emami, MD, discusses her study into women's representation on ophthalmology conference programs. Available at: <https://bit.ly/RetSpecMag-2022-06>




“In retina in particular, over 72 percent of speakers identified as men compared with over 34 percent women ( $p < 0.0001$ ),” Dr. Emami says.

Retina also had the highest percentage of all-men panels across all subspecialties, 22.3 percent compared with 12.6 percent for ophthalmology overall. Only seven of 966 conference sessions in ophthalmology were all-women, a rate of 0.7 percent.

Dr. Emami notes that from 2010 to 2019, the trend for more women on speakers' panels was moving upward, but then derailed in 2020 with the pandemic, with 26 percent of speakers being women. In 2021 that overall percentage rebounded to 33.8 percent.

“Having women on the ophthalmic podium is really integral to allowing them to continue to reach greater heights and to participate in ophthalmic leadership and ophthalmic societies as they participate in more research and presentations,” Dr. Emami says. “It increases the number of women who are going to be considered for ophthalmic awards.”

Dr. Emami has no relevant relationships to disclose. 

## REFERENCE

1. Emami S, Qian J, Bakshi. Striving towards gender diversity at the ophthalmic podium: How close are we to achieving parity? Poster 220 presented at the American Academy of Ophthalmology, Retina Subspecialty Day; Chicago, IL; September 30, 2022.

# RETINA SPECIALIST

## BUSINESS OFFICES

19 CAMPUS BOULEVARD, SUITE 101  
NEWTOWN SQUARE, PA 19073  
SUBSCRIPTION INQUIRIES (877) 529-1746  
(USA ONLY); OUTSIDE USA, CALL (847) 763-9630

## BUSINESS STAFF

PUBLISHER  
**MICHAEL HOSTER**  
(610) 492-1028 MHOSTER@JOBSON.COM

SALES MANAGER, STRATEGIC ACCOUNTS  
**MICHELE BARRETT**  
(610) 492-1014 MBARRETT@JOBSON.COM

REGIONAL SALES MANAGER  
**JONATHAN DARDINE**  
(610) 492-1030 JDARDINE@JOBSON.COM

## CLASSIFIED ADVERTISING

(888)-498-1460

PRODUCTION MANAGER  
**KAREN LALLONE**  
(610) 492-1010 KLALLONE@JOBSON.COM

## SUBSCRIPTIONS

US ONE YEAR: \$63.00  
CANADIAN ONE YEAR: \$99.00  
FOREIGN ONE YEAR: \$158.00  
SUBSCRIPTIONS E-MAIL:  
**SUBSCRIPTIONS@MEDGE.COM**

## CIRCULATION

RETINA SPECIALIST  
10255 W HIGGINS ROAD, SUITE 280  
ROSEMONT, IL 60018.

DIRECTOR, CIRCULATION  
**JARED SONNERS**  
jsonners@medge.com

CEO, INFORMATION GROUP SERVICES  
**MARC FERRARA**

SENIOR VICE PRESIDENT, OPERATIONS  
**JEFF LEVITZ**

VICE PRESIDENT, HUMAN RESOURCES  
**TAMMY GARCIA**

VICE PRESIDENT, CREATIVE SERVICES & PRODUCTION  
**MONICA TETTAMANZI**

SENIOR CORPORATE PRODUCTION DIRECTOR  
**JOHN ANTHONY CAGGIANO**

DIRECTOR, CIRCULATION  
**JARED SONNERS**



Jobson Medical Information LLC,  
395 Hudson Street, 3rd Floor, New York, NY 10014

# Top 10 OCT terms for vitreoretinal surgery

*A review of must-know optical coherence tomography nomenclature for the vitreoretinal surgical practice.*

**By Bhadra U. Pandya, Tina Felfeli, MD, Michael Grinton, MD, FRCOphth, and Efrem D. Mandelcorn, MD, FRCSC**



**Bhadra U. Pandya**



**Tina Felfeli, MD**



**Michael Grinton, MD, FRCOphth**



**Efrem D. Mandelcorn, MD, FRCSC**

## Bios

**Mr. Pandya** is a medical student at the University of Toronto.

**Dr. Felfeli** is an ophthalmology resident at the University of Toronto.

**Dr. Grinton** is a medical retina fellow at University Health Network, Toronto.

**Dr. Mandelcorn** is an associate professor of ophthalmology at the University of Toronto.

**DISCLOSURES:** The authors have no relevant financial disclosures.

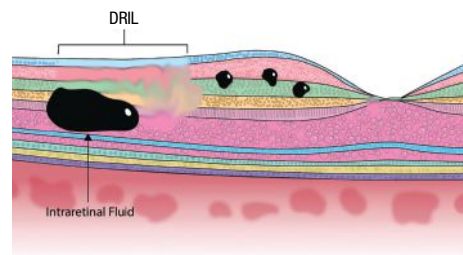
**O**ptical coherence tomography has evolved considerably over the last decades and the literature in that time has described many distinct OCT terminologies. In addition to serving a significant diagnostic role, OCT can enable better prognostication of patient outcomes and also inform operative decision-making.

A good understanding of OCT patterns is essential in vitreoretinal practice where what we see on OCT may guide our surgical decision-making. Here, we summarize the top 10 OCT terminologies that are relevant in the context of vitreoretinal surgery.

## 1. Disorganization of retinal inner layers (DRIL)

DRIL is an OCT pattern that involves the inner nuclear layer, outer plexiform layer (OPL) and ganglion cell-inner plexiform layer complex (*Figure 1*). Specifically, OCT can't clearly distinguish the boundaries of the aforementioned layers.<sup>1</sup>

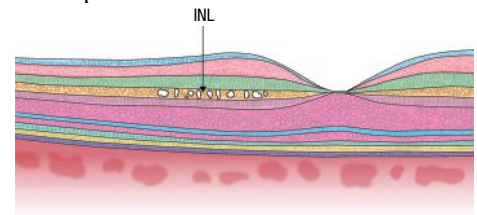
Greater DRIL extent in patients with epiretinal membrane has been associated with poorer outcomes following pars plana vitrectomy, which we should take into consideration when we're discussing the visual prognosis in patients undergoing ERM surgery.<sup>2</sup>



**Figure 1. Disorganization of retinal inner layers (DRIL), characterized by the spot of intraretinal fluid. (Images by the authors except where noted)**

## 2. INL microcysts

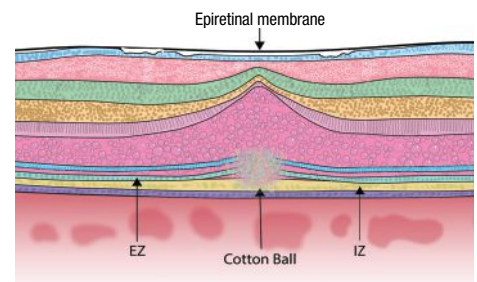
INL microcysts (*Figure 2*) are cystic, hyporeflective spaces generally observed in the INL in eyes affected with conditions such as ERM that result in macular edema.<sup>3</sup> The formation of INL microcysts following ERM peel is common and predicts poor postoperative visual outcomes. Additionally, unlike cystoid macular edema, INL microcysts don't respond to intravitreal steroids and shouldn't be treated in patients with these findings following ERM peel.<sup>4</sup>



**Figure 2. Inner nuclear layer microcysts, shown as white debris in the orange INL.**

## 3. Cotton ball sign (CBS)

CBS (*Figure 3*) is a round, hyperreflective region that's observed between the interdigitation zone (IZ) and ellipsoid zone.<sup>5</sup> The presence of CBS is strongly associated with ERM presence and vitreomacular traction. Importantly, when the tractional forces on the fovea are released, the CBS is no longer observable on OCT.<sup>5</sup>



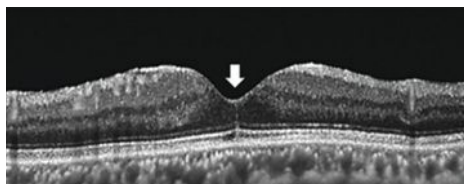
**Figure 3. Cotton ball sign appears as a round, hyperreflective region between the ellipsoid zone (EZ, lowest blue layer) and interdigitation zone (IZ, yellow layer toward bottom).**

CBS may predict future decline in visual acuity because it indicates significant foveal traction. However, the presence of CBS doesn't necessarily mean that the patient has poor visual acuity because this pattern can be observed in patients with relatively good VA.<sup>5</sup>

#### 4. Foveal crack sign (FCS)

FCS (Figure 4) appears on OCT as a vertical, hyperreflective line in the foveola.<sup>6</sup> Clinicians should be aware of this sign because it's uniquely associated with macular hole formation following PPV for rhegmatogenous retinal detachment. Specifically, Tomoyuki Ishibashi, MD, and colleagues in Japan observed FCS in 100 percent of eyes that developed a secondary macular hole following PPV for RRD.<sup>6</sup>

They observed FCS on OCT at  $255 \pm 217$  days following PPV, and macular hole development at  $232 \pm 171$  days following FCS appearance, indicating that these patients should be followed longer term following RD repair.

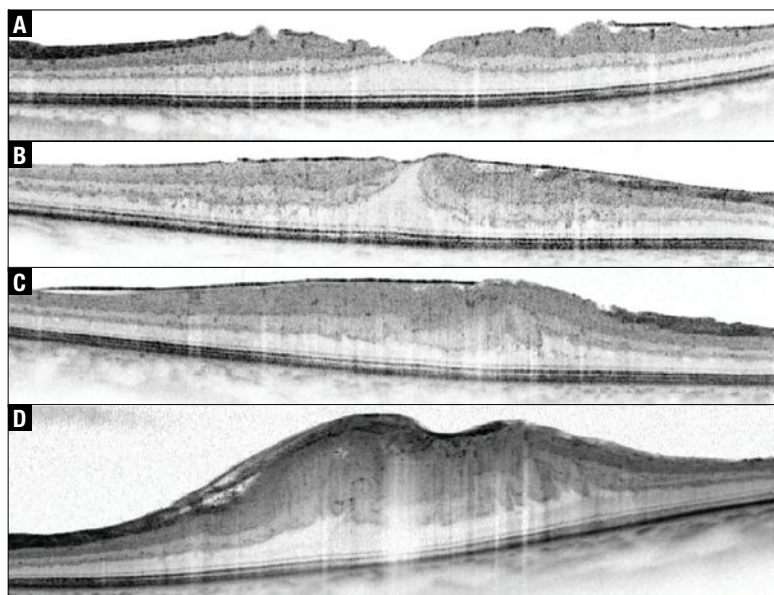


**Figure 4.** Foveal crack sign manifests as a vertical, hyperreflective line in the foveola (arrow). (From: Ishibashi T, Iwama Y, Nakashima H, Ikeda T, Emi K. Foveal crack sign: An OCT sign preceding macular hole after vitrectomy for rhegmatogenous retinal detachment. *Am J Ophthalmol.* 2020;218:192-198. Used with permission.)

#### 5. Epiretinal membrane staging

Andrea Govetto, MD, and colleagues were the first to offer a standardized, OCT-based description of the relevant ERM stages.<sup>7</sup> Clinically speaking, this classification system is useful in assessing overall severity and prognosticating patient outcomes. The stages are:

- **Stage 1.** In this stage, ERM (Figure 5A), the foveal depression is generally



**Figure 5.** The four stages of epiretinal membrane: A) stage 1; B) stage 2; C) stage 3; and D) stage 4. (From: Govetto A, Lalane RA 3rd, Sarraf D, Figueroa MS, Hubschman JP. Insights into epiretinal membranes: Presence of ectopic inner foveal layers and a new optical coherence tomography staging scheme. *Am J Ophthalmol.* 2017;175:99-113. Used with permission.)

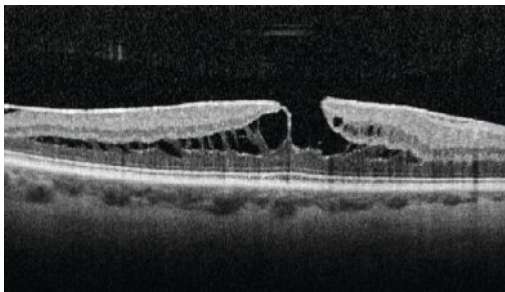
preserved. Additionally, the individual retinal layers are preserved and can be distinguished easily.

- **Stage 2.** The retinal layers can still be readily distinguished in this stage (Figure 5B). However, the foveal depression isn't present and the ONL is commonly widened.
- **Stage 3.** This stage (Figure 5C) is characterized by the absence of the foveal depression and presence of well-defined layers of the retina. However, the presence of ectopic inner foveal layers (EIFL) is a central feature of stage 3 ERM. EIFL is associated with worse outcomes following PPV in patients with ERM.<sup>8</sup>
- **Stage 4.** Stage 4 ERM (Figure 5D) retains the same features as stage 3 (absence of foveal depression, EIFL), with one key exception: the retinal layers can't be determined as clearly as they can in DRIL. Also, retinal thickening is typically observed in stage 4. As these ERM stage progress, postop-

erative outcomes tend to be poorer as the macular architecture continues to worsen (e.g., EIFL presence). Ultimately, the decision to operate will depend on several factors, such as ERM stage, preoperative VA and degree of metamorphopsia.

### 6. Tractional lamellar hole

Tractional lamellar holes (Figure 6) form when the OPL and ONL separate.



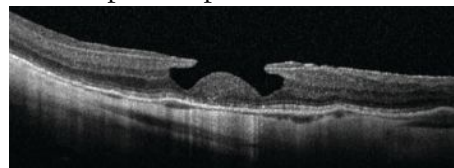
**Figure 6. Tractional lamellar hole, readily identifiable by its moustache-like appearance. (From: Govetto A, Dacquay Y, Farajzadeh M, et al. Lamellar macular hole: Two distinct clinical entities? Am J Ophthalmol. 2016;164:99-109. Used with permission.)**

On OCT, this pattern can be readily identified due to its moustache-like appearance. Tractional lamellar holes are typically observed in eyes with ERM and VMT.<sup>9</sup> Vision is generally good despite the presence of tractional lamellar hole,<sup>9</sup> likely because the photoreceptor-RPE interface isn't disturbed.

### 7. Degenerative lamellar hole

Several features characterize degenerative lamellar holes (Figure 7), including a central cavitation that may involve the layers of the outer retina, foveal bump, and EZ disruption.

In contrast to the moustache-like appearance of tractional lamellar holes, degenerative lamellar holes have a top-hat like appearance. Most degenerative lamellar holes are also associated with the presence of epiretinal proliferation.<sup>9</sup> Similar to

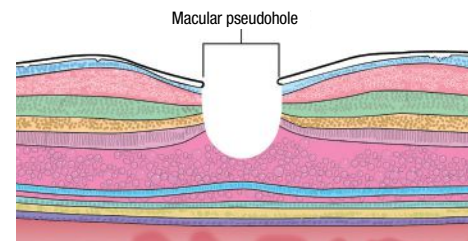


**Figure 7. Degenerative lamellar hole, characterized by central cavitation. (From: Govetto A, Dacquay Y, Farajzadeh M, et al. Lamellar macular hole: Two distinct clinical entities? Am J Ophthalmol. 2016;164:99-109. Used with permission.)**

tractional lamellar holes, these cases are often observed.

### 8. Macular pseudohole

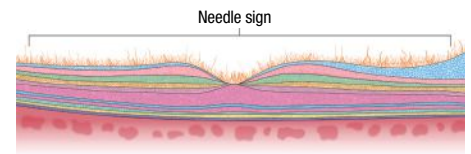
The main features of macular pseudoholes (Figure 8) include fovea-sparing ERM, retinal thickening and vertical foveal edges.<sup>10,11</sup> The mechanism of macular pseudohole formation is thought to be due to centripetal ERM contraction.



**Figure 8. Macular pseudohole is thought to be due to centripetal epiretinal membrane contraction.**

### 9. Needle sign

Needle-shaped deposits on the retina surface characterize the needle sign (Figure 9). This sign is typically observed in eyes that have previously undergone PPV and, more rarely, in cases of ocular amyloidosis.<sup>12</sup>



**Figure 9. Needle sign, as evidenced by needle-shaped deposits on the retinal surface.**

### 10. Omega sign (II)

Retention of perfluorocarbon (PFCL) bubbles following PPV can lead to the subsequent accumulation of PFCL in the subretinal space. This can result in a bubble with a dome-shaped appearance, called the omega sign (Figure 10, page 15).

If this occurs in the subfoveal space, the PFCL should be removed to avoid long-term damage to the photoreceptors.<sup>13</sup>

(Continued on page 15)



# Can we spare the OR?

*A case and discussion of macular hole management with medical therapy.*

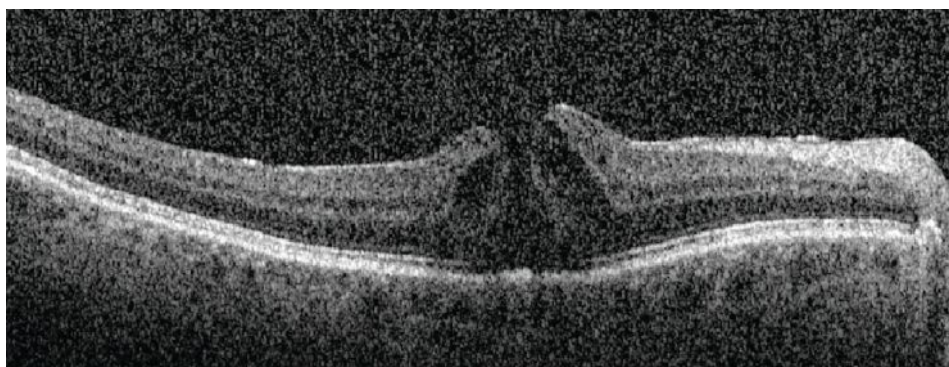
**A**n 83-year-old male presented to the emergency department for evaluation of a central scotoma in the right eye for one day. He reported that, before the symptoms came on, he had applied pressure to the right globe with his finger. When he removed his finger, he noticed that there was a dark, flower-shaped spot in the center of his vision in that eye.

## Examination findings and work-up

Best corrected visual acuity was 20/70 in the right eye and 20/20 in the left. His pupils were equal and reactive without a relative afferent pupillary defect, and intraocular pressures were within normal limits in each eye.

The slit lamp examination was notable for a posterior vitreous detachment in both eyes. A dilated fundus examination revealed a small, full-thickness macular hole in the right eye.

Optical coherence tomography of the macula in the right eye revealed an absent hyaloid face (*Figure 1*). Notably, there was a small, full-thickness macular hole in the right eye, measuring 193  $\mu\text{m}$ . Cystic intraretinal fluid collected at the edges of the hole.



**Figure 1.** Optical coherence tomography of the right eye at the time of presentation demonstrates an absent hyaloid face along with a small, full-thickness macular hole. Cystic intraretinal fluid had collected at the edges of the hole.

## Diagnosis

We diagnosed the patient with a full-thickness macular hole likely secondary to self-induced trauma following digital pressure on the globe.

## Management

The patient was referred to the retina service for a follow-up evaluation four weeks after the symptom first appeared. After this period of observation, best-corrected visual acuity remained 20/70 in the right eye and the macular hole persisted with an increase in the amount of IRF at the hole margins.

We considered three options: observation; medical treatment; and surgical intervention. Given the small size of the macular hole, the absence of vitreomacular traction and the presence of IRF at the hole margin, we decided to start medical treatment, prescribing topical ketorolac 0.5% q.i.d. in the right eye.

## Macular hole closure

We saw the patient again five weeks after starting treatment. At that visit, he reported an improvement in his symptoms. BCVA remained 20/70 in the right eye. Examination and OCT (*Figure 2, page 14*)

*By Alyssa C. Bonnell, MD,  
and K. Matthew McKay, MD*



Alyssa C. Bonnell,  
MD



K. Matthew  
McKay, MD

## BIOS

**Dr. Bonnell** is an ophthalmology resident at the University of Washington in Seattle.

**Dr. McKay** is a retina fellow at the University of Washington.

**Dr. Olmos de Koo** is an associate professor of ophthalmology and director of the retina fellowship program at the University of Washington.

**DISCLOSURES:** The authors have no relevant financial disclosures.

UW Medicine  
EYE INSTITUTE

determined the closure of the macular hole and resolution of the IRF with residual subretinal fluid. We told the patient to keep applying ketorolac q.i.d. in the right eye.

At the most recent follow-up appointment, 17 weeks after the patient started treatment, he remains on ketorolac at the same dose. BCVA is 20/30 in the right eye. The macular hole has remained closed. Persistent trace subretinal fluid continues to improve at each visit.

### Why Medical Therapy?

Vitreomacular traction has been thought to play a role in the development of macular holes for more than 30 years.<sup>1</sup> This theory has been widely accepted and supported by the fact that reducing traction on the retina with vitrectomy, with or without inner limiting membrane peeling or gas tamponade, has long been a successful treatment for macular holes.<sup>2</sup> In many cases, OCT imaging demonstrates the progression of vitreoretinal traction in the development of macular holes.<sup>3</sup>

However, some macular holes develop and persist in the absence of retinal traction.<sup>4</sup> In these cases, patients may have had vitrectomy previously or OCT didn't show evidence of vitreomacular traction in the affected eye. These observations have led

to a supplemental theory of macular hole formation: the hydration theory.<sup>5</sup>

The hydration theory of macular hole development surmises that IRF at the macular hole edges distorts the normal retinal architecture and precludes hole closure. By reducing this fluid, the hole edges can reapproximate and close.<sup>5,6</sup> Surgeons are now using medical therapies targeting this fluid before taking select patients to the operating room.

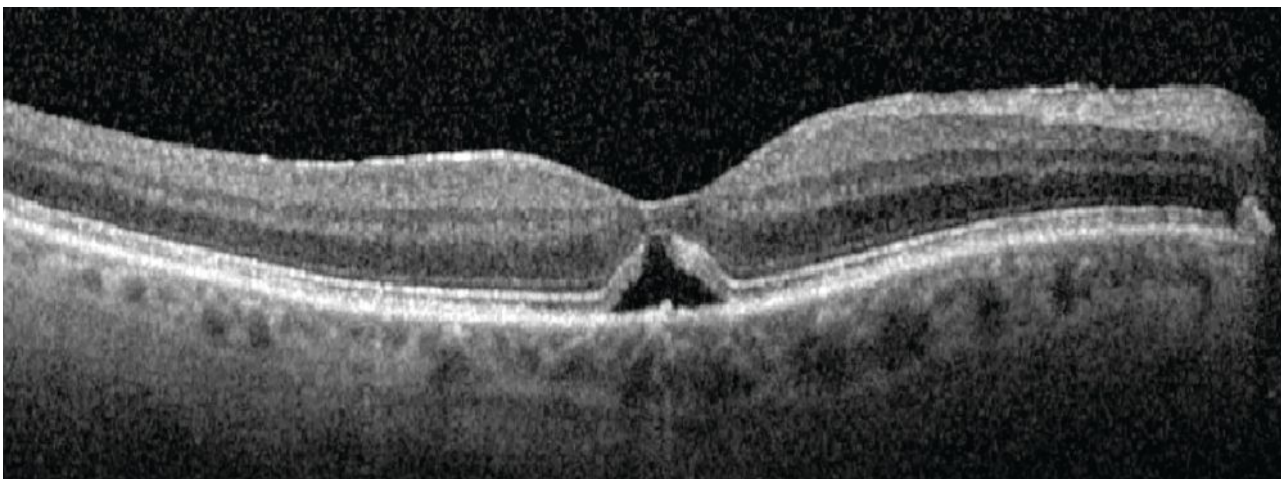
### Medication Selection

The literature on macular hole closure following medical therapy is growing. Authors have reported on the use of a variety of medical therapies and doses targeting macular edema.

Selected therapies include topical steroids and topical nonsteroidal anti-inflammatory drugs, including ketorolac, as we used in this case.<sup>6-10</sup> Other therapies include topical carbonic anhydrase inhibitors.<sup>11</sup>

### Considering a Therapeutic Effect

Macular holes have been known to close spontaneously. It's possible that our patient, and others reported in the literature, would have closed regardless of medical intervention. Spontaneous macular hole closure has



**Figure 2.** Five weeks after starting treatment with topical ketorolac, optical coherence tomography demonstrates macular hole closure and resolution of intraretinal fluid with persistent subretinal fluid.

been reported in 4 to 11.5 percent of cases.<sup>12</sup> Spontaneous closure is more likely in cases of small holes, especially smaller than 250 µm, without vitreomacular traction—again, as was the case for our patient.<sup>13</sup>

However, two reports have described a close association between treatment and macular hole status.<sup>7,8</sup> In both cases, patients demonstrated macular hole closure after topical NSAID and steroid exposure, respectively. What's interesting is that both cases had macular hole recurrence after the topical therapy was stopped, but then the holes closed again when the patients restarted the medications.

This relationship between medication exposure and macular hole status is interesting to consider, though not conclusive. We need prospective research to further elucidate this relationship.

### Bottom line

A growing number of reports have described a relationship between medical treatments targeting IRF and macular hole closure, including this case. A large selection of medications and doses have been tried and reported in the literature.

In light of these reports, hope is emerging that medical treatment for macular holes may offer patients comparable visual and anatomic outcomes to surgery but with reduced morbidity. However, at this time we lack the evidence to support this hypothesis. We need to prospectively study medical therapy in the management of macular holes to better understand this relationship. <sup>RS</sup>

### REFERENCES

1. Johnson RN, Gass JD. Idiopathic macular holes. Observations, stages of formation, and implications for surgical intervention. *Ophthalmology*. 1988;95:917-924.
2. Kelly NE, Wendel RT. Vitreous surgery for idiopathic macular holes. Results of a pilot study. *Arch Ophthalmol*. 1991;109:654-659.
3. Puliafito CA, Hee MR, Lin CP, et al. Imaging of macular diseases with optical coherence tomography. *Ophthalmology*. 1995;102:217-229.
4. Smiddy WE. Macular hole formation without vitreofoveal traction. *Arch Ophthalmol*. 2008;126:737-738.
5. Tornambe PE. Macular hole genesis: the hydration theory. *Retina*. 2003;23:421-424.
6. Gentile RC, Elliott D, Rosen RB, Benevento J, Reppucci VS, Izzzi R. The combined tractional-hydration theory of idiopathic macular holes. *Invest Ophthalmol Vis Sci*. 2015;56:4325.
7. Kurz PA, Kurz DE. Macular hole closure and visual improvement with topical nonsteroidal treatment. *Arch Ophthalmol*. 2009;127:1687-1688.
8. Bonnell AC, Prenner S, Weinstein MS, Fine HF. Macular hole closures with topical steroids. *Retin Cases Brief Rep*. 2022;16:351-354.
9. Gonzalez-Saldivar G, Juncal V, Chow D. Topical steroids: A non-surgical approach for recurrent macular holes. *Am J Ophthalmol Case Rep*. 2019;13:93-95.
10. Khurana RN, Wieland MR. Topical steroids for recurrent macular hole after pars plana vitrectomy. *Ophthalmol Retina*. 2018;2:636-637.
11. Sokol JT, Schechet SA, Komati R, et al. Macular hole closure with medical treatment. *Ophthalmol Retina*. 2021;5:711-713.
12. Yuzawa M, Watanabe A, Takahashi Y, Matsui M. Observation of idiopathic full-thickness macular holes: follow-up observation. *Arch Ophthalmol*. 1994;112:1051-1056.
13. Liang X, Liu W. Characteristics and risk factors for spontaneous closure of idiopathic full-thickness macular hole. *J Ophthalmol*. 2019;2019:4793764.

### Top 10 OCT terms for vitreoretinal surgery

(Continued from page 12)

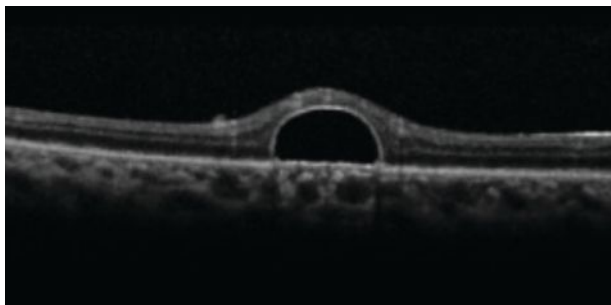


Figure 10. Omega sign, caused by retention of perfluorocarbon bubbles. (Courtesy Nicolas Yannuzzi, MD, and Jayanth Sridhar, MD)

### Bottom line

Here, we provide a brief summary of OCT terminology that vitreoretinal surgeons encounter in practice. We should be aware of these subtle changes on OCT to help us in deciding whether to offer surgery to patients. Understanding their nuances can help guide our surgical decision-making. <sup>RS</sup>

### REFERENCES

1. Sun JK, Lin MM, Lammer J, et al. Disorganization of the retinal inner layers as a predictor of visual acuity in eyes with center-involved diabetic macular edema. *JAMA Ophthalmol*. 2014;132:1309-1316.
2. Zur D, Iglicki M, Feldinger L, Schwartz S, Goldstein M, Loewenstein A, Barak A. Disorganization of retinal inner layers as a biomarker for idiopathic epiretinal membrane after macular surgery—The DREAM study. *Am J Ophthalmol*. 2018;196:129-135.
3. Brar M, Yuson R, Kozak I, et al. Correlation between morphologic features on spectral-domain optical coherence tomography and angiographic leakage patterns in macular edema. *Retina*. 2010;30:383-389.
4. Chen SJ, Tsai FY, Liu HC, Chung YC, Lin TC. Postoperative inner nuclear layer microcysts affecting long-term visual outcomes after epiretinal membrane surgery. *Retina*. 2016;36:2377-2383.
5. Tsunoda K, Watanabe K, Akiyama K, Usui T, Noda T. Highly reflective foveal region in optical coherence tomography in eyes with vitreomacular traction or epiretinal membrane. *Ophthalmology*. 2012;119:581-587.
6. Ishibashi T, Iwama Y, Nakashima H, Ikeda T, Emi K. Foveal Crack Sign: An OCT sign preceding macular hole after vitrectomy for rhegmatogenous retinal detachment. *Am J Ophthalmol*. 2020;218:192-198.
7. Govetto A, Lalane RA 3rd, Sarraf D, Figueroa MS, Hubschman JP. Insights into epiretinal membranes: Presence of ectopic inner foveal layers and a new optical coherence tomography staging scheme. *Am J Ophthalmol*. 2017;175:99-113.
8. Govetto A, Virgili G, Rodriguez FJ, Figueroa MS, Sarraf D, Hubschman JP. Functional and anatomical significance of the ectopic inner foveal layers in eyes with idiopathic epiretinal membranes: Surgical results at 12 months. *Retina*. 2019;39:347-357.
9. Govetto A, Dacquay Y, Farajzadeh M, et al. Lamellar macular hole: Two distinct clinical entities? *Am J Ophthalmol*. 2016;164:99-109.
10. Michalewski J, Michalewska Z, Dzgielewska K, Nawrocki J. Evolution from macular pseudohole to lamellar macular hole—Spectral domain OCT study. *Graefes Arch Clin Exp Ophthalmol*. 2011;249:175-178.
11. Hubschman JP, Govetto A, Spaide RF, et al. Optical coherence tomography-based consensus definition for lamellar macular hole. *Br J Ophthalmol*. 2020;104:1741-1747.
12. Kakiyama S, Hirano T, Matsuda Y, et al. Deposits on retinal surface seen on OCT in ocular amyloidosis. *Ophthalmol Retina*. 2021;5:1005-1008.
13. Figueroa MS, Contreras I. Characteristics of retained subretinal perfluoro-n-octane on optical coherence tomography. *Retina*. 2012;32:2177-2178.



# Handling a GORE-TEX-sutured IOL

*A review of key steps that will avoid suture twisting and lens tilt.*

By **Meera D. Sivalingam, MD, and Michael N. Cohen, MD**



Meera D. Sivalingam, MD



Michael N. Cohen, MD

**A**s retina specialists, we have several techniques for intraocular lens placement in eyes with poor capsular support. GORE-TEX-sutured intraocular lens fixation remains a steadfast method that has several advantages, including excellent stability, minimal risk of suture breakage and a small corneal wound through which the IOL can be inserted.<sup>1-3</sup>

Here, we review GORE-TEX-sutured IOL placement using the Bausch + Lomb enVista MX60 lens with four-point fixation and highlight key steps, and tricks to avoid common issues such as suture tangling, lens decentration and optic tilt.

## Cannula positioning

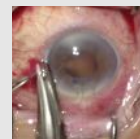
We create peritomies temporally and nasally with relaxing radial incisions for adequate exposure, then use external cautery to achieve proper hemostasis.

Precise and careful measurement before placing the cannula is essential. The corneal limbus is marked at two points along the horizontal axis, each 180 degrees apart to establish the axis of fixation. Rotation by a few clock hours can help avoid interference from the nasal bridge. The sclera is marked at two points, each 3 mm posterior to the limbus, 5 mm apart, centered around the horizontal limbal marks (Figure 1).

A 25-gauge cannula is placed, non-tunneled, at the superior mark and the 25-g trocar, marked with a sterile marking pen, is used to create a sclerotomy at the inferior mark. The same is repeated on the opposite

## View the Video

Dr. Sivalingam and Dr. Cohen demonstrate their technique for GORE-TEX sutured intraocular lens placement. Available at: [https://bit.ly/VideoPearl\\_32](https://bit.ly/VideoPearl_32)



side of the limbus.

When creating these sclerotomies, the blade must be oriented parallel to the limbus to avoid wound gaping when tightening the suture. Mismeasurement during trocar placement can lead to lens tilt and decentration, so it's essential to take extra time to confirm proper placement.

## Avoiding fog

The enVista MX60 lens is a hydrophobic acrylic lens, so it's not susceptible to (Continued on page 19)

## Bios

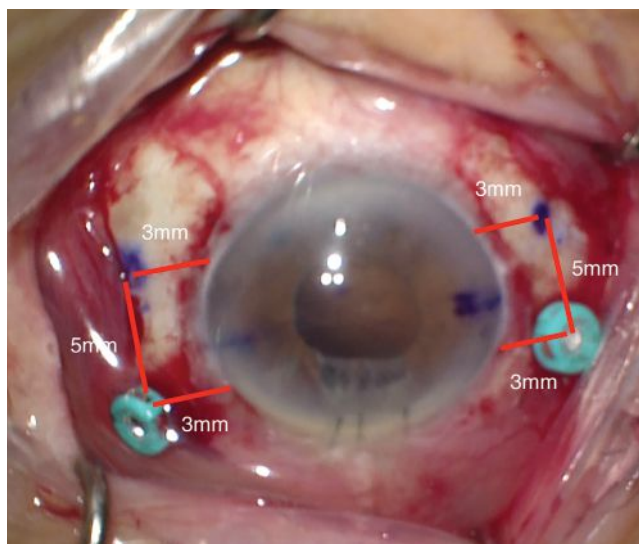
**Dr. Sivalingam** is a second-year vitreoretinal fellow at Wills Eye Hospital, Philadelphia.

**Dr. Cohen** is an assistant professor of ophthalmology at Thomas Jefferson University Hospital, Philadelphia, a member of the retina service at Wills Eye Hospital and a member of Mid Atlantic Retina.

**Dr. Hahn** is a vitreoretinal specialist at NJ Retina in Teaneck.

**DISCLOSURES:** The authors have no relevant financial disclosures.

**Dr. Hahn** has no relevant financial disclosures.



**Figure 1. Schematic of the 25-gauge cannula and sclerotomy placement. The corneal limbus is marked at two points, 180 degrees apart, along the horizontal meridian. The 25-g cannulas are placed 3 mm posterior to the limbus. Sclerotomies are made 3 mm posterior to the limbus and 5 mm inferior to the cannulas. Cannulas and sclerotomies are centered around the horizontal meridian.**



# PROGRESSION IN GEOGRAPHIC ATROPHY IS RELENTLESS AND IRREVERSIBLE<sup>1-4</sup>

While GA progression may appear to move slowly, it can affect your patients faster than you think<sup>1,4-6</sup>

The consequences of Geographic Atrophy (GA) are too critical to be ignored<sup>7-9</sup>



**IN A MEDIAN OF ONLY 2.5 YEARS,** GA lesions encroached on the fovea according to a prospective AREDS study (N=3640)<sup>2\*</sup>



**2 OUT OF 3 PATIENTS** lost the ability to drive in a median time of <2 years according to a retrospective study (n=523)<sup>10†</sup>

GA lesions can lead to visual impairment even before they reach the fovea<sup>1,5,6</sup>



See the effect of GA progression on your patients

\*Data sourced from the Age-related Eye Disease Study (AREDS) Report #26—a long-term, multicenter, prospective study examining progression of GA area in a cohort of 3640 patients with signs of early and more advanced forms of AMD.

†A retrospective cohort analysis (N=1901) of a multicenter electronic medical record database examining disease burden and progression in patients in the United Kingdom with bilateral GA secondary to AMD.

BCVA=best-corrected visual acuity.

References: 1. Boyer DS et al. *Retina*. 2017;37:819-835. 2. Lindblad AS et al, and AREDS Research Group. *Arch Ophthalmol*. 2009;127(9):1168-1174. 3. Holz FG et al. *Ophthalmology*. 2014;121(5):1079-1091. 4. Sunness JS et al. *Ophthalmology*. 2007;114(2):271-277. 5. Kimel M et al. *Invest Ophthalmol Vis Sci*. 2016;57(14):6298-6304. 6. Sadda SR et al. *Retina*. 2016;36(10):1806-1822. 7. Singh RP et al. *Am J Ophthalmic Clin Trials*. 2019;(1):1-6. doi:10.25259/ajoc-9-2018. 8. Sivaprasad S et al. *Ophthalmol Ther*. 2019;8(1):115-124. 9. Patel PJ et al. *Clin Ophthalmol*. 2020;14:15-28. 10. Chakravarthy U et al. *Ophthalmology*. 2018;125:842-849.

## Apellis

Intended for US HCP only.  
© 2022 Apellis Pharmaceuticals, Inc.  
All rights reserved. 2/22 US-GA-2200004 V1.0

# RETINA SPECIALIST



## KEEP UP WITH CUTTING-EDGE SCIENCE IN RETINA

*Retina Specialist* focuses on the latest advances in the diagnosis, medical management and surgical treatment of diseases of the retina, along with practical, real-world advice from leading clinicians and other experts on managing the successful retina practice.

### Watch for issues in:

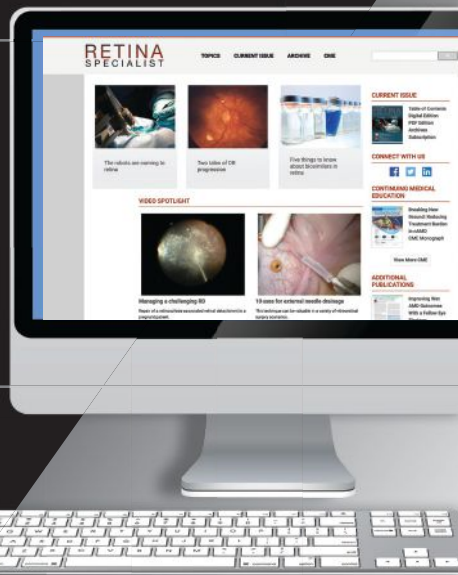
- JANUARY/FEBRUARY
- MARCH/APRIL
- MAY/JUNE
- JULY/AUGUST
- SEPTEMBER/OCTOBER
- NOVEMBER/DECEMBER

### WEBSITE

RETINASPECIALIST.COM

## RETINA ONLINE

Each month, Medical Editor Philip Rosenfeld, MD, PhD, and our editors provide you with this timely and easily accessible report to keep you up to date on important information affecting the care of patients with vitreoretinal disease.



### FOR INQUIRIES CONTACT

**RETINASPECIALIST@JOBSON.COM**

### ADVERTISING OPPORTUNITIES

MICHAEL HOSTER • PUBLISHER • 610-492-1028 • MHOSTER@JOBSON.COM  
 MICHELE BARRETT • 215-519-1414 • MBARRETT@JOBSON.COM  
 JONATHAN DARDINE • 610-492-1030 • JDARDINE@JOBSON.COM

### FOLLOW US

- @RetSpecMag
- RetinaSpecialistMag

opacification under gas or air. This makes it a great choice for patients with a history of retinal pathology who may be at risk for future retinal surgery requiring a tamponade.

### Threading the lens

Proper placement of the 8-0 GORE-TEX suture through the eyelet is a key step to avoiding lens tilt. We pass the suture down through the islet and then back up and over the optic (*Figure 2*). We bring both ends of the suture anterior to the haptic to rest on its anterior surface. This orientation must be maintained after the lens is placed inside the eye. If a suture end slips under the haptic, lens tilt will surely happen.

### Avoiding suture twisting

It's paramount to maintain proper superior and inferior orientation of the suture ends while threading through the cannula and sclerotomy. Threading one side of the suture through the sclerotomies before inserting the lens helps with stability.

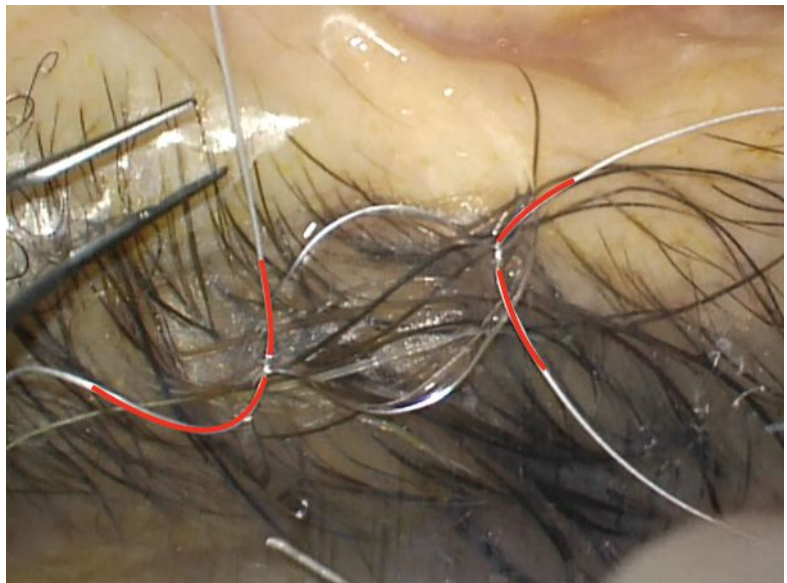
Once one side is carefully threaded, the lens must be folded carefully while maintaining the orientation of the suture. We do this by folding the IOL in half and tucking the lead optic into the "taco."

The corneal wound must be large enough to smoothly allow for IOL insertion into the eye while maintaining a constant tension on the suture. Once the IOL is in the appropriate position, you can remove the cannula and throw a stabilizing knot to keep the IOL in position. This allows for easier visualization of the optic through the pupillary margin to ensure that the suture is oriented correctly for threading the opposite sclerotomies.

Once the lens is stabilized on both sides (using the first tie of a slipknot or the first throw of a 3-1-1 tie), we recommend using a Sinsky hook or a Lester pusher to displace the iris peripherally and visualize the suture orientation over the haptic and verify the position is appropriate.

### Mind the eyelet

It's important to place minimal tension on



**Figure 2. The enVista MX60 lens (Bausch + Lomb) in proper backwards S configuration. Two CV-8 GORE-TEX sutures are passed down through each eyelet and passed back over the haptic. Each end of the suture lies flat on the anterior surface of the haptic.**

the eyelet itself during suture tightening, because not doing so can lead to eyelet tears and lens dislocation. The tension should be just enough that the lens is centered, suture slack is minimal and the lens sits flush to the sclera. You can titrate this by gently pulling the suture loop to gauge its tension.

### Bottom line

GORE-TEX-sutured IOL placement using the enVista MX60 along with standard pars plana vitrectomy is a safe, predictable and efficient method for secondary IOL placement. Proper sclerotomy placement, careful suture threading through the eyelet, and consistent suture placement through the sclerotomies are all key steps that, if done properly, will lead to success. <sup>RS</sup>

### REFERENCES

1. Khan MA, Gerstenblith AT, Dollin ML, et al. Scleral fixation of posterior chamber intraocular lenses using GORE-TEX suture with concurrent 23-gauge pars plana vitrectomy. *Retina*. 2014;34:1477-1480.
2. Parekh P, Green WR, Stark WJ, Akpek EK. Subluxation of suture-fixed posterior chamber intraocular lenses A clinicopathologic study. *Ophthalmology*. 2007;114:232-237.
3. Khan MA, Gupta OP, Smith RG, et al. Scleral-fixation of intraocular lenses using GORE-TEX suture: Clinical outcomes and safety profile. *Br J Ophthalmol*. 2016. 100:638-643.

# Anti-VEGF for RVO: A look at real-world results

*They don't necessarily measure up to what clinical trials show, pointing to a need for more durable therapies.*



Abdulla Shaheen,  
MD



Carl J. Danzig, MD

By Abdulla Shaheen, MD, and Carl J. Danzig, MD

## Take-home points

- » In randomized clinical trials, patients with macular edema from retinal vein occlusion demonstrated significant improvements in best-corrected visual acuity during year one with monthly monitoring and frequent anti-VEGF injections.
- » In real-world studies, RVO patients with macular edema, who were monitored less often and received fewer injections, didn't attain the same BCVA gains within the first year.
- » A novel anti-VEGF therapy with a longer duration is required to reduce the treatment burden for RVO patients, provide greater improvement in BCVA in real-world settings and overcome the demand for regular monitoring.

## Bios

**Dr. Shaheen** is with the Bascom Palmer Eye Institute, University of Miami Miller School of Medicine, Miami.

**Dr. Danzig** is with the Rand Eye Institute, Deerfield Beach, Florida, and Florida Atlantic University, Charles E. Schmidt School of Medicine, Boca Raton.

**DISCLOSURES:** Dr. Shaheen has no relevant disclosures.

**Dr. Danzig** disclosed relationships with Adverum Biotechnologies, Alexion, Bayer, Genentech/Roche, Gyroscope Therapeutics, IvericBio, Kodiak Sciences, Novartis, Regeneron Pharmaceuticals and Unity Biotechnology.

**R**etinal vein occlusion is the second most common cause of retinal vascular diseases after diabetic retinopathy.<sup>1</sup> It's defined by the site of occlusion as branch RVO, when the occlusion occurs at a venous tributary; hemiretinal vein occlusion, when it occurs at the major bifurcation of the retinal vein; and central RVO, when it occurs within or posterior to the optic nerve head.<sup>1</sup> The etiology of RVO includes impaired venous return and its manifestation ranges from asymptomatic to complete visual loss.<sup>1</sup>

BRVO is subdivided into major and macular BRVO. Major BRVO presents with a peripheral field defect due to an occlusion of a retinal vein. Macular BRVO presents with central field defect due to occlusion of a macular vein. In both subtypes, visual acuity can improve without treatment by three or more lines, yet the two subtypes have different final visual outcomes.<sup>2</sup>

In contrast, VA in eyes with CRVO may range from excellent vision in the absence of

retinal nonperfusion to severe vision loss if the retinal nonperfusion is substantial.<sup>3</sup> Eyes with mild-to-moderate nonperfusion may go on to develop progressive nonperfusion with potential further complications, making their future visual outcomes more challenging to predict.<sup>3</sup>

## Moving from surgery to anti-VEGF

Several interventions aimed at enhancing perfusion and relieving venous blockage have proven ineffective. These include creating anastomoses by surgery and laser, thrombolysing the occlusion and bypassing the congestion via optic nerve sheathotomy. For this reason, the management revolves around treating and preventing RVO complications.

RVO can cause macular edema and/or ischemia, vitreous hemorrhage, tractional retinal detachment and neovascular glaucoma. Clinical trials for RVO initially focused on laser photocoagulation, which demonstrated effectiveness in BRVO but limited

efficacy for CRVO. In 2009 the dexamethasone steroid injection (Ozurdex, Allergan/AbbVie) became the first intravitreal medication to be specifically approved by the Food and Drug Administration to treat macular edema from RVO.

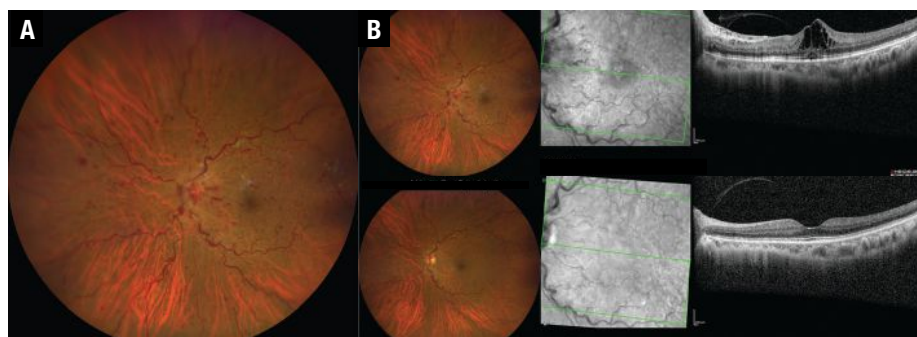
Bevacizumab (Avastin, Genentech/Roche) was used off-label for RVO as early as 2005.<sup>4</sup> FDA approval of ranibizumab (Lucentis, Genentech/Roche) and aflibercept (Eylea, Regeneron Pharmaceuticals) for RVO

followed Ozurdex a few years later. More recently, two Phase III studies of faricimab (Vabysmo, Genentech/Roche) have demonstrated equivalency to aflibercept in treating BRVO and CRVO, and intravitreal tarcocimab (KSI-301, Kodiak Sciences) is being evaluated for macular edema due to RVO. Here, we explore the evidence supporting the FDA-approved treatments for RVO.

### Ranibizumab in BRVO

The BRAVO<sup>5</sup> and CRUISE<sup>6</sup> trials, respectively, evaluated ranibizumab for efficacy and safety for BRVO- and CRVO-associated macular edema. BRAVO enrolled 397 patients receiving a 1:1:1 pattern of monthly intraocular injections of 0.3 or 0.5 mg ranibizumab or sham. The mean (95% CI) change in Early Treatment Diabetic Retinopathy Study letter score in BCVA at six months was 16.6 (14.7 to 18.5) and 18.3 (16.0 to 20.6) in the 0.3- and 0.5-mg treatment groups, and 7.3 (5.1-9.5) in the sham group ( $p < 0.0001$  for each ranibizumab group vs. sham).

The proportion of patients who gained  $\geq 15$  letters at month six was 55.2 and 61.1 percent in the respective ranibizumab groups, and 28.8 percent in the sham arm ( $p < 0.0001$ ). At month six, significantly more ranibizumab-treated patients (67.9 and 64.9, respectively) had BCVA of  $\geq 20/40$  than sham patients (41.7 percent;  $p < 0.0001$ ). Central foveal thickness (CFT) decreased by a mean of 337 and 345  $\mu\text{m}$  in the ranibizumab



**Figure 1. A)** Color fundus photograph and corresponding optical coherence tomography scan of an eye with central retinal vein occlusion before aflibercept injections and **B)** six months after treatment. Notice resolution of the hemorrhages, optic disc swelling and the decrease in vessel tortuosity and dilatation.

ab groups and 158  $\mu\text{m}$  in the sham group ( $p < 0.0001$ ).

### Ranibizumab in CRVO

The CRUISE trial included 392 CRVO patients with macular edema and the design was similar to that of BRAVO. The mean (95% CI) change from baseline BCVA letter score at month six was 12.7 (9.9 to 15.4) and 14.9 (12.6 to 17.2) in the 0.3 mg and 0.5 mg ranibizumab groups, respectively, and 0.8 (-2 to 3.6) in the sham group ( $p < 0.0001$ ).

The percentage of patients who gained  $\geq 15$  letters in BCVA at month six was 46.2 and 47.7 percent in the respective ranibizumab groups and 16.9 percent in the sham group ( $p < 0.0001$ ). At six months, CFT decreased by a mean of 434  $\mu\text{m}$  (0.3 mg) and 452  $\mu\text{m}$  (0.5 mg) vs. 168  $\mu\text{m}$  in the sham group ( $p < 0.0001$ ). The FDA approved ranibizumab 0.5 mg for treating macular edema following RVO in 2010.

### Aflibercept for RVO

The VIBRANT trial evaluated aflibercept for efficacy and safety against macular grid laser for BRVO-associated macular edema (Figure 1).<sup>7</sup> In the aflibercept group, 52.7 percent gained  $\geq 15$  ETDRS letters at the week 24 vs. 26.7 percent in the laser group ( $p = 0.0003$ ), with a mean improvement of 17 ETDRS letters in the former and 6.9 ETDRS letters in the latter ( $p < 0.0001$ ).

Aflibercept was also evaluated for

CRVO-associated macular edema in the COPERNICUS trial involving 188 patients.<sup>8</sup> Trial subjects received aflibercept injection 2 mg or sham injections every four weeks up to week 24. During weeks 24 to 52, patients in both arms received aflibercept injection *pro re nata* with monthly follow-up. In weeks 52 to 100, subjects also received aflibercept injections PRN but with at least every three months follow-up evaluation. At week 25, 56.1 vs. 12.3 percent gained  $\geq 15$  ETDRS letters; at week 52, the respective gains were 55.3 vs. 30.1 percent; and at week 100, 49.1 vs. 23.3 percent ( $p < 0.001$  for all).

The mean change from baseline BCVA was also significantly higher in the treatment arm: +17.3 vs. -4 letters at week 24 ( $p < 0.001$ ); +16.2 vs. +3.8 at week 52 ( $p < 0.001$ ); and +13 vs. +1.5 at week 100 ( $p < 0.0001$ ). At the same time points, the

mean central retinal thickness reduction from baseline was 457.2 vs. 144.8  $\mu\text{m}$  ( $p < 0.001$ ); 413 vs. 381.8  $\mu\text{m}$  ( $p = 0.546$ ); and 390 vs. 343.3  $\mu\text{m}$  ( $p = 0.366$ ) in the treatment vs. the control arms, respectively. The FDA in 2014 approved aflibercept for treating BRVO or CRVO with macular edema.

### Clinical trials vs. the real world

As these results show,<sup>8-11</sup> frequent anti-VEGF injections for macular edema associated with BRVO or CRVO have improved the mean VA in randomized clinical trials. While RCTs are the most reliable research design for evaluating the effectiveness of interventions, what matters is how this translates into real-world practice. Real-world treatment involves variable treatment patterns, patient groups, care providers and, more importantly, follow-up intervals.

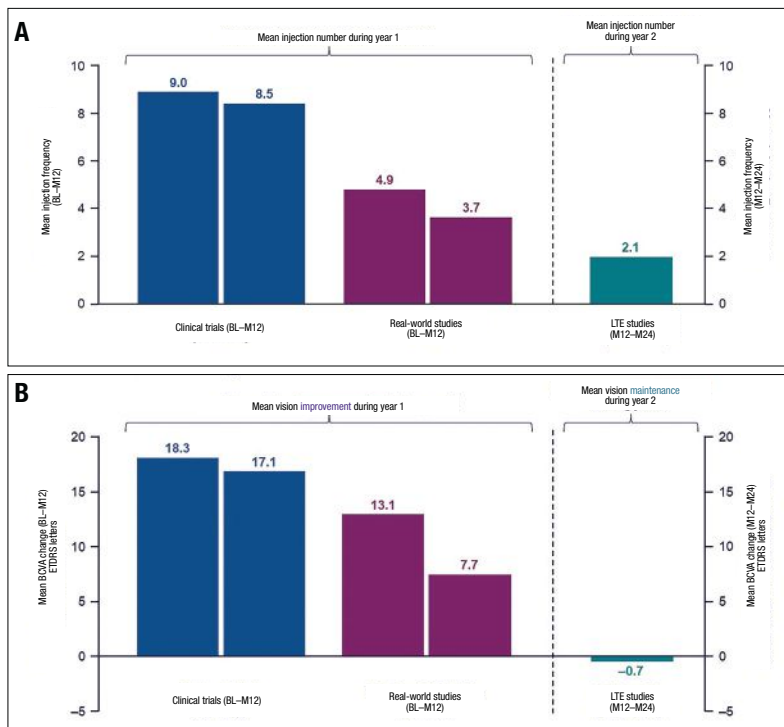
Real-world studies on the approved anti-VEGF treatments for RVO-associated macular edema have demonstrated outcomes that diverge from the clinical trials. We evaluated BCVA outcomes and anti-VEGF injection frequency during the first year of treatment and improvement of macular edema in eyes with BRVO or CRVO in real-world studies vs. randomized clinical trials.

We also incorporated the published results of long-term extension (LTE) studies.<sup>12</sup> We included seven controlled clinical trials (two BRVO, five CRVO; all with monthly monitoring), four LTE trials (two BRVO/CRVO, two CRVO; the majority with less than monthly monitoring); and two real-world studies (both BRVO/CRVO) monitored at the investigator's discretion.

### Lower injection frequency

We found that the anti-VEGF injection frequency in patients with branch RVO was lower in real-world studies<sup>13,14</sup> and LTE trials<sup>15</sup> than in clinical trials (Figure 2A).<sup>9,16,17</sup> In real-world studies, individuals with BRVO who had fewer anti-VEGF injections didn't

(Continued on page 27)



**Figure 2. A) Patients with branch retinal vein occlusion in long-term extension (LTE) and real-world studies received fewer injections on average over 12 months than those in clinical trials. B) In addition, compared to clinical trials, patients with BRVO in real-world studies had a lesser improvement in visual acuity. In contrast, patients retained the initial vision improvements gained in clinical trials during LTE studies. (Courtesy Genentech/Roche)**

## RVO in clinical practice

**T**hough retinal vein occlusion is often a straightforward diagnosis, treatment can remain burdensome, leaving some patients significantly undertreated. Treatment algorithms vary amongst retina specialists, and often they don't exactly align with the clinical trial paradigms.

Many factors enter into the treating physician's mind. What's the presenting vision? Is the RVO ischemic or nonischemic? Is there an afferent pupillary defect? Is the patient phakic? Can I appreciate any neovascularization, particularly of the iris? Does the patient need prior authorization in order to initiate therapy?

All of these factors play a role in how we treat our patients. Off-label bevacizumab (Avastin, Genentech/Roche) may be the first treatment, or occasionally the only allowed treatment, for a patient with macular edema due to RVO. That may not be ideal for many patients, but it's absolutely a reasonable start.

Furthermore, all anti-VEGF injections can suppress the downstream consequences of RVO such as possible vitreous hemorrhage, neovascular glaucoma and even traction retinal detachment that would possibly occur had the disease been left untreated. Both ranibizumab (Lucentis, Genentech/Roche) and aflibercept (Eylea, Regeneron Pharmaceuticals) can maintain good control of macular edema in many patients, but some need more. These patients often benefit from adding a dexamethasone implant (Ozurdex, Allergan/AbbVie) to their regimen. Yet, still some patients need focal laser or panretinal photocoagulation depending on the level of ischemia and nonperfusion seen on fluorescein angiography.

### Role of imaging

When I first encounter a new patient with any type of RVO, I sometimes get a widefield fluorescein angiogram if I feel the quality will be adequate to identify areas of ischemia and the information would be useful, but more often

than not I defer FA until I have better visualization of the retina tissue once the degree of hemorrhage lessens.

All I need most of the time is a quality, comprehensive examination and an optical coherence tomography scan. From there, in most cases I can initiate therapy on the same day. Many of these patients have commercial insurance and all too often I'm forced to use off-label bevacizumab as my initial therapy.

If I had my choice, and if it were available, I would use a sample of aflibercept as my first-line treatment, and I would continue it monthly for at least three doses. Often, I continue monthly for up to six doses, though I may use a treat-and-extend protocol following the third or fourth injection, depending on how the patient is doing. During this time, between months three and six, I commonly order a widefield FA to assess peripheral nonperfusion.

### Adding dexamethasone implant

If a patient can't go longer than six to eight weeks between anti-VEGF, namely aflibercept, injections, I'll usually add a dexamethasone implant. A steroid injection isn't a replacement for anti-VEGF therapy, but rather a supplement to it.

Steroid treatments come with their share of side effects. More than one intravitreal steroid treatment will cause cataract progression in a phakic patient. Intraocular pressure rise is also of concern, but it only occurs in a subset of patients. Laser isn't commonly used, although it may decrease the vascular endothelial growth factor load in a patient with significant peripheral ischemia, as identified on widefield FA.

Overall, most patients do quite well, and we're no longer seeing nearly as much neovascular complications that we did before the anti-VEGF era. Nevertheless, more often than we likely realize, patients are undertreated in the real world, with the current burden of injections too difficult for some patients to manage.

—C.D.

**Many factors enter into the treating physician's mind. What's the presenting vision? Is the RVO ischemic or nonischemic? Is there an afferent pupillary defect? Is the patient phakic? Can I appreciate any neovascularization?**

# WHAT COULD SHE SEE THIS YEAR?



**304  
BINGO  
CARDS**

 **EYLEA**<sup>®</sup>  
(aflibercept) Injection  
For Intravitreal Injection

*Inspired by a real patient  
with Wet AMD.*

## **IMPORTANT SAFETY INFORMATION CONTRAINDICATIONS**

- EYLEA is contraindicated in patients with ocular or periocular infections, active intraocular inflammation, or known hypersensitivity to aflibercept or to any of the excipients in EYLEA.

## **WARNINGS AND PRECAUTIONS**

- Intravitreal injections, including those with EYLEA, have been associated with endophthalmitis and retinal detachments. Proper aseptic injection technique must always be used when administering EYLEA. Patients should be instructed to report any symptoms suggestive of endophthalmitis or retinal detachment without delay and should be managed appropriately. Intraocular inflammation has been reported with the use of EYLEA.
- Acute increases in intraocular pressure have been seen within 60 minutes of intravitreal injection, including with EYLEA. Sustained increases in intraocular pressure have also been reported after repeated intravitreal dosing with VEGF inhibitors. Intraocular pressure and the perfusion of the optic nerve head should be monitored and managed appropriately.
- There is a potential risk of arterial thromboembolic events (ATEs) following intravitreal use of VEGF inhibitors, including EYLEA. ATEs are defined as nonfatal stroke, nonfatal myocardial infarction, or vascular death (including deaths of unknown cause). The incidence of reported thromboembolic events in wet AMD studies during the first year was 1.8% (32 out of 1824) in the combined group of patients treated with EYLEA compared with 1.5% (9 out of 595) in patients treated with ranibizumab; through 96 weeks, the incidence was 3.3% (60 out of 1824) in the EYLEA group compared with 3.2% (19 out of 595) in the ranibizumab group. The incidence in the DME studies from baseline to week 52 was 3.3% (19 out of 578) in the combined group of patients treated with EYLEA compared with 2.8% (8 out of 287) in the control group; from baseline to week 100, the incidence was 6.4% (37 out of 578) in the combined group of patients treated with EYLEA compared with 4.2% (12 out of 287) in the control group. There were no reported thromboembolic events in the patients treated with EYLEA in the first six months of the RVO studies.

EYLEA is a registered trademark of Regeneron Pharmaceuticals, Inc.

**REGENERON**

© 2021, Regeneron Pharmaceuticals, Inc. All rights reserved.  
777 Old Saw Mill River Road, Tarrytown, NY 10591



# PROVEN VISUAL OUTCOMES AT YEAR 1 IN THE VIEW STUDIES

## Fewer injections with EYLEA Q8 vs ranibizumab Q4

Demonstrated in the largest phase 3 anti-VEGF trials completed to date in Wet AMD (N=2412)<sup>1-3</sup>

Proportion of patients who maintained vision (<15 ETDRS letters lost of BCVA) at Year 1 from baseline<sup>1-3,\*</sup>

	Primary Endpoint (Year 1)	
	VIEW 1	VIEW 2
EYLEA Q4	<b>95%</b> (12.5 injections <sup>†</sup> )	<b>95%</b> (12.6 injections <sup>†</sup> )
EYLEA Q8 <sup>‡</sup>	<b>94%</b> (7.5 injections <sup>†</sup> )	<b>95%</b> (7.7 injections <sup>†</sup> )
ranibizumab Q4	<b>94%</b> (12.1 injections <sup>†</sup> )	<b>95%</b> (12.7 injections <sup>†</sup> )

\*Last observation carried forward; full analysis set.

<sup>†</sup>Safety analysis set.

<sup>‡</sup>Following 3 initial monthly doses.



**Vision was maintained at Year 1 with ≈5 fewer injections with EYLEA Q8 vs ranibizumab Q4**

## EYLEA was clinically equivalent to ranibizumab.

**VIEW 1 and VIEW 2 study designs:** Two multicenter, double-masked clinical studies in which patients with Wet AMD (N=2412; age range: 49-99 years, with a mean of 76 years) were randomized to receive: 1) EYLEA 2 mg Q8 following 3 initial monthly doses; 2) EYLEA 2 mg Q4; 3) EYLEA 0.5 mg Q4; or 4) ranibizumab 0.5 mg Q4. Protocol-specified visits occurred every 28 (±3) days.<sup>1</sup> In both studies, the primary efficacy endpoint was the proportion of patients with Wet AMD who maintained vision, defined as losing <15 letters of visual acuity at Week 52, compared with baseline.<sup>1</sup>

**SEE WHAT EYLEA COULD DO FOR YOUR PATIENTS WITH WET AMD AT [HCP.EYLEA.US](http://HCP.EYLEA.US)**

anti-VEGF, anti-vascular endothelial growth factor; BCVA, best-corrected visual acuity; ETDRS, Early Treatment Diabetic Retinopathy Study; Q4, every 4 weeks; Q8, every 8 weeks.

## ADVERSE REACTIONS

- Serious adverse reactions related to the injection procedure have occurred in <0.1% of intravitreal injections with EYLEA including endophthalmitis and retinal detachment.
- The most common adverse reactions (≥5%) reported in patients receiving EYLEA were conjunctival hemorrhage, eye pain, cataract, vitreous detachment, vitreous floaters, and intraocular pressure increased.
- Patients may experience temporary visual disturbances after an intravitreal injection with EYLEA and the associated eye examinations. Advise patients not to drive or use machinery until visual function has recovered sufficiently.

## INDICATIONS

EYLEA® (aflibercept) Injection 2 mg (0.05 mL) is indicated for the treatment of patients with Neovascular (Wet) Age-related Macular Degeneration (AMD), Macular Edema following Retinal Vein Occlusion (RVO), Diabetic Macular Edema (DME), and Diabetic Retinopathy (DR).

**References:** 1. EYLEA® (aflibercept) Injection full U.S. Prescribing Information. Regeneron Pharmaceuticals, Inc. August 2019. 2. Data on file. Regeneron Pharmaceuticals, Inc. 3. Heier JS, Brown DM, Chong V, et al; for the VIEW 1 and VIEW 2 Study Groups. Intravitreal aflibercept (VEGF Trap-Eye) in wet age-related macular degeneration. *Ophthalmology*. 2012;119(12):2537-2548. doi:10.1016/j.ophtha.2012.09.006

Please see Brief Summary of Prescribing Information on the following page.

03/2021  
EYL.21.02.0019



**BRIEF SUMMARY**—Please see the EYLEA full Prescribing Information available on HCP.EYLEA.US for additional product information.

**1 INDICATIONS AND USAGE**

EYLEA is a vascular endothelial growth factor (VEGF) inhibitor indicated for the treatment of patients with:

**Neovascular (Wet) Age-Related Macular Degeneration (AMD), Macular Edema Following Retinal Vein Occlusion (RVO), Diabetic Macular Edema (DME), Diabetic Retinopathy (DR).**

**4 CONTRAINDICATIONS**

**4.1 Ocular or Periorbital Infections**

EYLEA is contraindicated in patients with ocular or periorbital infections.

**4.2 Active Intraocular Inflammation**

EYLEA is contraindicated in patients with active intraocular inflammation.

**4.3 Hypersensitivity**

EYLEA is contraindicated in patients with known hypersensitivity to afibercept or any of the excipients in EYLEA. Hypersensitivity reactions may manifest as rash, pruritus, urticaria, severe anaphylactic/anaphylactoid reactions, or severe intraocular inflammation.

**5 WARNINGS AND PRECAUTIONS**

**5.1 Endophthalmitis and Retinal Detachments**

Intravitreal injections, including those with EYLEA, have been associated with endophthalmitis and retinal detachments [see Adverse Reactions (6.1)]. Proper aseptic injection technique must always be used when administering EYLEA. Patients should be instructed to report any symptoms suggestive of endophthalmitis or retinal detachment without delay and should be managed appropriately [see Patient Counseling Information (17)].

**5.2 Increase in Intraocular Pressure**

Acute increases in intraocular pressure have been seen within 60 minutes of intravitreal injection, including with EYLEA [see Adverse Reactions (6.1)]. Sustained increases in intraocular pressure have also been reported after repeated intravitreal dosing with vascular endothelial growth factor (VEGF) inhibitors. Intraocular pressure and the perfusion of the optic nerve head should be monitored and managed appropriately.

**5.3 Thromboembolic Events**

There is a potential risk of arterial thromboembolic events (ATEs) following intravitreal use of VEGF inhibitors, including EYLEA. ATEs are defined as nonfatal stroke, nonfatal myocardial infarction, or vascular death (including deaths of unknown cause). The incidence of reported thromboembolic events in wet AMD studies during the first year was 1.8% (32 out of 1824) in the combined group of patients treated with EYLEA compared with 1.5% (9 out of 595) in patients treated with ranibizumab; through 96 weeks, the incidence was 3.3% (60 out of 1824) in the EYLEA group compared with 3.2% (19 out of 595) in the ranibizumab group. The incidence in the DME studies from baseline to week 52 was 3.3% (19 out of 578) in the combined group of patients treated with EYLEA compared with 2.8% (8 out of 287) in the control group; from baseline to week 100, the incidence was 6.4% (37 out of 578) in the combined group of patients treated with EYLEA compared with 4.2% (12 out of 287) in the control group. There were no reported thromboembolic events in the patients treated with EYLEA in the first six months of the RVO studies.

**6 ADVERSE REACTIONS**

The following potentially serious adverse reactions are described elsewhere in the labeling:

- Hypersensitivity [see Contraindications (4.3)]
- Endophthalmitis and retinal detachments [see Warnings and Precautions (5.1)]
- Increase in intraocular pressure [see Warnings and Precautions (5.2)]
- Thromboembolic events [see Warnings and Precautions (5.3)]

**6.1 Clinical Trials Experience**

Because clinical trials are conducted under widely varying conditions, adverse reaction rates observed in the clinical trials of a drug cannot be directly compared to rates in other clinical trials of the same or another drug and may not reflect the rates observed in practice.

A total of 2980 patients treated with EYLEA constituted the safety population in eight phase 3 studies. Among those, 2379 patients were treated with the recommended dose of 2 mg. Serious adverse reactions related to the injection procedure have occurred in <0.1% of intravitreal injections with EYLEA including endophthalmitis and retinal detachment. The most common adverse reactions (≥5%) reported in patients receiving EYLEA were conjunctival hemorrhage, eye pain, cataract, vitreous detachment, vitreous floaters, and intraocular pressure increased.

**Neovascular (Wet) Age-Related Macular Degeneration (AMD).** The data described below reflect exposure to EYLEA in 1824 patients with wet AMD, including 1223 patients treated with the 2-mg dose, in 2 double-masked, controlled clinical studies (VIEW1 and VIEW2) for 24 months (with active control in year 1). Safety data observed in the EYLEA group in a 52-week, double-masked, Phase 2 study were consistent with these results.

**Table 1: Most Common Adverse Reactions (≥1%) in Wet AMD Studies**

Adverse Reactions	Baseline to Week 52		Baseline to Week 96	
	EYLEA (N=1824)	Active Control (ranibizumab) (N=595)	EYLEA (N=1824)	Control (ranibizumab) (N=595)
Conjunctival hemorrhage	25%	28%	27%	30%
Eye pain	9%	9%	10%	10%
Cataract	7%	7%	13%	10%
Vitreous detachment	6%	6%	8%	8%
Vitreous floaters	6%	7%	8%	10%
Intraocular pressure increased	5%	7%	7%	11%
Ocular hyperemia	4%	8%	5%	10%
Corneal epithelium defect	4%	5%	5%	6%
Detachment of the retinal pigment epithelium	3%	3%	5%	5%
Injection site pain	3%	3%	3%	4%
Foreign body sensation in eyes	3%	4%	4%	4%
Lacrimation increased	3%	1%	4%	2%
Vision blurred	2%	2%	4%	3%
Intraocular inflammation	2%	3%	3%	4%
Retinal pigment epithelium tear	2%	1%	2%	2%
Injection site hemorrhage	1%	2%	2%	2%
Eyeid edema	1%	2%	2%	3%
Corneal edema	1%	1%	1%	1%
Retinal detachment	<1%	<1%	1%	1%

Less common serious adverse reactions reported in <1% of the patients treated with EYLEA were hypersensitivity, retinal tear, and endophthalmitis.

**Macular Edema Following Retinal Vein Occlusion (RVO).** The data described below reflect 6 months exposure to EYLEA with a monthly 2 mg dose in 218 patients following central retinal vein occlusion (CRVO) in 2 clinical studies (COPERNICUS and GALILEO) and 91 patients following branch retinal vein occlusion (BRVO) in one clinical study (VIBRANT).

**Table 2: Most Common Adverse Reactions (≥1%) in RVO Studies**

Adverse Reactions	CRVO		BRVO	
	EYLEA (N=218)	Control (N=142)	EYLEA (N=91)	Control (N=92)
Eye pain	13%	5%	4%	5%
Conjunctival hemorrhage	12%	11%	20%	4%
Intraocular pressure increased	8%	6%	2%	0%
Corneal epithelium defect	5%	4%	2%	0%
Vitreous floaters	5%	1%	1%	0%
Ocular hyperemia	5%	3%	2%	2%
Foreign body sensation in eyes	3%	5%	3%	0%
Vitreous detachment	3%	4%	2%	0%
Lacrimation increased	3%	4%	3%	0%
Injection site pain	3%	1%	1%	0%
Vision blurred	1%	<1%	1%	1%
Intraocular inflammation	1%	1%	0%	0%
Cataract	<1%	1%	5%	0%
Eyeid edema	<1%	1%	1%	0%

Less common adverse reactions reported in <1% of the patients treated with EYLEA in the CRVO studies were corneal edema, retinal tear, hypersensitivity, and endophthalmitis.

**Diabetic Macular Edema (DME) and Diabetic Retinopathy (DR).** The data described below reflect exposure to EYLEA in 578 patients with DME treated with the 2-mg dose in 2 double-masked, controlled clinical studies (VIVID and VISTA) from baseline to week 52 and from baseline to week 100.

**Table 3: Most Common Adverse Reactions (≥1%) in DME Studies**

Adverse Reactions	Baseline to Week 52		Baseline to Week 100	
	EYLEA (N=578)	Control (N=287)	EYLEA (N=578)	Control (N=287)
Conjunctival hemorrhage	28%	17%	31%	21%
Eye pain	9%	6%	11%	9%
Cataract	8%	9%	19%	17%
Vitreous floaters	6%	3%	8%	6%
Corneal epithelium defect	5%	3%	7%	5%
Intraocular pressure increased	5%	3%	9%	5%
Ocular hyperemia	5%	6%	5%	5%
Vitreous detachment	3%	3%	8%	6%
Foreign body sensation in eyes	3%	3%	3%	3%
Lacrimation increased	3%	2%	4%	2%
Vision blurred	2%	2%	3%	4%
Intraocular inflammation	2%	<1%	3%	1%
Injection site pain	2%	<1%	2%	<1%
Eyeid edema	<1%	1%	2%	1%

Less common adverse reactions reported in <1% of the patients treated with EYLEA were hypersensitivity, retinal detachment, retinal tear, corneal edema, and injection site hemorrhage.

Safety data observed in 269 patients with nonproliferative diabetic retinopathy (NPDR) through week 52 in the PANORAMA trial were consistent with those seen in the phase 3 VIVID and VISTA trials (see Table 3 above).

**6.2 Immunogenicity**

As with all therapeutic proteins, there is a potential for an immune response in patients treated with EYLEA. The immunogenicity of EYLEA was evaluated in serum samples. The immunogenicity data reflect the percentage of patients whose test results were considered positive for antibodies to EYLEA in immunoassays. The detection of an immune response is highly dependent on the sensitivity and specificity of the assays used, sample handling, timing of sample collection, concomitant medications, and underlying disease. For these reasons, comparison of the incidence of antibodies to EYLEA with the incidence of antibodies to other products may be misleading.

In the wet AMD, RVO, and DME studies, the pre-treatment incidence of immunoreactivity to EYLEA was approximately 1% to 3% across treatment groups. After dosing with EYLEA for 24-100 weeks, antibodies to EYLEA were detected in a similar percentage range of patients. There were no differences in efficacy or safety between patients with or without immunoreactivity.

**8 USE IN SPECIFIC POPULATIONS**

**8.1 Pregnancy Risk Summary**

Adequate and well-controlled studies with EYLEA have not been conducted in pregnant women. Afibercept produced adverse embryofetal effects in rabbits, including external, visceral, and skeletal malformations. A fetal No Observed Adverse Effect Level (NOAEL) was not identified. At the lowest dose shown to produce adverse embryofetal effects, systemic exposures (based on AUC for free afibercept) were approximately 6 times higher than AUC values observed in humans after a single intravitreal treatment at the recommended clinical dose [see Animal Data].

Animal reproduction studies are not always predictive of human response, and it is not known whether EYLEA can cause fetal harm when administered to a pregnant woman. Based on the anti-VEGF mechanism of action for afibercept, treatment with EYLEA may pose a risk to human embryofetal development. EYLEA should be used during pregnancy only if the potential benefit justifies the potential risk to the fetus.

All pregnancies have a background risk of birth defect, loss, or other adverse outcomes. The background risk of major birth defects and miscarriage for the indicated population is unknown. In the U.S. general population, the estimated background risk of major birth defects and miscarriage in clinically recognized pregnancies is 2-4% and 15-20%, respectively.

**Data**

**Animal Data**

In two embryofetal development studies, afibercept produced adverse embryofetal effects when administered every three days during organogenesis to pregnant rabbits at intravenous doses ≥3 mg per kg, or every six days during organogenesis at subcutaneous doses ≥0.1 mg per kg.

Adverse embryofetal effects included increased incidences of postimplantation loss and fetal malformations, including anasarca, umbilical hernia, diaphragmatic hernia, gastroschisis, cleft palate, ectrodactyly, intestinal atresia, spina bifida, encephalomenocele, heart and major vessel defects, and skeletal malformations (fused vertebrae, sternbrae, and ribs; supernumerary vertebral arches and ribs; and incomplete ossification). The maternal No Observed Adverse Effect Level (NOAEL) in these studies was 3 mg per kg. Afibercept produced fetal malformations at all doses assessed in rabbits and the fetal NOAEL was not identified. At the lowest dose shown to produce adverse embryofetal effects in rabbits (0.1 mg per kg), systemic exposure (AUC) of free afibercept was approximately 6 times higher than systemic exposure (AUC) observed in humans after a single intravitreal dose of 2 mg.

**8.2 Lactation Risk Summary**

There is no information regarding the presence of afibercept in human milk, the effects of the drug on the breastfed infant, or the effects of the drug on milk production/excretion. Because many drugs are excreted in human milk, and because the potential for absorption and harm to infant growth and development exists, EYLEA is not recommended during breastfeeding. The developmental and health benefits of breastfeeding should be considered along with the mother's clinical need for EYLEA and any potential adverse effects on the breastfed child from EYLEA.

**8.3 Females and Males of Reproductive Potential Contraception**

Females of reproductive potential are advised to use effective contraception prior to the initial dose, during treatment, and for at least 3 months after the last intravitreal injection of EYLEA.

**Infertility**

There are no data regarding the effects of EYLEA on human fertility. Afibercept adversely affected female and male reproductive systems in cynomolgus monkeys when administered by intravenous injection at a dose approximately 1500 times higher than the systemic level observed in humans with an intravitreal dose of 2 mg. A No Observed Adverse Effect Level (NOAEL) was not identified. These findings were reversible within 20 weeks after cessation of treatment.

**8.4 Pediatric Use**

The safety and effectiveness of EYLEA in pediatric patients have not been established.

**8.5 Geriatric Use**

In the clinical studies, approximately 76% (2049/2701) of patients randomized to treatment with EYLEA were ≥65 years of age and approximately 46% (1250/2701) were ≥75 years of age. No significant differences in efficacy or safety were seen with increasing age in these studies.

**17 PATIENT COUNSELING INFORMATION**

In the days following EYLEA administration, patients are at risk of developing endophthalmitis or retinal detachment. If the eye becomes red, sensitive to light, painful, or develops a change in vision, advise patients to seek immediate care from an ophthalmologist [see Warnings and Precautions (5.1)].

Patients may experience temporary visual disturbances after an intravitreal injection with EYLEA and the associated eye examinations [see Adverse Reactions (6)]. Advise patients not to drive or use machinery until visual function has recovered sufficiently.

**REGENERON**

Manufactured by:  
**Regeneron Pharmaceuticals, Inc.**  
777 Old Saw Mill River Road  
Tarrytown, NY 10591

Issue Date: 08/2019  
Initial U.S. Approval: 2011

Based on the August 2019  
EYLEA® (afibercept) Injection full  
Prescribing Information.

EYL.20.09.0052

EYLEA is a registered trademark of Regeneron Pharmaceuticals, Inc.  
© 2020, Regeneron Pharmaceuticals, Inc.  
All rights reserved.

attain the visual benefits found in clinical trials. In contrast, individuals who participated in LTE studies were able to sustain their initial vision gains made during clinical trials (Figure 3B).

Similar to what we observed in patients with BRVO, patients with CRVO received, on average, fewer anti-VEGF injections throughout the course of 12 months in real-world studies<sup>13,14</sup> and LTE trials<sup>8,15,18</sup> than in clinical trials (Figure 3A).<sup>8,10,11,17-20</sup> In contrast to patients with BRVO, patients with CRVO were unable to preserve their initial visual improvements throughout long-term extension studies (Figure 3B).

Therefore, there's now an unmet need for longer-acting drugs that can address the varying intervals between visits and injections that we encounter in the real world.

### Faricimab emerges

Faricimab, a bispecific antibody with a novel mechanism of action that targets angiopoietin-2 and VEGF-A, is being evaluated against aflibercept for macular edema associated with BRVO in the BALATON<sup>21</sup> and CRVO in the COMINO trials.<sup>22</sup> Both studies have two treatment arms:

- faricimab 6 mg given at fixed four-week intervals for 20 weeks (part 1), followed by a personalized treatment interval (PTI) dosing regimen from week 24 to week 72 (part 2); and
- aflibercept 2 mg at four-week intervals through week 20 (part 1), followed by faricimab 6 mg PTI from week 24 through week 72 (part 2).

The primary endpoint for these studies is the average change in BCVA score from baseline through week 24.

Genentech/Roche recently reported topline results that showed both studies met their primary endpoint of noninferior VA gains compared to aflibercept. The trial also reported that faricimab showed rapid drying of retinal fluid, as measured by reduction in central subfield thickness, as well as a safety profile in line with previous trials. Both studies are expected to end in June 2023.

### Tarcocimab

Another novel drug, intravitreal tarcocimab (KSI-301, Kodiak Sciences), is being evaluated for macular edema due to RVO in the BEACON study,<sup>23</sup> estimated to conclude in July 2023. It has 568 participants randomized 1:1 to KSI-301 or aflibercept. Initial results showed that tarcocimab is the first anti-VEGF therapy to show non-inferior VA outcomes with fewer injections than used, on average, in clinical practice.<sup>24</sup>

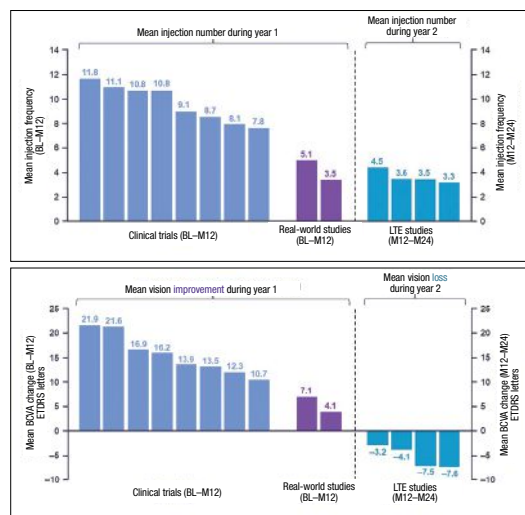
### Bottom line

Patients with macular edema from BRVO and CRVO had considerable BCVA improvements in RCTs during the first year with frequent anti-VEGF injections and frequent monitoring.

In long-term extension studies (months 12 to 24), however, patients with BRVO retained the initial visual gains attained during the clinical trials, but those with CRVO couldn't retain their vision improvements, and their mean BCVA decreased. Patients in real-world studies didn't achieve the same BCVA improvements reported in clinical trials over the first year.

These findings highlight the need for treatments with longer therapeutic action to lessen the treatment burden and the necessity for frequent monitoring and, more specifically, to bring the real-world practice results closer to randomized control trials. There's a recent renewed interest in this endeavor, as evidenced by the ongoing Phase III trials of faricimab, which has already been approved for the treatment of diabetic

(Continued on page 46)



**Figure 3. A) Patients with central retinal vein occlusion who participated in long-term extension (LTE) and real-world evidence studies got fewer injections over 12 months than those who participated in clinical trials. B) In addition, in real-world studies, patients with CRVO achieved lower vision improvements than in clinical trials. Still, in LTE studies, patients didn't retain the initial vision gains seen in clinical trials. (Courtesy Genentech/Roche)**

# Sickle cell retinopathy: An update on management

*Laser photocoagulation is the gold standard, but adjunct anti-VEGF and current and emerging systemic therapies may help improve retinopathy.*

By Loka Thangamathesvaran, MD, and Adrienne W. Scott, MD



Loka Thangamathesvaran, MD



Adrienne W. Scott, MD

## Take-home points

- » Sickle cell disease (SCD) affects 100,000 people in the United States and sickle cell retinopathy (SCR) is the most common cause of vision impairment in these individuals.
- » Laser photocoagulation is the gold standard treatment of proliferative SCR.
- » Off-label anti-VEGF therapy has emerged as an adjunct to scatter laser photocoagulation for SCR and systemic treatments, including hydroxyurea and red blood cell exchange transfusions, may improve SCR.
- » The impact that newer treatments for SCD may have on retinopathy has yet to be evaluated.

**S**ickle cell retinopathy is the most common cause of vision impairment and blindness in individuals with sickle cell disease, which affects 100,000 individuals in the United States, with a global incidence of 300,000 neonates.<sup>1</sup>

Sickle cell disease (SCD) results from a point mutation in the position six of the beta-globin gene of the hemoglobin A molecule and remains the most common inherited disorder. The abnormal hemoglobin (Hb) causes impaired tissue perfusion, resulting in multisystem end-organ damage in affected patients.

Sickle cell retinopathy (SCR) can be defined as the range of retinal vascular changes that result from repetitive vaso-occlusions and ischemia in the retinal microvasculature. SCR is stratified into nonproliferative (NPSR) and proliferative (PSR) subtypes. Sequelae of the latter are the most frequent cause of vision loss in individuals with SCD, typically due to complications from vitreous hemorrhage and/or retinal detachment.

PSR is defined as the presence of pathologic characteristic “sea fan” neovascularization that occurs from progressive retinal ischemia. Given that SCR is part of a larger systemic disease process, studies have identified hemoglobin parameters and systemic biomarkers associated with SCR development.<sup>2,3</sup> Here, we review present management of SCR and existing evidence on how systemic therapies impact the disease.

## Manifestations of SCR

Commonly observed manifestations of NPSR include salmon patch hemorrhages, black sunburst lesions (*Figure 1A*), macular thinning (*Figure 1B*), retinal vaso-occlusions and arterio-venous anastomoses. These findings can be typically monitored without intervention.

PSR can lead to visual impairment and/or blindness from vitreous hemorrhage or retinal detachment. Once PSR is detected, treatment is warranted to prevent progression to vitreous hemorrhage or retinal

## Bios

**Dr. Thangamathesvaran** is a fourth-year resident at Wilmer Eye Institute at Johns Hopkins University School of Medicine, Baltimore.

**Dr. Scott** is an associate professor of ophthalmology at the Wilmer Eye Institute at the Johns Hopkins University School of Medicine, with a clinical research emphasis on sickle cell retinopathy.

**DISCLOSURES:** Dr. Thangamathesvaran and Dr. Scott have no relevant disclosures.

detachment. The gold-standard treatment for PSR remains laser photocoagulation, which barricades sea-fan neovascular complexes and targets transition zones of the peripheral retina between the perfused and nonperfused retina (*Figure 2, page 30*).<sup>4</sup>

### Management of SCR

Although there are no currently established treatment paradigms for using anti-VEGF therapy to treat SCR, off-label use as an adjunct to scatter laser photocoagulation has been shown to be of benefit for several indications. For example, intravitreal bevacizumab (Avastin, Genentech/Roche) has been shown to decrease vascularization of PSR complexes that remain vascularized despite scatter laser treatment.

Intravitreal bevacizumab can hasten vitreous hemorrhage resolution and it's helpful in preventing recurrence of vitreous hemorrhage in PSR.<sup>5</sup> Further, bevacizumab has shown utility as a preoperative medication, allowing for dissection of sea-fan neovascular complexes while minimizing intraoperative bleeding during PSR-related retinal detachment repair.<sup>6</sup>

### Surgery for PSR

Surgery is reserved for advanced PSR and includes non-clearing vitreous hemorrhage, retinal detachment, symptomatic epiretinal membrane, macular hole or vitreomacular traction. The surgical approach in managing patients with SCR can be complex because the peripheral retina is atrophic and thin, making it susceptible to breaks.<sup>7</sup>

### Systemic agents and SCR

Systemic therapies for the management of SCR include red blood cell exchange transfusions and hydroxyurea (Hydrea, Bristol Myers Squibb). These agents reduce total sickle hemoglobin (HbS) red cells to minimize sickling and promote adequate blood flow and tissue perfusion.

Hydroxyurea, the first systemic medication approved for use in SCD, increases the production of fetal Hb (HbF). In patients

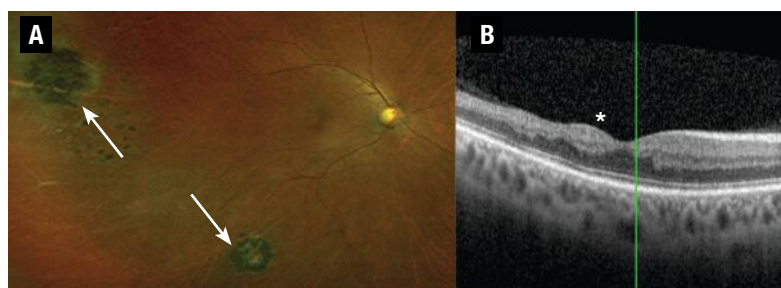
with homozygous HbS disease (HbSS), studies have shown hydroxyurea slows end-organ damage in SCD and decreases the incidence of comorbidities, including vaso-occlusive pain crisis, dactylitis and acute chest syndrome.<sup>8</sup>

A study by Umar Mian, MD, and colleagues noted that the threshold for a 50-percent reduction in SCR is HbF levels of 15 percent.<sup>9</sup> However, this and another study<sup>10</sup> failed to stratify SCR into PSR and NPSR, limiting the conclusions that can be drawn.

Furthermore, hydroxyurea can impact SCR changes on a structural level. A prospective study led by Jennifer Lim, MD, noted decreased rates of macular thinning in patients who received hydroxyurea compared to those with SCD who didn't receive hydroxyurea.<sup>11</sup>

Hydroxyurea may work to improve perfusion, reducing retinal ischemia and retinal thinning.<sup>11</sup> Other work corroborated this hypothesis, documenting decreased intermittent perfusion index (IPI) on optical coherence tomography angiography two months following initiation of hydroxyurea in a patient with HbSS disease (*Figure 3, page 31*).<sup>12</sup>

Red blood cell exchange transfusions are routine for systemic SCD, and have decreased the frequency of vaso-occlusive pain crises, stroke and silent cerebral infarctions.<sup>13</sup> Anecdotal case reports have demon-



**Figure 1. A)** Ultra-widefield fundus photograph of a patient with homozygous sickle cell disease (HbSS) with peripheral pigmentary changes consistent with black sunburst lesions (white arrows) depicting mild nonproliferative sickle cell retinopathy (SCR). **B)** Spectral-domain optical coherence tomography of a patient with HbSS showing macular thinning most pronounced temporally, corresponding to the watershed zone most susceptible to ischemia in SCR (asterisk).

strated that exchange transfusions may halt PSR progression. However larger, systematic clinical studies are lacking.<sup>10,14</sup>

### Systemic therapy pros and cons

Challenges with systemic use of hydroxyurea exist. Animal studies have suggested that hydroxyurea is teratogenic and can predispose young patients to developmental anomalies, including neural tube defects, digit hypoplasia and craniofacial defects. However, these findings haven't been reproduced in human studies.<sup>15</sup>

Some patients experience neutropenia, hair loss, fingernail darkening and nausea with hydroxyurea use.<sup>16</sup> Furthermore, hydroxyurea adherence rates as low as 30 percent have been reported. The most-cited reasons include difficulty remembering to take the medication, doubting its effectiveness and concerns about side effects.<sup>17</sup> Nonetheless, data showing benefits of hydroxyurea significantly outweigh the reported potential side effects.

One analysis reported that hydroxyurea was associated with a 40-percent reduction in mortality in patients with HbSS disease.<sup>18</sup>

Red blood cell exchange transfusions, although their role in SCR management is unclear, are used regularly in the management of systemic complications of HbSS. Indications for red cell transfusions include acute stroke, acute chest syndrome and multiorgan failure.<sup>18</sup> These acute risks are similar to those seen with other transfusions, including the possibility of blood transmissible disease, blood clots and alterations in blood electrolytes. Risks associated with chronic transfusions include iron overload, which can be mit-

igated with chelation.<sup>18</sup>

### Curative therapies for SCD

Hematopoietic stem cell bone marrow transplantation (BMT) and gene therapy are two novel modalities that present promising, potentially curative treatments to SCD.

The process for marrow transplant first includes chemotherapy, which is used to remove patient's native stem cells, with busulfan being the most commonly used agent. Then the patient's bone marrow is replaced with matched donor stem cells and the patient simultaneously receives graft versus host disease (GVHD) prophylaxis with systemic immunosuppressants to prevent rejection.

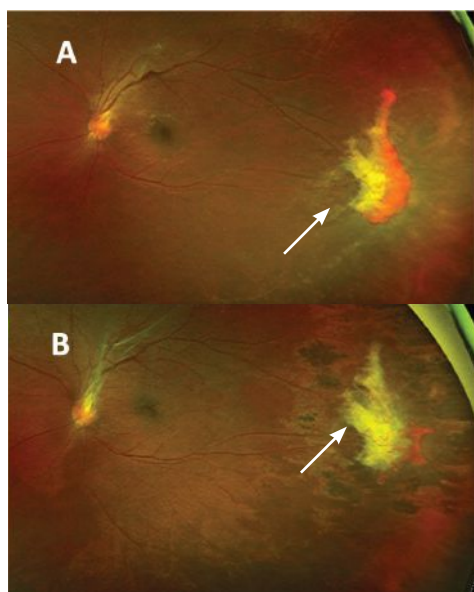
However, challenges with BMT include finding a donor match, GVHD and toxicity from immunosuppressive medications, including secondary malignancy and infertility.<sup>19</sup>

### The potential of gene therapy

The second potentially curative modality is gene therapy. Gene modification mechanisms include:

- gene addition, which involves using a viral vector to deliver a nonsickling globin gene to stem cells;
- gene editing, which involves gene disruption by binding to a certain element of a gene and inducing double stranded breaks;
- gene silencing by preventing expression of certain proteins; and
- gene correction, which uses RNA as a vector to identify mutations and a template DNA to correct the mutation.

Gene therapy also carries significant potential risks, including infertility in the myeloblastosis process, and the potential for myelodysplastic syndromes and secondary malignancy.<sup>20</sup> Although both BMT and gene therapy are promising, their large-scale application is limited. It will be interesting to evaluate how these modalities impact microvasculature circulation patterns and SCR progression.



**Figure 2. A) Ultra-widefield fundus photography of a patient with sickle cell hemoglobin C shows peripheral retinal neovascularization representing sea-fan lesions seen in proliferative sickle cell retinopathy before treatment. B) After treatment with laser photocoagulation, the sea-fan neovascular complex shows partial regression after scatter laser treatment.**

## Differences in SCD variants

Both HbSS and sickle cell Hb C (HbSC) disease can present with similar systemic and ocular manifestations. Although HbSS disease is associated with more severe systemic complications, vision-threatening proliferative sickle cell retinopathy is more common in HbSC disease.<sup>21</sup>

The difference in retinopathy between HbSS and HbSC genotypes isn't completely understood. One hypothesis for increased PSR in HbSC is the partial occlusion of retinal microvasculature resulting in a chronic, steady hypoxic state promoting vaso-proliferation in contrast to the complete vaso-occlusion seen during sickling events in HbSS disease.<sup>22</sup>

Differences in pathophysiologic disease processes between HbSC and HbSS suggest that isolated studies evaluating systemic agents to prevent retinopathy in HbSC patients would be beneficial because findings from one disease process can't be directly applied to the other.<sup>23</sup>

## More PSR, macular thinning

In addition to experiencing a higher incidence of vision-threatening PSR, patients with HbSC disease also have higher rates of macular thinning than their HbSS counterparts and the lowest rates of hydroxyurea therapy.<sup>11</sup>

This difference can be attributed to current practice patterns, because hydroxyurea isn't part of the standard systemic treatment paradigm for HbSC. Larger-scale clinical studies would help to evaluate hydroxyurea as an agent to mitigate the effects of PSR in HbSC patients.<sup>11,24</sup>

Although studies have noted that baseline Hb greater than 12.5 g/dl and HbF are risk factors for PSR, and exchange transfusions may minimize retinopathy development in HbSS, few studies in HbSC disease describe systemic interventions to prevent PSR. Similar to hydroxyurea, case reports have identified the use of transfusions to improve PSR in patients with HbSC-associated SCR, but large-scale analyses are limited.<sup>13</sup>

## Future therapies

New systemic agents for SCD include:

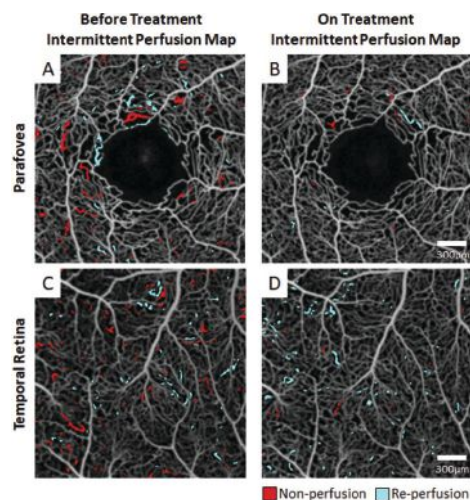
- **Crizanlizumab** (Adakveo, Novartis), a monoclonal antibody that inhibits the interaction of P-selectin glycoprotein ligand and thrombin reducing vaso-occlusion and thrombosis. Preliminary randomized controlled trial results noted lower crisis events and decreased median time to the first crisis with its use.<sup>25</sup>
- **Voxelotor** (Oxbryta, Global Blood Therapeutics), a HbS polymerization inhibitor that reversibly binds to Hb to stabilize the oxygenated Hb state. Phase III randomized trials have shown increased Hb levels and reduced hemolysis markers in SCD patients.<sup>26</sup>
- **Amino acid L-glutamine** (Endari, Emmaus Medical), a pharmaceutical grade 1 glutamine that increases the proportion of nicotinamide adenine dinucleotide, an antioxidant molecule that, in a multicenter, Phase III trial has been shown to reduce the median number of pain crises.<sup>27</sup>

Although these agents have yet to be evaluated in SCR, their systemic benefits suggest possible benefits for retinal perfusion, with potential alterations in future SCR treatment paradigms.<sup>28</sup>

## Bottom line

SCR is the most common cause of vision impairment in people with SCD, and while laser photocoagulation is the gold standard for PSR, off-label bevacizumab has been

(Continued on page 46)



**Figure 3.** A treatment-naïve sickle cell patient with homozygous hemoglobin sickle cell disease (HbSS) genotype was imaged at an initial visit (left column) and again after two months of hydroxyurea treatment (right column). Before treatment, the patient exhibited between-session intermittent perfusion index (IPI) of 3 and 2.7 percent, respectively, at the (A) parafovea and (C) temporal retina. After two months of hydroxyurea, the between-session IPI was reduced to 0.5 and 1.6 percent, respectively, at the (B) parafovea and (D) temporal retina. (New York Eye and Ear Infirmary of Mount Sinai)

# Lessons from MEAD: The potential for reversing DR

*The dexamethasone implant has shown efficacy in diabetic macular edema, but more recent evidence shows a signal for reversing diabetic retinopathy.*

By Maxwell J. Wingelaar, MD, and Kevin J. Blinder, MD



Maxwell J.  
Wingelaar, MD



Kevin J. Blinder, MD

## Take-home points

- » The intravitreal dexamethasone (DEX) implant is not only helpful in reducing central retinal thickness in diabetic macular edema, but also in improving best-corrected visual acuity.
- » Reversal of the diabetic retinopathy severity level may be achievable with the DEX implant in some patients.
- » Phakic eyes treated with the DEX implant are at greater risk of cataract development. Intraocular pressure must be monitored carefully in both phakic and pseudophakic eyes.
- » DEX implants serve as a useful tool in our armamentarium for the treatment of DME. Patients with refractory DME may also benefit significantly.

In treating patients with diabetic macular edema, vascular endothelial growth factor is a popular target and anti-VEGF agents have proven to be very effective at both reducing the degree of DME and improving visual acuity. Corticosteroids also are a sensible agent to use in these patients, given the cascade of proinflammatory cytokines involved with DME. However, the challenge with corticosteroids has been in delivering the medication in the appropriate way to achieve a desirable therapeutic result.

The intravitreal dexamethasone implant (DEX, Ozurdex, Allergan/AbbVie) has overcome many of these challenges, as we learned from the MEAD trial conducted in 2014.<sup>1</sup> More recently, our own retrospective analysis of MEAD data demonstrated that the DEX implant has the potential for reducing the severity of diabetic retinopathy and halting or slowing disease progression.<sup>2</sup> Here, we report on what our retrospective analysis found and review some important

lessons from MEAD about the efficacy of DEX in these patients.

## Challenges of corticosteroid therapy

We've known that topical corticosteroid agents can be effective, but they don't always penetrate to the retina to yield an adequate response. Systemic steroids have their own set of risks, the largest being disruption of a patient's glycemic status to a dangerous level.

A sustained-release intravitreal steroid implant allows for direct delivery to the posterior segment, which can offer a prolonged reduction in retinal inflammatory markers and go a long way toward reigning in uncontrolled DME in the right patient.<sup>3,4</sup> The MEAD trial thoroughly investigated using the DEX implant in DME.

## MEAD takeaways

MEAD, done in 2014, evaluated the safety and efficacy of the dexamethasone intravitreal implant with dosages of 0.7 mg and

## Bios

**Dr. Wingelaar** is a vitreo-retinal surgery fellow at The Retina Institute, St. Louis.

**Dr. Blinder** is a partner at The Retina Institute and professor of clinical ophthalmology and visual sciences at Washington University, St. Louis.

**DISCLOSURES:** Dr. Wingelaar has no relevant financial disclosures.

**Dr. Blinder** disclosed relationships with Bausch + Lomb, Regeneron Pharmaceuticals, Genentech, Allergan/AbbVie, Aldeyra Therapeutics, Diopsys, Novo Nordisk and Biogen.



0.35 mg in the treatment of DME.<sup>1</sup> The study included patients with a diagnosis of DME for a mean duration of 24.9 months with a baseline visual acuity of 20/50 to 20/200 and a central retinal thickness  $\geq 300$   $\mu\text{m}$ , as measured with optical coherence tomography.

Study patients had previously been treated with medical or laser therapy. MEAD was designed as two randomized, multicenter, sham-controlled Phase III trials with identical protocols. With three years of follow-up, the study yielded a wealth of data on the effectiveness of the DEX implant.

Over the study course, both the 0.7- and 0.35-mg DEX implants proved to be superior to sham for achieving the primary study endpoint, defined as improvement in best-corrected visual acuity by  $\geq 15$  letters from baseline. Not only was this clinically significant; it was statistically significant.

A larger percentage of patients receiving the 0.7-mg implant reached the primary study endpoint than those receiving the 0.35-mg implant—22.2 vs. 18.4 percent.<sup>1</sup> After initial treatment, retreatment in MEAD patients was restricted to no more than every six months. This helped to demonstrate the durability of the implant.

### DR regression

Our own retrospective analysis of the MEAD data explored the effects of the DEX implant on Diabetic Retinopathy Severity Scale (DRSS) levels,<sup>2</sup> which other trials in DME have used to measure disease progression.

We found the DEX implant has the potential to reduce the DRSS and halt or slow disease progression. We evaluated patients improving one or two steps in DRSS score and converting between nonproliferative and proliferative DR. Patients treated with the DEX implant showed a one-step im-

provement in DRSS scores about two months sooner than sham patients.

Additionally, the DEX implant group achieved a two-step improvement in DRSS score about 1.5 months sooner than the sham group. These findings were statistically significant.

Interestingly enough, when looking at time to conversion from NPDR to PDR, patients who had the DEX implant had a delayed conversion time to PDR by two months compared to sham. The treatment arm also demonstrated a regression from PDR to NPDR 1.5 months faster than those in the sham group.<sup>2</sup> These results continue to support the utility and benefit of the DEX implant for patients with DME and severe DR.

### Putting it into practice

Keeping these data in mind, the DEX implant can be a powerful tool when implemented properly. Patients with DME refractory to anti-VEGF therapy or those who aren't candidates for anti-VEGF therapy may benefit significantly from intravitreal corticosteroid therapy with the DEX implant, especially pseudophakic patients.<sup>5-9</sup>

Of course, not all patients will be candidates for the DEX implant, especially if they have a history of glaucoma or have demonstrated an IOP response to prior corticosteroids.

Before inserting the DEX implant, consider first treating the patient with a course of topical steroids to evaluate their risk of a steroid response.

Typically, we treat a patient with a topical corticosteroid for about six weeks before initiating intravitreal corticosteroid therapy. This has the added benefit of possibly demonstrating an improvement in macular edema with topical agents alone, although this response tends to be less than what we would see with the DEX implant.

It's also critical to discuss with the

## The growing burden of DME

**D**ME is one of the most common ailments that we face. It can be burdensome to patients and have a significant impact on their quality of life. As the population continues to age and obesity continues to be a problem, both diabetes and diabetic macular edema will increasingly affect our patients.<sup>18</sup>

The pathogenesis occurs through alteration of the blood-retinal barrier (BRB), characterized by pericyte loss and endothelial cell-to-cell junction breakdown. With a weakened BRB, other systemic conditions can further the development of DME.

Hypertension, heart failure and renal failure are all common comorbidities in patients with diabetes. Both inflammation and oxidative stress also contribute by causing an increase in cytokines and growth factors such as VEGF, angiopoietins, tumor necrosis factor, interleukins and matrix metalloproteinases.<sup>19</sup> These factors augment the breakdown of the BRB even further and lead to DME.<sup>14,20</sup> The identification of these factors allows for selective therapeutic targets to treat DME.

— M.J.W., K.J.B

patient the potential for an IOP increase and cataract development.<sup>10,11</sup> In pseudophakic patients, the cataract risk is mitigated, so the DEX implant may be an even more favorable option.<sup>12</sup> We've seen dramatic improvements in patients' macular edema when treated with the implant. They also benefit from a reduction in treatment burden due to the implant's sustained-release mechanism.<sup>13,14</sup>

We demonstrate one such case (*Figure*), which shows serial OCTs of a patient before getting the DEX implant and six weeks afterward. This patient's central foveal thickness improved from 460 to 210  $\mu\text{m}$  and visual acuity improved from 20/50 to 20/30 Snellen equivalent. This patient was minimally responsive to previous anti-VEGF therapy, but tolerated the DEX implant well and didn't go on to develop an IOP response.

### Our DEX protocol

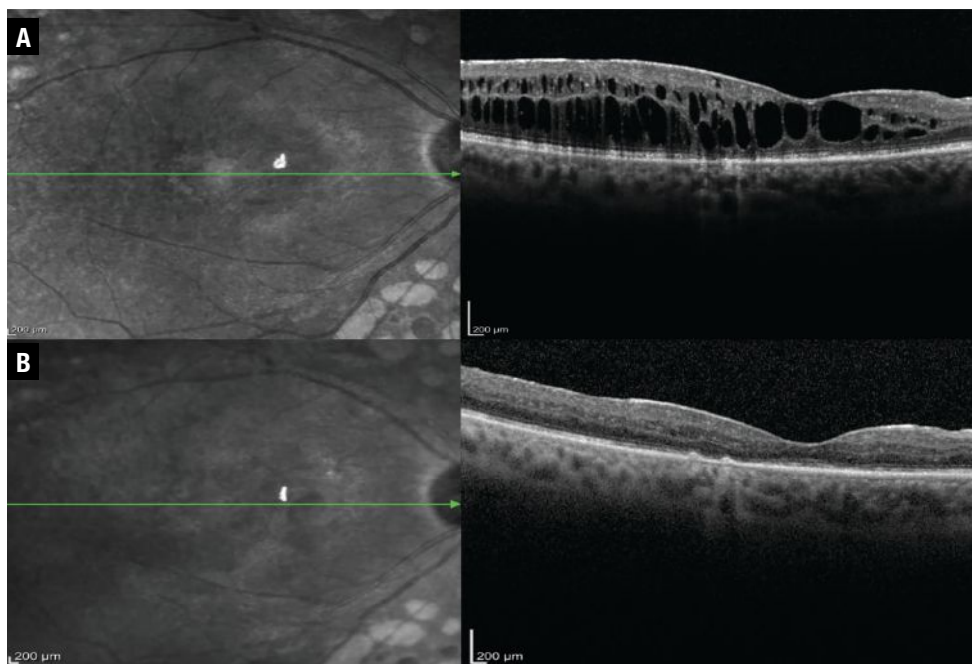
In our practice the DEX implant is a powerful tool when treating DME. When a new patient presents with visually significant

macular edema, we start with anti-VEGF therapy or topical corticosteroid drops. In milder cases, we lean toward topical corticosteroid therapy. We monitor the patient closely and bring them in at approximately six weeks to assess their treatment response.

With anti-VEGF therapy, we give patients one or two more injections, depending on their response. If the macular edema exhibits little to no response, we either give another anti-VEGF injection or start the patient on topical drops along with an additional anti-VEGF injection. At this visit, we also discuss the DEX implant with the patient as a treatment option.

The patient comes back in six to eight weeks and if the treatment response remains suboptimal and their IOP hasn't shown a response to the topical corticosteroids, we start treatment with the DEX implant. The patient returns again in six to eight weeks, when we evaluate the treatment response, paying careful attention to the patient's IOP to ensure a significant elevation hasn't occurred.

Patients who have been on long-term anti-VEGF therapy may develop a refractory response to continued treatment. In these instances, the DEX implant also proves to be a valuable treatment option. We manage these patients in a similar fashion: with a trial of topical corticosteroids to assess IOP response and then the DEX implant on follow-up. We can give them supplemental anti-VEGF therapy concurrently to optimize their treatment response and reduce DME. The sustained-release therapy that the DEX implant provides is a significant advantage, as one injection leads to continued control with



**In this patient treated with the dexamethasone intravitreal implant patient, central foveal thickness, as evaluated on optical coherence tomography, improved from (A) 460  $\mu\text{m}$  before treatment with the DEX implant to (B) 210  $\mu\text{m}$  afterward.**

supplemental therapy available for breakthrough edema.

## Managing cataract, IOP outcomes

Cataract development and IOP increase were the primary adverse events in MEAD patients treated with the DEX implant. Some patients ended up losing vision after one year due to the development of cataract, but then had their vision restored following cataract extraction.

Despite cataract formation, at year three study patients receiving the DEX implant had significant improvement in BCVA over the sham group, which indicated that even with a cataract these patients still do well.

In fact, having the DEX implant on board seemed to yield a protective effect against an increase in DME following cataract surgery.<sup>15</sup> Upon subgroup analysis, the 0.7-mg implant, currently the marketed dose, proved to be more effective in treating DME, with a safety profile similar to the 0.35-mg device.<sup>16</sup>

Patients receiving the DEX implant were more likely to have an IOP increase  $\geq 10$  mmHg than the sham group—27.7 percent in the 0.7-mg group vs. 24.9 percent in the 0.35-mg group. Fortunately, topical medications controlled IOP in most of these patients. Only three patients—two in the 0.7-mg group and one in the 0.35-mg group—required incisional surgery to correct their IOP rise.

Thus, MEAD provided supportive evidence for the use of the DEX implant in the management of DME. Up to one-third of trial patients achieved vision of 20/40 or better after their first treatment, which appeared to be sustained after correcting for the confounding effect of cataract development.<sup>1,17</sup>

## Bottom line

DME poses a significant burden to a large number of patients. Early intervention with the DEX implant can significantly reduce the degree of macular edema, improve visual acuity and potentially scale back the

degree of DR, while at the same time reducing the treatment burden of frequent intravitreal injections. <sup>CS</sup>

## REFERENCES

1. Boyer DS, Yoon YH, Belfort R, et al. Three-year, randomized, sham-controlled trial of dexamethasone intravitreal implant in patients with diabetic macular edema. *Ophthalmology*. 2014;121:1904-1914.
2. Blinder K, Wykoff C, Ferencz J, et al. Dexamethasone implant appears to slow diabetic retinopathy progression: A retrospective analysis of the MEAD study. Paper presented at The Retina Society 54th annual scientific meeting; Chicago, IL; September 29, 2021.
3. Browning D, Stewart M, Lee C. Diabetic macular edema: Evidence-based management. *Indian J Ophthalmol*. 2018;66:1736-1750.
4. Figueira J, Henriques J, Carneiro A, et al. Guidelines for the management of center-involving diabetic macular edema: Treatment options and patient monitoring. *Clin Ophthalmol*. 2021;15:3221-3230.
5. Ehlers JP, Yeh S, Maguire MG, et al. Intravitreal pharmacotherapies for diabetic macular edema. *Ophthalmology*. 2022;129:88-99.
6. Teja S, Sawatzky L, Wiens T, Maberley D, Ma P. Ozurdex for refractory macular edema secondary to diabetes, vein occlusion, uveitis and pseudophakia. *Can J Ophthalmol*. 2019;54:540-547.
7. Wang JK, Huang TL, Hsu YR, Chang PY. Effect of dexamethasone intravitreal implant for refractory and treatment-naive diabetic macular edema in Taiwanese patients. *J Chin Med Assoc*. 2021;84:326-330.
8. Al-Latayfeh M, Abdel Rahman M, Shatnawi R. Outcome of single dexamethasone implant injection in the treatment of persistent diabetic macular edema after anti-VEGF treatment: Real-life data from a tertiary hospital in Jordan. *Clin Ophthalmol*. 2021;15:1285-1291.
9. Neves P, Ornelas M, Matias I, et al. Dexamethasone intravitreal implant (Ozurdex) in diabetic macular edema: Real-world data versus clinical trials outcomes. *Int J Ophthalmol*. 2021;14:1571-1580.
10. Schwartz S, Scott I, Stewart M, Flynn Jr. H. Update on corticosteroids for diabetic macular edema. *Clin Ophthalmol*. 2016;10:1723-1730.
11. Urbani M, Topcic IG, Matovic K. Visual outcomes in patients with diabetic macular edema treated with dexamethasone implant in routine clinical practice. *Acta Clin Croat*. 2021;60:602-608.
12. Karti O, Saatci AO. Place of intravitreal dexamethasone implant in the treatment armamentarium of diabetic macular edema. *World J Diabetes*. 2021;12:1220-1232.
13. Nicolò M, Musetti D, Marengo M, et al. Real-life management of diabetic macular edema with dexamethasone intravitreal implant: A retrospective analysis of long-term clinical outcomes. *J Ophthalmol*. 2020;4860743.
14. Chawan-Saad J, Wu M, Wu A, Wu L. Corticosteroids for diabetic macular edema. *Taiwan J Ophthalmol*. 2019;9:233-242.
15. He Y, Ren XJ, Hu BJ, Lam WC, Li XR. A meta-analysis of the effect of a dexamethasone intravitreal implant versus intravitreal anti-vascular endothelial growth factor treatment for diabetic macular edema. *BMC Ophthalmol*. 2018;18:121.
16. Augustin AJ, Kuppermann B, Lanzetta P, et al; for the Ozurdex MEAD Study Group. Dexamethasone intravitreal implant in previously treated patients with diabetic macular edema: Subgroup analysis of the MEAD study. *BMC Ophthalmol*. 2015;15:150.
17. Danis RP, Sada S, Li XY, Cui H, Hashad Y, Whitcup SM. Anatomical effects of dexamethasone intravitreal implant in diabetic macular oedema: a pooled analysis of 3-year Phase III trials. *Br J Ophthalmol*. 2016;100:796-801.
18. Tan GS, Cheung N, Simó R, Cheung GCM, Wong TY. Diabetic macular oedema. *Lancet Diabetes Endocrinol*. 2017;5:143-155.
19. Noma H, Yasuda K, Shimura M. Involvement of cytokines in the pathogenesis of diabetic macular edema. *Int J Mol Sci*. 2021;22:3427.
20. Das A, McGuire PG, Ranganamy S. Diabetic macular edema: Pathophysiology and novel therapeutic targets. *Ophthalmology*. 2015;122:1375-1394.

**Despite cataract formation, at year three study patients receiving the DEX implant had significant improvement in BCVA over the sham group, which indicated that even with a cataract, these patients still do well.**

# How AI may impact retinal practice

*Artificial intelligence has shown potential for helping us to manage the multitudes with geographic atrophy and diabetes.*

By Yavuz Cakir, MD, and Justis P. Ehlers, MD



Yavuz Cakir, MD



Justis P. Ehlers, MD

## Bios

**Dr. Cakir** is a research fellow at The Tony and Leona Campana Center for Excellence in Image-Guided Surgery and Advanced Imaging Research, Cole Eye Institute, Cleveland Clinic, Cleveland.

**Dr. Ehlers** holds the Norman C. and Donna L. Harbert Endowed Chair for Ophthalmic Research and is director of the Tony and Leona Campana Center for Excellence in Image-Guided Surgery and Advanced Imaging Research at the Cole Eye Institute.

**DISCLOSURES:** Dr. Cakir has no relevant relationships to disclose.

**Dr. Ehlers** reported relationships with Novartis, Zeiss, Leica, Beyeonics, Alcon, Allergan/AbbVie, Adverum, Oxurion, Roche, Allegro, Stealth, RegenxBio, Iveric bio, Boehringer-Ingelheim, Apellis and Regeneron Pharmaceuticals.

## Take-home points

- » A growing population at-risk for retina-related disease and the need for precision management of these patients may be importantly augmented through the use of artificial intelligence (AI)-based technology.
- » Advancing imaging methods have expanded retinal disease data acquisition, leading to the potential for new biomarkers, which AI-integrated systems have the potential to detect, quantify and extract.
- » AI is currently used in retinal screening and may allow for individualized management in the future.

**A**rtificial intelligence is the ability for a computer system to learn, adapt, and perform complex tasks in a way that mimics rational thinking. Machine learning is a subset of AI (*Figure 1*). Advancements in machine learning, the process by which algorithms and machines learn from experience, have allowed for dramatic improvements in the deployment of AI within ophthalmology and the study of retinal diseases.

One of the significant developments in machine learning was the neural network, which is a series of numeric matrices of connected nodes that interact in such a way that allow for complex computations with hidden tunable layers that could adjust the connections between nodes (*Figure 2*). These networks are generally computationally taxing, but adept at capturing complex non-linear relationships. As computational power and graphics cards have exploded in capacity and potential, the size and depth of neural networks has greatly increased, resulting in deeper networks that became capable of

recognizing increasingly abstract patterns.

The complexity, accuracy, and abstract pattern recognition of neural networks has become powerful enough to rival human performance on an increasingly wide and difficult range of tasks. The impressive performance of these deeply constructed neural networks has consequently created an entire technical research field dedicated to developing and understanding them, including deep learning (DL). DL algorithms are the most capable way to handle complex tasks, and they comprise the majority of AI work done today.

## AI applications in retina

The retina subspecialty is particularly well-suited to AI deployment and exploration due to the ease of acquisition of medically relevant images and data. This, combined with an aging global population that's increasingly diagnosed with chronic diseases, suggests a major opportunity for the expansion of AI research in retinal medicine.

According to a 2014 World Health Orga-

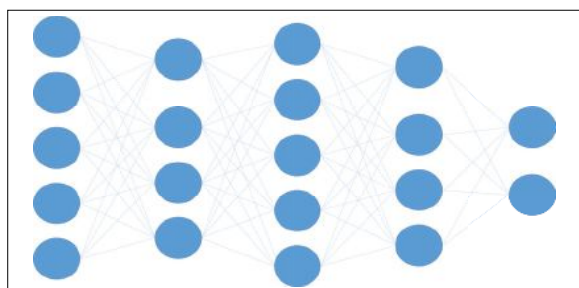
nization study, the number of AMD patients in 2040 is expected to reach 288 million globally.<sup>1</sup> Diabetes mellitus has a global prevalence varying between 2 and 12 percent.<sup>2</sup> In real-world studies, one of three patients with diabetes has diabetic retinopathy, and one of every three patients with DR has vision-threatening retinopathy.<sup>3</sup>

Given the large number of people affected by these diseases and the potential to better understand and diagnose these diseases using AI, it's worthwhile to understand specific applications of AI in ophthalmology.

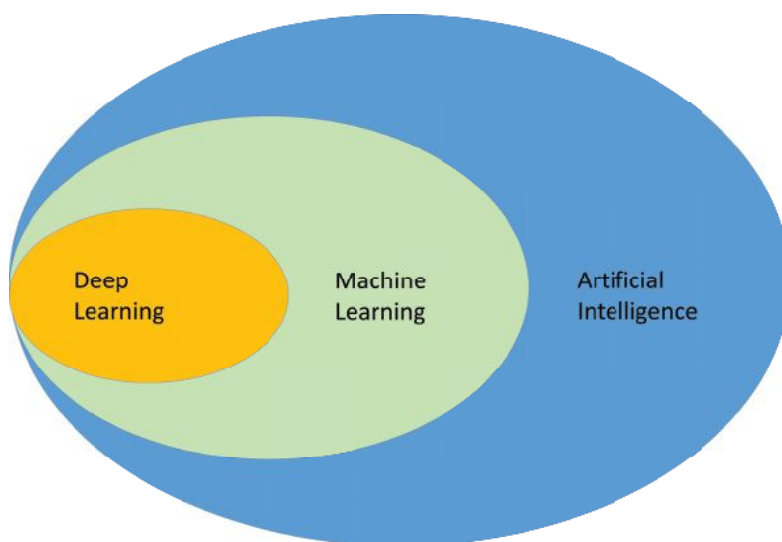
### AI in AMD

While there's no Food and Drug Administration-approved treatment for dry age-related macular degeneration,<sup>4</sup> multiple therapies in clinical trials have demonstrated promising initial results. However, as our treatment paradigms expand to include dry AMD, multiple new challenges in the detection and monitoring of this highly prevalent disease will emerge.

We'll need risk stratification of dry AMD cases to accurately identify eyes at risk for disease progression, to predict eyes most likely to benefit from therapy and to potentially maximize clinical trial enrichment. Optimizing the precision approach to the management of dry AMD will help facilitate the treatment of patients at greatest risk for progression and help identify eyes that could benefit from therapy.



**Figure 2. A convolutional neural network (CNN) is a network architecture for deep learning that learns directly from data. A CNN, like other neural networks, is made up of an input layer, an output layer and several hidden layers in between. These layers conduct operations on the data with the goal of learning data-specific attributes.**



**Figure 1. How artificial intelligence, machine learning and deep learning relate to each other. Deep learning is a subset of machine learning, which is a subset of AI.**

Performing effective, rapid risk stratification in a growing and aging population requires rapid, inexpensive and accurate diagnostics. AI-enabled systems are well-suited to address these concerns. Imaging techniques, such as optical coherence tomography, fundus autofluorescence and OCT angiography, can rapidly generate detailed data of sufficient quantities to train AI systems to identify medically useful biomarkers and automate disease characterization (*Figure 3, page 38*). Incorporating this information and automated detection into standard-of-care medical software platforms allows for scalable longitudinal monitoring, providing valuable feedback on treatment results.

Numerous imaging biomarkers have been studied in non-neovascular AMD, including intraretinal hyperreflective foci (HRF), complex drusenoid lesions (DL, i.e., heterogeneous reflectivity), subretinal drusenoid deposits (SDDs) and drusen burden.<sup>5,6</sup> Predicting GA development and progression is a key area of research focus.<sup>7-10</sup> A recent study found that ellipsoid zone integrity and quantitative characterization of the subretinal

pigment epithelium compartments have high predictive value in the progression to subfoveal GA.<sup>11</sup>

In neovascular AMD, feature assessment and accurate characterization of fluid is important for maximizing disease control and outcomes. OCT is the gold standard for monitoring and identifying fluid features. Historically, fluid features were generally evaluated in a binary fashion (i.e., presence/absence of a specific fluid of interest).

With the advent of AI-enabled systems, extensive characterization of fluid in nAMD is now feasible, including fluid volume analysis and specific fluid type classification. Volumetric fluid characterization, fluid dynamics and exudative volatility, and volumetric quantification of subretinal fibrosis and hyperreflective material have all been established in several studies.<sup>12-14</sup>

Overall, many potential opportunities exist for the deployment and integration of AI-based tools for the management of AMD.

### AI in DR

Studies anticipate that by 2030 450 million people will have diabetes worldwide—150 million with mild DR and about 30 million with diabetic macular edema.<sup>15,16</sup> While DR is treatable, slow and expensive screening can be a major barrier when treating large populations. AI is well positioned to make significant improvements in these screening processes while integrating into holistic platforms designed to coordinate with treatments for other complications typically resulting from diabetes.<sup>17</sup>

One example of merging diabetic retinopathy screening with AI is IDx-DR (Digital Diagnostics), the first FDA-approved autonomous device employing artificial intelligence software.<sup>18</sup> A pivotal trial of 900 patients reported device sensitivity and specificity for diabetes detection were 87.4 and 89.5 percent, respectively.

If the software detects severe DR, the patient is referred to an eye-care professional. If the software doesn't detect severe or moderate DR, the patient is directed to rescreen in a year. The study reported that DR screening has successfully referred individuals with DR symptoms over specific thresholds to specialized facilities.<sup>18</sup> The idea is to reduce patient burden on tertiary centers, allowing providers to spend more time with patients who need advanced care.

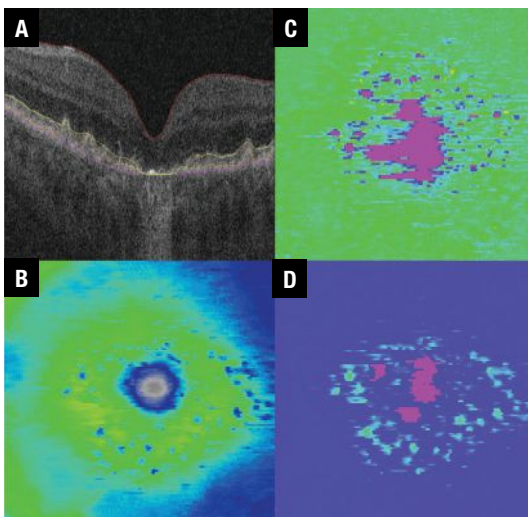
While anti-VEGF therapy is widely used to treat DME, retinal specialists disagree on the ideal treatment frequency or duration, or which patients will respond, resulting in expensive and potentially more frequent treatment than needed.

Deep-learning algorithms might be able to recognize new features undetectable by the human eye and incorporate existing complex biomarkers, such as ultra-wide-field fluorescein angiography biomarkers (nonperfusion area, ischemic index, leakage and microaneurysm counts).<sup>19,20</sup> These algorithms have also recognized the following OCT biomarkers (Figure 4):<sup>21-26</sup>

- central subfield thickness and disorganization of retinal inner layers (DRIL);
- hyperreflective foci;
- ellipsoid zone integrity;
- retinal fluid index; and
- retinal fluid volatility.

These markers have been shown to correlate with DR severity. Many of these parameters, such as quantitative UWFA parameters, including panretinal MA count, ischemia and leakage index, have been strongly associated with DR severity.<sup>20</sup>

As with AMD, the rapid proliferation of new and emerging therapies provides a unique need and opportunity for optimizing



**Figure 3.** Retinal tissue thickness maps for a patient with non-neovascular age-related macular degeneration include A) B-scan with inner limiting membrane, retinal pigment epithelium, ellipsoid zone and Bruch's membrane line segmentation; B) ILM-RPE thickness map; C) EZ-RPE thickness map; and D) RPE-Bruch's membrane thickness map.

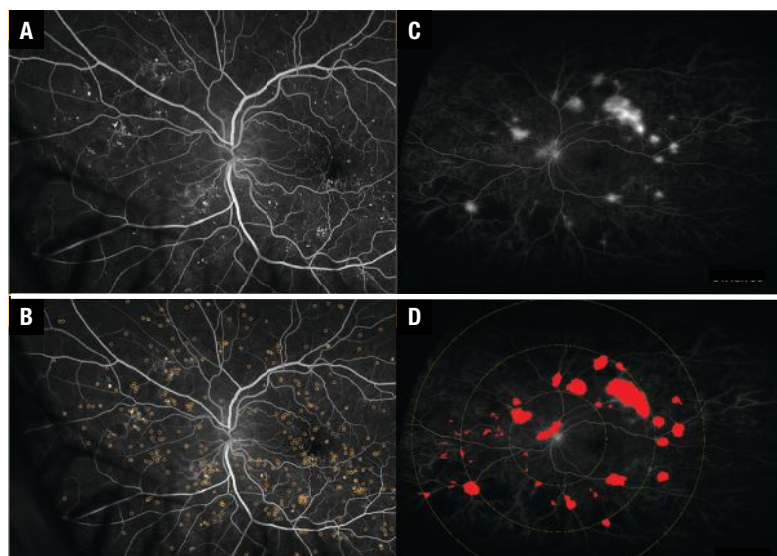
treatment decision-making using a precision-based approach. AI-enabled systems that provide insights into therapeutic response and prognosis may enhance not only screening and diagnosis, but may also help to optimize the actual treatment for a given patient.

## Bottom line

AI is poised to expand dramatically in the coming years, given the growing population of patients with ophthalmic needs may overwhelm traditional methods for screening and chronic disease follow-up. AI-enabled systems may help mitigate some of these challenges by efficiently managing large amounts of data and having the unique ability to extract key features relevant to disease management, including identifying key imaging biomarkers. <sup>RS</sup>

## REFERENCES

1. Wong WL, Su X, Li X, et al. Global prevalence of age-related macular degeneration and disease burden projection for 2020 and 2040: A systematic review and meta-analysis. *Lancet Glob Health*. 2014;2:e106-116.
2. Sabanayagam C, Banu R, Chee ML, et al. Incidence and progression of diabetic retinopathy: A systematic review. *Lancet Diabetes Endocrinol*. 2019;7:140-149.
3. Lee R, Wong TY, Sabanayagam C. Epidemiology of diabetic retinopathy, diabetic macular edema and related vision loss. *Eye Vis (Lond)*. 2015;2:17.
4. Handa JT, Bowes Rickman C, Dick AD, et al. A systems biology approach towards understanding and treating non-neovascular age-related macular degeneration. *Nat Commun*. 2019;10:3347.
5. Toth CA, Tai V, Chiu SJ, et al. Linking OCT, angiographic, and photographic lesion components in neovascular age-related macular degeneration. *Ophthalmol Retina*. 2018;2:481-493.
6. Nassisi M, Lei J, Abdelfattah NS, et al. OCT risk factors for development of late age-related macular degeneration in the fellow eyes of patients enrolled in the HARBOR study. *Ophthalmology*. 2019;126:1667-1674.
7. Bogunovic H, Montuoro A, Baratsits M, et al. Machine learning of the progression of intermediate age-related macular degeneration based on OCT imaging. *Invest Ophthalmol Vis Sci*. 2017;58:BI0141-BI0150.
8. Hirabayashi K, Yu HJ, Wakatsuki Y, Marion KM, Wykoff CC, Sadda SR. Optical coherence tomography risk factors for development of atrophy in eyes with intermediate age-related macular degeneration. *Ophthalmol Retina*. 2022;S2468-6530 (22) 00486-9.
9. Riedl S, Vogl WD, Mai J, et al. The effect of pegcetacoplan treatment on photoreceptor maintenance in geographic atrophy monitored by artificial intelligence-based OCT analysis. *Ophthalmol Retina*. 2022;S2468-6530 (22)00285-8.
10. Niu S, de Sisternes L, Chen Q, Rubin DL, Leng T. Fully automated prediction of geographic atrophy growth using quantitative spectral-domain optical coherence tomography biomarkers. *Ophthalmology*. 2016;123:1737-1750.
11. Sarici K, Abraham JR, Sevgi DD, et al. Risk classification for progression to subfoveal geographic atrophy in dry age-related macular degeneration using machine learning-enabled outer retinal feature extraction. *Ophthalmic Surg Lasers Imaging Retina*. 2022;53:31-39.
12. Ehlers JP, Patel N, Kaiser PK, et al. The association of fluid volatility with subretinal hyperreflective material and ellipsoid zone integrity in neovascular AMD. *Invest Ophthalmol Vis Sci*. 2022;63:17.
13. Ehlers JP, Zahid R, Kaiser PK, et al. Longitudinal assessment of ellipsoid



**Figure 4. A,B) Early fluorescein angiography shows microaneurysms with and without annotation in a patient with diabetic retinopathy. C,D) Late ultra-widefield FA shows leakage with and without annotations in a DR patient.**

zone integrity, subretinal hyperreflective material, and subretinal pigment epithelium disease in neovascular age-related macular degeneration. *Ophthalmol Retina*. 2021;5:1204-1213.

14. Ehlers JP, Clark J, Uchida A, et al. Longitudinal higher-order OCT assessment of quantitative fluid dynamics and the total retinal fluid index in neovascular AMD. *Transl Vis Sci Technol*. 2021;10:29.
15. Shaw JE, Sicree RA, Zimmet PZ. Global estimates of the prevalence of diabetes for 2010 and 2030. *Diabetes Res Clin Pract*. 2010;87:4-14.
16. Yau JW, Rogers SL, Kawasaki R, et al. Global prevalence and major risk factors of diabetic retinopathy. *Diabetes Care*. 2012;35:556-564.
17. Williams R, Karuranga S, Malanda B, et al. Global and regional estimates and projections of diabetes-related health expenditure: Results from the International Diabetes Federation Diabetes Atlas, 9th edition. *Diabetes Res Clin Pract*. 2020;162:108072.
18. Abrámoff MD, Lavin PT, Birch M, Shah N, Folk JC. Pivotal trial of an autonomous AI-based diagnostic system for detection of diabetic retinopathy in primary care offices. *NPJ Digit Med*. 2018;1:39.
19. Jiang AC, Srivastava SK, Hu M, et al. Quantitative ultra-widefield angiographic features and associations with diabetic macular edema. *Ophthalmol Retina*. 2020;4:49-56.
20. Ehlers JP, Jiang AC, Boss JD, et al. Quantitative ultra-widefield angiography and diabetic retinopathy severity: An assessment of panretinal leakage index, ischemic index and microaneurysm count. *Ophthalmology*. 2019;126:1527-1532.
21. Ehlers JP, Uchida A, Hu M, et al. Higher-order assessment of OCT in diabetic macular edema from the VISTA Study: Ellipsoid zone dynamics and the Retinal Fluid Index. *Ophthalmol Retina*. 2019;3:1056-1066.
22. Ehlers JP, Uchida A, Sevgi DD, et al. Retinal fluid volatility associated with interval tolerance and visual outcomes in diabetic macular edema in the VISTA Phase III trial. *Am J Ophthalmol*. 2021;224:217-227.
23. Vujosevic S, Midena E. Retinal layers changes in human preclinical and early clinical diabetic retinopathy support early retinal neuronal and Müller cells alterations. *J Diabetes Res*. 2013;2013:905058.
24. Shi R, Guo Z, Wang F, Li R, Zhao L, Lin R. Alterations in retinal nerve fiber layer thickness in early stages of diabetic retinopathy and potential risk factors. *Curr Eye Res*. 2018;43:244-253.
25. Deák GG, Schmidt-Erfurth UM, Jampol LM. Correlation of central retinal thickness and visual acuity in diabetic macular edema. *JAMA Ophthalmol*. 2018;136:1215-1216.
26. Joltikov KA, Sesi CA, de Castro VM, et al. Disorganization of retinal inner layers (DRIL) and neuroretinal dysfunction in early diabetic retinopathy. *Invest Ophthalmol Vis Sci*. 2018;59:5481-5486.

# Climate change and social media

*Exploring the axis of access: Pollution, health outcomes and your social media account.*

**By David R. P. Almeida,  
MD, PhD, MBA**



**T**he scientific consensus on the anthropogenic cause of climate change is overwhelming and undeniable. However, climate change perceptions interact with how climate change is portrayed in the news, which is now increasingly accessed via social media platforms.<sup>1</sup>

As we have assayed here in “Social Media Specialist” previously, social media has the potential to be a significant means of effective knowledge translation. But, at they’re worst, social media platforms turn into ideological echo chambers where falsehoods can’t be set straight.

The confluence of cognitive biases (systematic errors in thinking that stem from the propensity of mental shortcuts), social bias (tendency to trust information that comes from those with whom you identify over information from other sources) and algorithmic bias (inherent in social media platforms) can distort accurate information into incomprehensible opinion.

## Pollution and health outcomes

The World Health Organization estimates that roughly 7 million people die yearly from “exposure to fine particles in polluted air.”<sup>2</sup> That’s double the number of people who died globally from COVID-19 in 2020.




## Quotable

**Social media is an arena where we can advocate for climate change protections as an access point in limiting the negative effects of pollution on our patients’ health.**

The proximate health consequences of pollution—pneumonia, stroke and heart disease—are responsible for massive economic costs of nearly \$3 trillion annually.<sup>1</sup> When the best evidence declares “no safe level of air pollution,” interventions to improve health outcomes necessitate plans to mitigate the polluting effects of climate change.<sup>3</sup>

## Accessing health outcomes

There’s no doubt that climate change, pollution, medicine, ophthalmology and social media are disparate subjects. Still, they’re sympatico regarding accessing the best possible health outcomes for individuals and communities.

Social media is an arena where we can advocate for climate change protections as an indirect access point in limiting the negative effects of pollution on the health of our patients. 

## REFERENCES

1. Tuitjer J, Dirksmeier P. Social media and perceived climate change efficacy: A European comparison. *Digital Geography and Society*. 2021;2:100018.
2. Osseiran N, Lindmeier C. World Health Organization releases new global air pollution data. Updated May 2, 2018. Available at: <https://tiny.one/2p8dpaz7>. Accessed November 7, 2022.
3. Zhao B, Johnston FH, Salimi F, Kurabayashi M, Negishi K. Short-term exposure to ambient fine particulate matter and out-of-hospital cardiac arrest: A nationwide case-crossover study in Japan. *Lancet Planet Health*. 2020;4:e15-e23.

## Bio

**Dr. Almeida** is in private practice at Erie Retinal Surgery in Erie, Pennsylvania.

**Twitter:** @davidalmeidamd

**Email:** drpa@pm.me

**DISCLOSURES:** Dr. Almeida reports financial relationships with Acylerin, Alcon, Alimera Sciences, Allergan/AbbVie, Bausch + Lomb, Bayer, Boehringer Ingelheim, Citrus Therapeutics, Clinical Trials Network, EyePoint Pharmaceuticals, Genentech/Roche, Gyroscope Therapeutics, Novartis, Opthea, Regeneron Pharmaceuticals, RegenxBio, Samsara Vision and Spherix Consulting Group.



# AAO highlights: ILM peel in DR and more

*Standout Retina Subspecialty Day 2022 talks include real-world faricimab and high-dose aflibercept results, and Protocol T outcomes.*

## Take-home points

- » The long-term effects of internal limiting membrane peeling on young patients with diabetic retinopathy are unknown. ILM peeling isn't advisable in all cases of diabetic macular edema or tractional retinal detachment.
- » Faricimab real-world results reveal stable to improved visual acuity in both previously treated and treatment-naïve patients with neovascular age-related macular degeneration and the drug appears to be safe and well-tolerated.
- » A large majority of patients receiving high-dose aflibercept for neovascular age-related macular degeneration achieved dosing at 12-week or greater intervals.
- » At two years, no statistically significant difference in visual acuity was found between patients receiving aflibercept monotherapy or bevacizumab first for diabetic macular edema.

**T**he Retina Subspecialty Day sessions at the annual American Academy of Ophthalmology meeting are packed with important trial readouts and a host of presentations on new medical management and surgical techniques. This year's meeting in Chicago lived up to expectations.

Here we present four notable abstracts from the meeting:

- a literature review of outcomes for internal limited membrane peeling in patients with diabetic macular edema;
- an update from the TRUCKEE study of real-world outcomes in patients receiving faricimab for neovascular age-related macular degeneration;
- 48-month results from the PULSAR study of high-dose aflibercept for patients with nAMD; and
- an update from the DRCR Retina Network Protocol AC trial of patients randomized to aflibercept monotherapy or bevacizumab first.



### Is ILM necessary in diabetic vitrectomy?

Internal limiting membrane peeling in diabetic vitrectomy has been proposed for DME, proliferative diabetic

retinopathy and tractional retinal detachment. However, we don't fully understand the long-term effects or even immediate benefits of ILM peeling.

Stanley Chang, MD, of the Edward Harkness Eye Institute at Columbia University Medical Center in New York, described the important role Müller cells play as the primary glial cells of the retina.<sup>1</sup> ILM peeling injures Müller cells and nerve fiber layer axons. Müller cells are important in maintaining retinal function including recycling neurotransmitters, preventing glutamate toxicity, participating in the retinoid cycle, and regulating nutrient supply and blood flow to the retina. Disturbing the Müller cells can affect all the cells in the retina.

In diabetes, hyperglycemia activates Müller cells, increasing cytokine and chemokine release. The retinal thickness is also decreased in patients with severe diabetic eye disease.

Dr. Chang performed a literature review that found no difference in best corrected visual acuity, postoperative central macular thickness or macular thickness reduction in patients undergoing ILM peeling for DME.

ILM peeling in PDR showed slightly more promising results. Patients undergoing ILM peeling for PDR or TRD had better BCVA, needed fewer anti-VEGF

**By Avni P. Finn, MD, MBA**




Avni P. Finn, MD, MBA

## BIO

Dr. Finn is an assistant professor of clinical ophthalmology and visual sciences at the Vanderbilt Eye Institute, Nashville, Tennessee.

**DISCLOSURES:** Dr. Finn disclosed relationships with Allergan/AbbVie, Genentech/Roche and Apellis Pharmaceuticals.



**TRUCKEE showed that patients treated with faricimab have good outcomes with stable VA, reduced mean central subfield thickness and decreased pigment epithelial detachment height.**

injections, and had a lower postoperative rate of DME and epiretinal membrane formation. Dr. Chang noted some important limitations, namely that VA results for patients undergoing subsequent epiretinal membrane peeling weren't available.

Dr. Chang reviewed his own cases, noting that the ILM shouldn't be peeled if it appears normal. No strong clinical evidence exists that peeling ILM in cases of DME leads to better outcomes. He advised peeling ILM in diabetic eyes with macular traction if striae are present and underscored that we don't know the long-term effects of ILM peeling on DR, especially in younger patients.

*Dr. Chang disclosed relationships with Alcon Laboratories and Genentech.*



**Update from TRUCKEE study of faricimab**

**T**RUCKEE is an ongoing collaborative clinician-run trial across the United States looking at real-world outcomes in patients receiving faricimab (Vabysmo, Genentech/Roche).<sup>2</sup> So far, 491 patients with nAMD have been enrolled, receiving a total of 1,231 injections; follow-up data are available on 335 patients. The majority were high-need patients and most were switched from aflibercept (Eylea, Regeneron Pharmaceuticals) to faricimab.

Overall, TRUCKEE showed that patients treated with faricimab have good outcomes with stable to improved VA, reduced mean central subfield thickness and decreased pigment epithelial detachment height.

Treatment-naïve patients gained on average 4.9 letters, had an 84.5- $\mu$ m reduction in mean CST and 93- $\mu$ m reduction in PED height. After one faricimab injection, 40 percent of patients had resolution of intraretinal fluid, 25 percent had total resolution of subretinal fluid and 41.7 percent had total resolution of PEDs.

For all patients switched from any anti-VEGF medication to faricimab, IRF

resolution occurred in 17.8 percent of eyes, SRF resolution in 36.6 percent and PED resolved in 11.1 percent. For those eyes switched from aflibercept, 12.3 percent had complete IRF resolution, 37.2 percent complete SRF resolution and 3.2 percent complete PED resolution. All switched patients maintained or extended their prior-treatment interval.

Faricimab was well-tolerated with one case of infectious endophthalmitis and one case of intraocular inflammation in the study. Ramanath Bhandari, MD, of Spring Clinic Eye Institute in Springfield, Illinois, was asked about the need for repeating loading doses when switching a patient to faricimab and advised that a loading dose is beneficial for patients that are amenable when switching therapies.

*Dr. Bhandari disclosed relationships with Apellis Pharmaceuticals, Novartis, Regeneron Pharmaceuticals, RevOpsis and Vial.*



**High-dose aflibercept extends intervals**

**P**ULSAR was a multicenter, randomized, double masked study of 1,011 patients with treatment-naïve nAMD.<sup>3</sup> Patients were randomized 1:1:1 to aflibercept 2 mg q8 weeks, aflibercept 8 mg q12 weeks or aflibercept 8 mg q16 weeks, all after three monthly injections. Baseline patient characteristics were similar across all groups and the study met its primary endpoint at week 48.

At 48 weeks, the standard dosing group gained 6.2 letters, the 8-mg/q12-weeks group gained 6.7 letters and the 8-mg/q16-weeks group gained 7.6 letters, Paolo Lanzetta, MD, of the University of Udine and the European Institute of Ocular Microsurgery in Milan, reported.

At week 16, 63 percent of patients on 8-mg treatment didn't have any retinal fluid compared to 52 percent in the 2-mg group. Overall, 83 percent of patients receiving the 8-mg dose maintained a greater-than-q12-weeks dosing. Seventy-nine percent of

patients maintained a q12-week regimen and 77 percent a q16-week dosing.

All three groups had a similar CRT, and no group saw a significant see-sawing effect over the 48 weeks. The higher dose was well tolerated and no significant safety signals were reported during the study.

Importantly, intraocular pressure increase was similar across all groups, with a 2.1 percent rise in the 2-mg group and a 3 percent increase in the 8-mg groups. PULSAR shows some encouraging results for increasing duration with high dose aflibercept.

*Dr. Lanzetta disclosed relationships with AbbVie, Aerie Pharmaceuticals, Apellis Pharmaceuticals, Bausch + Lomb, Bayer Healthcare Pharmaceuticals, Biogen, Boehringer Ingelheim, Centervue, Genentech, Novartis, Outlook Therapeutics and Roche.*



### Aflibercept vs. bevacizumab for DME

The Protocol AC study of the DRCR Retina Network evaluated aflibercept monotherapy or bevacizumab (Avastin, Roche/Genentech) first for diabetic macular edema.<sup>4,5</sup>

We know from Protocol T that patients with 20/50 or worse vision who were started on aflibercept did better at one and two years.<sup>6</sup> Insurers are increasingly demanding that we employ “step therapy” to reduce costs, but we don’t know if this treatment strategy compromises visual outcomes for patients.

In Protocol AC, patients with 20/50 or worse vision were randomized to aflibercept monotherapy or bevacizumab first. At 12 weeks, patients receiving bevacizumab first could be switched to aflibercept based on the following criteria: persistent DME; injection with bevacizumab at the last two visits; no recent improvement; and continued suboptimal vision (20/50 or worse before 24 weeks and 20/32 or worse after 24 weeks). Once patients were switched, they were treated with aflibercept for two

monthly visits then retreated according to preset criteria.

The bevacizumab-first patients averaged 1.5 more injections over two years. Over two years, 70 percent of patients switched from bevacizumab first to aflibercept. No overall difference in mean vision or retinal thickness was found between the two groups. The number of patients with two- and three-line improvement were similar in both groups. CST wasn’t statistically significantly different between the two groups, although the results slightly favored aflibercept.

At two years, 62 percent of aflibercept eyes and 55 percent of bevacizumab eyes had complete DME resolution. Adverse events were similar across both groups.

Chirag Jhaveri, MD, of the Retina Consultants of Austin and the Austin Research Center for Retina in Texas, concluded that rescue treatment with aflibercept mitigated the average visual and anatomic difference that arose from initiating therapy with bevacizumab versus aflibercept. Initiating treatment with bevacizumab may result in cost reductions for the health-care system without significant difference in visual outcomes over two years.

*Dr. Jhaveri disclosed relationships with Boehringer Ingelheim, Genentech/Roche, Gyroscope Therapeutics, Kodiak Sciences, Novartis, Opthea, Oxurion and RegenxBio.* <sup>CS</sup>

### REFERENCES

1. Chang S. Is it necessary to peel internal limiting membrane in diabetic vitrectomy? Paper presented at American Academy of Ophthalmology Retina Subspecialty Day, Session RET02; Chicago, IL; September 30, 2022.
2. Bhandari R. Real world efficacy, durability and safety of faricimab in neovascular age-related macular degeneration: TRUCKEE study. Paper presented at AAO Retina Subspecialty Day, Session RET09; Chicago, IL; September 30, 2022.
3. Lanzetta P. Intravitreal aflibercept injection 8 mg for neovascular age-related macular degeneration: 48-week results from the Phase 3 PULSAR trial. Paper presented at AAO Retina Subspecialty Day, Session RET09; Chicago, IL; September 30, 2022.
4. Jhaveri CD. DRCR Retina Network: Protocol AC results. Paper presented at AAO Retina Subspecialty Day, Session RET10; Chicago, IL; October 1, 2022.
5. Jhaveri CD, Glassman AR, Ferris FL 3rd, et al; DRCR Retina Network. Aflibercept monotherapy or bevacizumab first for diabetic macular edema. *N Engl J Med.* 2022;387:692-703.
6. Bressler NM, Beaulieu WT, Maguire MG, et al; Diabetic Retinopathy Clinical Research Network. Early response to anti-vascular endothelial growth factor and two-year outcomes among eyes with diabetic macular edema in Protocol T. *Am J Ophthalmol.* 2018;195:93-100.

**At two years, 62 percent of aflibercept eyes and 55 percent of bevacizumab eyes had complete resolution of DME. Adverse events were similar across both groups.**



# Axitinib implant shows early potential

*Interim results from Phase I trial of OTX-TKI, a bioresorbable hydrogel platform using a tyrosine kinase inhibitor.*

With **Arshad Khanani, MD**



Arshad Khanani, MD

**What makes tyrosine kinase inhibitors novel in the treatment of exudative retinal disease is their pan-vascular endothelial growth factor inhibition.**

**T**yrosine kinase inhibitors are drawing heightened interest as a novel treatment for exudative retinal disease. They include vorolanib (EYP-1901, EyePoint Pharmaceuticals), sunitinib (GB-102, Graybug Vision) and axitinib.

The latter is the subject of two investigative programs in neovascular age-related macular degeneration: OTX-TKI (Ocular Therapeutix), an intravitreal, bioresorbable hydrogel implant; and CLS-AX (Clearside Biomedical), a suprachoroidal microinjector platform.

Seven-month interim results of the U.S.-based Phase I trial of OTX-TKI 600 µg, reported in October at the American Academy of Ophthalmology meeting,<sup>1</sup> showed that the implant was well-tolerated in the patients who received it. All trial subjects had been previously treated for their nAMD.

## Novelty of TKIs

What makes TKIs novel in the treatment of exudative retinal disease is their pan-vascular endothelial growth factor inhibition. Existing treatments target one or two factors (faricimab [Vabysmo, Genentech/Roche] targets VEGF-A and angiopoietin-2). Whether this translates into longer treatment intervals is something the various clinical trials of TKIs in retinal disease, including the Phase I OTX-TKI trial, aim to sort out.

Here, Arshad Khanani, MD, who presented the interim results at the AAO meeting, answers questions about the Phase I trial of OTX-TKI in wet AMD. Dr. Khanani is managing partner and director of clinical research at Sierra Eye Associates in Reno, Nevada, and clinical associate professor at the University of Nevada, Reno School of Medicine. He is a consultant to trial sponsor Ocular Therapeutix, as well as EyePoint Pharmaceuticals, Genentech/Roche, Graybug Vision, Novartis and Regeneron Pharmaceuticals.

**Q What makes TKIs unique for treatment of exudative retinal disease?**

**A** TKIs are designed for pan-VEGF inhibition. They work on the intracellular receptors. Current anti-VEGF treatments target extracellular VEGF with antibodies or trap, but TKIs bind to all VEGF receptors and block them from inside the cell.

**Q How does axitinib differ from the other TKIs in the pipeline?**

**A** The benefit of axitinib is that it seems to have the highest affinity for VEGF-2 compared to the other TKIs. The hope is that with that high affinity and the sustained dosing through the bioresorbable implant, we'll be able to control nAMD for six months or more in most of these patients.

**Q Can you describe the design of the Phase I U.S. trial?**

**A** This trial followed a study in Australia that detected a signal for efficacy. That trial included both previously treated and treatment-naive patients. With the U.S. study, the goal was to evaluate safety, durability and tolerability of OTX-TKI in previously treated patients with nAMD. Eligibility criteria included having controlled retinal fluid and a response to anti-VEGF previously.

Patients were randomized 3:1 to either OTX-TKI or aflibercept (Eylea, Regeneron Pharmaceuticals; n=15 and 5), with the aflibercept arm getting a sham injection at baseline. At four weeks, all patients received an aflibercept injection, with the aflibercept arm getting injections every eight weeks.

**Q What were the criteria for rescue therapy?**

**A** Rescue criteria were a ≥10-letter loss from the previous best-corrected visual acuity or ≥75 µm change in central subfield thickness and a ≥5-letter loss and new macu-

lar hemorrhage. However, if the investigator felt the patient needed treatment, they could exercise their own discretion.

**Q What's the take-home from the seven-month trial results?**

**A** The majority of patients on OTX-TKI maintained BCVA and CSFT through seven months. The mean change in BCVA was -1.2 (5.2) letters and -1 (5.3) letters in the OTX-TKI and aflibercept arms, respectively. The mean change in CSFT was +9.2 (38.6)  $\mu\text{m}$  and +0.4 (9.1)  $\mu\text{m}$ .

**Q How many OTX-TKI patients needed rescue?**

**A** Eighty percent were rescue-free through six months and 73 percent through seven months. Four patients received five rescue injections, all based on the investigator's discretion. One OTX-TKI patient received rescue aflibercept at three and five months, two received rescue at five months, and one received rescue at six months.


**Q What were the findings with regard to safety?**

**A** There were no drug-related ocular serious adverse events. One patient in the OTX-TKI arm had endophthalmitis after receiving an aflibercept rescue injection. It resolved after an intravitreal antibiotic injection and the patient's vision returned to baseline. There were no reports of intraocular inflammation in the OTX-TKI arm.

**Q What are the next steps in the development of OTX-TKI?**

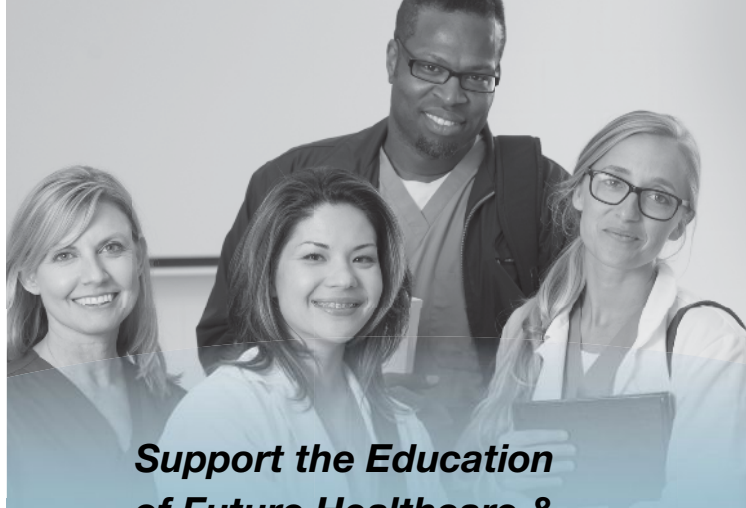
**A** First, the 12-month results from the Phase I U.S. trial must be collected and analyzed. In my opinion, the next trial should look at previously treated patients and have the primary endpoint of noninferiority to aflibercept. The Phase II trial in wet AMD is expected to start later next year. Ocular Therapeutix also plans to start a U.S.-based Phase I trial in diabetic retinopathy next year.

**Q Any parting thoughts?**

**A** The bar is high whenever you have a new mechanism of action and early stage data, so we're going to learn together in terms of long-term efficacy, long-term safety and durability of OTX-TKI as we go into larger trials to make sure what we're seeing is real as well as if the safety continues to look good. 

## REFERENCE

1. Khanani AM, Couvillion S, Eichenbaum D, Steinle N, Wykoff CK, Xavier S. Interim 7-month data from a Phase I US study of sustained-release axitinib hydrogel implant (OTX-TKI) in previously treated wet age-related macular degeneration subjects. Poster 359 presented at the American Academy of Ophthalmology, Retina Subspecialty Day; Chicago, IL; September 30-October 3, 2022.



**Support the Education  
of Future Healthcare &  
Eyecare Professionals**

# THE RICK BAY FOUNDATION

*for Excellence in Eyecare Education*

Scholarships are awarded to advance the education of students in both **Optometry** and **Ophthalmology**, and are chosen by their school based on qualities that embody Rick's commitment to the profession, including integrity, compassion, partnership and dedication to the greater good.

**INTERESTED IN BEING  
A PARTNER WITH US?**

[www.rickbayfoundation.org](http://www.rickbayfoundation.org)

*(Contributions are tax-deductible in accordance with section 170 of the Internal Revenue Code.)*

### ABOUT RICK

Rick Bay served as the publisher of *The Review Group* for more than 20 years.

To those who worked for him, he was a leader whose essence was based in a fierce and boundless loyalty.

To those in the industry and the professions he served, he will be remembered for his unique array of skills and for his dedication to exceeding the expectations of his customers, making many of them fast friends.



**THE RICK BAY FOUNDATION**  
*for Excellence in Eyecare Education*

*(The Rick Bay Foundation for Excellence in Eyecare Education is a nonprofit, tax-exempt organization under section 501(c)(3) of the Internal Revenue Code.)*

## Anti-VEGF for RVO

(Continued from page 27)

macular edema and neovascular age-related macular degeneration, and tarcocimab. <sup>CS</sup>

## REFERENCES

- Ip M, Hendrick A. Retinal vein occlusion review. *Asia Pac J Ophthalmol (Phila)*. 2018;7:40-45.
- Hayreh SS, Zimmerman MB. Branch retinal vein occlusion: natural history of visual outcome. *JAMA Ophthalmol*. 2014;132:13-22.
- Scott IU, Campochiaro PA, Newman NJ, Biousse V. Retinal vascular occlusions. *Lancet*. 2020;396:1927-1940.
- Rosenfeld PJ, Fung AE, Puliafito CA. Optical coherence tomography findings after an intravitreal injection of bevacizumab (Avastin) for macular edema from central retinal vein occlusion. *Ophthalmic Surg Lasers Imaging*. 2005;36:336-339.
- Campochiaro PA, Heier JS, Feiner L, et al. Ranibizumab for macular edema following branch retinal vein occlusion: Six-month primary end point results of a Phase III study. *Ophthalmology*. 2010;117:1102-1112.
- Brown DM, Campochiaro PA, Singh RP, et al. Ranibizumab for macular edema following central retinal vein occlusion: Six-month primary end point results of a phase III study. *Ophthalmology*. 2010;117:1124-1133.
- Campochiaro PA, Clark WL, Boyer DS, et al. Intravitreal aflibercept for macular edema following branch retinal vein occlusion: The 24-week results of the VIBRANT study. *Ophthalmology*. 2015;122:538-544.
- Heier JS, Clark WL, Boyer DS, et al. Intravitreal aflibercept injection for macular edema due to central retinal vein occlusion: Two-year results from the COPERNICUS Study. *Ophthalmology*. 2014;121:1414-1420.
- Clark WL, Boyer DS, Heier JS, et al. Intravitreal aflibercept for macular edema following branch retinal vein occlusion: 52-week results of the VIBRANT Study. *Ophthalmology*. 2016;123:330-336.
- Korobelnik JF, Holz FG, Roeder J, et al. Intravitreal aflibercept injection for macular edema resulting from central retinal vein occlusion: One-year results of the Phase 3 GALILEO Study. *Ophthalmology*. 2014;121:202-208.
- Thach AB, Yau L, Hoang C, Tuomi L. Time to clinically significant visual acuity gains after ranibizumab treatment for retinal vein occlusion: BRAVO and CRUISE trials. *Ophthalmology*. 2014;121:1059-1066.
- Danzig CJ, Blotner S, Steffen V, Haskova Z. Clinical trial versus real-world outcomes with anti-VEGF therapy for branch and central retinal vein occlusion. *Invest Ophthalmol Vis Sci*. 2021;62:3174.
- Callizo J, Ziemssen F, Bertelmann T, et al. Real-world data: ranibizumab treatment for retinal vein occlusion in the OCEAN Study. *Clin Ophthalmol*. 2019;13:2167-2179.
- Pearce IA, Gupta AD, Lacey S, LUMINOUS. One-year outcomes of ranibizumab treatment in a cohort of patients with retinal vein occlusion: an interim analysis from the real-world LUMINOUS study. *Invest Ophthalmol Vis Sci*. 2015;56:3743-3743.
- Heier JS, Campochiaro PA, Yau L, et al. Ranibizumab for macular edema due to retinal vein occlusions: long-term follow-up in the HORIZON trial. *Ophthalmology*. 2012;119:802-809.
- Brown DM, Campochiaro PA, Bhisitkul RB, et al. Sustained benefits from ranibizumab for macular edema following branch retinal vein occlusion: 12-month outcomes of a Phase III study. *Ophthalmology*. 2011;118:1594-1602.
- Ho AC, Gray S, Rundle A, et al. Ranibizumab in patients with macular edema following retinal vein occlusion: 12-month outcomes of BRAVO and CRUISE. *Invest Ophthalmol Vis Sci*. 2010;51:6452.
- Scott IU, Oden NL, VanVeldhuisen PC, Ip MS, Blodi BA, Chan CK. Month 24 outcomes after treatment initiation with anti-vascular endothelial growth factor therapy for macular edema due to central retinal or hemiretinal vein occlusion: SCORE2 Report 10: A secondary analysis of the SCORE2 randomized clinical trial. *JAMA Ophthalmol*. 2019;137:1389-1398.
- Ip MS, Oden NL, Scott IU, et al. Month 12 outcomes after treatment change at month 6 among poor responders to aflibercept or bevacizumab in eyes with macular edema secondary to central or hemiretinal vein occlusion: A secondary analysis of the SCORE2 Study. *JAMA Ophthalmol*. 2019;137:281-287.
- Larsen M, Waldstein SM, Boscia F, et al. Individualized ranibizumab regimen driven by stabilization criteria for central retinal vein occlusion: Twelve-month results of the CRYSTAL Study. *Ophthalmology*. 2016;123:1101-1011.
- A study to evaluate the efficacy and safety of faricimab in participants with macular edema secondary to branch retinal vein occlusion (BALATON). [ClinicalTrials.gov identifier NCT04740905](https://clinicaltrials.gov/ct2/show/NCT04740905). Updated September 6, 2022. <https://clinicaltrials.gov/ct2/show/NCT04740905>
- A study to evaluate the efficacy and safety of faricimab in participants with macular edema secondary to central retinal or hemiretinal vein occlusion. [ClinicalTrials.gov identifier NCT04740931](https://clinicaltrials.gov/ct2/show/NCT04740931?term=faricimab&draw=2&rank=5). Updated August 31, 2022. <https://clinicaltrials.gov/ct2/show/NCT04740931?term=faricimab&draw=2&rank=5>
- A Study to Evaluate the Efficacy, Durability, and Safety of KSI-301 Compared to Aflibercept in Patients With Macular Edema Due to Retinal Vein Occlusion (RVO). [ClinicalTrials.gov identifier NCT04592419](https://clinicaltrials.gov/ct2/show/NCT04592419). Updated July 22, 2022. <https://clinicaltrials.gov/ct2/show/NCT04592419>
- Singer M. KSI-301 anti-VEGF antibody biopolymer conjugate for retinal vein occlusion: primary 24-week efficacy and safety outcomes of the BEACON Phase 3 Pivotal Study. Abstract presented at the American Academy of Ophthalmology 2022 Meeting, Retina Subspecialty Day, September 30, 2022; Chicago, IL.

## Sickle cell retinopathy: Update on management

(Continued from page 31)

come a useful adjunct. Systemic therapies for SCD have shown some clinical signals to improve SCR, but they also bring limitations, as do BMT and gene therapy. The impact that newer therapies have on SCR has yet to be elucidated. <sup>CS</sup>

## REFERENCES

- Wastnedge E, Waters D, Patel S, et al. The global burden of sickle cell disease in children under five years of age: A systematic review and meta-analysis. *J Glob Health*. 2018;8:021103. doi:10.7189/jogh.08.021103
- Dell'Arti L, Barteselli G, Riva L, et al. Sickle cell maculopathy: Identification of systemic risk factors, and microstructural analysis of individual retinal layers of the macula. *PLoS One*. 2018;13:e0193582.
- Duan XJ, Lanzkron S, Linz MO, Ewing C, Wang J, Scott AW. Clinical and ophthalmic factors associated with the severity of sickle cell retinopathy. *Am J Ophthalmol*. 2019;197:105-113.
- Rodrigues M, Kashiwabuchi F, Deshpande M, et al. Expression pattern of HIF-1 and VEGF supports circumferential application of scatter laser for proliferative sickle retinopathy. *Invest Ophthalmol Vis Sci*. 2016;57:6739-6746.
- Cai CX, Linz MO, Scott AW. Intravitreal bevacizumab for proliferative sickle retinopathy: a case series. *J VitreoRetinal Dis*. 2018;2:32-38.
- Moshiri A, Ha NK, Ko FS, Scott AW. Bevacizumab presurgical treatment for proliferative sickle-cell retinopathy-related retinal detachment. *Retin Cases Brief Rep*. 2013;7:204-205.
- Chen RW, Flynn HW, Jr., Lee WH, et al. Vitreoretinal management and surgical outcomes in proliferative sickle retinopathy: a case series. *Am J Ophthalmol*. 2014;157:870-875.
- Wang WC, Ware RE, Miller ST, et al. Hydroxycarbamide in very young children with sickle-cell anaemia: A multicentre, randomised, controlled trial (BABY HUG). *Lancet*. 2011;377:1663-1672.
- Mian UK, Tang J, Allende APM, et al. Elevated fetal haemoglobin levels are associated with decreased incidence of retinopathy in adults with sickle cell disease. *Br J Haematol*. 2018;183:807-811.
- Agrawal RK, Patel RK, Shah V, Nainiwal L, Trivedi B. Hydroxyurea in sickle cell disease: drug review. *Indian J Hematol Blood Transfus*. 2014;30:91-96.
- Lim JJ, Niec M, Sun J, Cao D. Longitudinal assessment of retinal thinning in adults with and without sickle cell retinopathy using spectral-domain optical coherence tomography. *JAMA Ophthalmol*. 2021;139:330-337.
- Zhou DB, Castanos MV, Pinhas A, et al. Quantification of intermittent retinal capillary perfusion in sickle cell disease. *Biomed Opt Express*. 2021;12:2825-2840.
- Howard J. Sickle cell disease: when and how to transfuse. *Hematol Am Soc Hematol Educ Program*. 2016;2016:625-631.
- McKinney CM, Siringo F, Olson JL, Capocelli KE, Ambruso DR, Nuss R. Red cell exchange transfusion halts progressive proliferative sickle cell retinopathy in a teenaged patient with hemoglobin SC disease. *Pediatr Blood Cancer*. 2015;62:721-723.
- Schlusser AE, Hales BF. Deprenyl enhances the teratogenicity of hydroxyurea in organogenesis stage mouse embryos. *Toxicol Sci*. 2013;134:391-399.
- Weber GF. DNA Damaging Drugs. In: Weber GF, ed. *Molecular Therapies of Cancer*. Springer International Publishing; 2015:9-112.
- Hodges JR, Phillips SM, Norell S, et al. Intentional and unintentional nonadherence to hydroxyurea among people with sickle cell disease: a qualitative study. *Blood Advances*. 2020;4:4463-4473.
- Steinberg MH, Barton F, Castro O, et al. Effect of hydroxyurea on mortality and morbidity in adult sickle cell anemia: risks and benefits up to 9 years of treatment. *JAMA*. 2003;289:1645-1651.
- Ashorobi D, Bhatt R. Bone Marrow Transplantation In Sickle Cell Disease. *StatPearls*. StatPearls Publishing LLC.; 2022.
- Kanter J, Falcon C. Gene therapy for sickle cell disease: Where are we now? *Hematology*. 2021;2021:174-180.
- Fox PD, Dunn DT, Morris JS, Serjeant GR. Risk factors for proliferative sickle retinopathy. *Br J Ophthalmol*. 1990;74:172-176. doi:10.1136/bjo.74.3.172
- Ballas SK, Lewis CN, Noone AM, Krasnow SH, Kamarulzaman E, Burka ER. Clinical, hematological, and biochemical features of Hb SC disease. *Am J Hematol*. 1982;13:37-51.
- Hingorani M, Bentley CR, Jackson H, et al. Retinopathy in haemoglobin C trait. *Eye (Lond)*. 1996;10:338-342.
- Summavarell CCG, Sheehan VA. Original Research: Use of hydroxyurea and phlebotomy in pediatric patients with hemoglobin SC disease. *Exp Biol Med (Maywood)*. 2016;241:737-744.
- Ataga KI, Kutlar A, Kanter J, et al. Crizanlizumab for the prevention of pain crises in sickle cell disease. *N Engl J Med*. 2017;376:429-439.
- Vichinsky E, Hoppe CC, Ataga KI, et al. A Phase 3 randomized trial of voxelotor in sickle cell disease. *N Engl J Med*. 2019;381:509-519.
- Niihara Y, Miller ST, Kanter J, et al. A Phase 3 trial of L-glutamine in sickle cell disease. *N Engl J Med*. 2018;379:226-235.
- Wu Y, Zeng J, Roscoe BP, et al. Highly efficient therapeutic gene editing of human hematopoietic stem cells. *Nat Med*. 2019;25:776-783.

**VABYSMO<sup>™</sup> (faricimab-svoa) injection, for intravitreal use**

This is a brief summary. Before prescribing, please refer to the full Prescribing Information

**1 INDICATIONS AND USAGE**

VABYSMO is a vascular endothelial growth factor (VEGF) and angiopoietin 2 (Ang-2) inhibitor indicated for the treatment of patients with:

**1.1 Neovascular (wet) Age-Related Macular Degeneration (nAMD)**
**1.2 Diabetic Macular Edema (DME)**
**4 CONTRAINDICATIONS**
**4.1 Ocular or Periocular Infections**

VABYSMO is contraindicated in patients with ocular or periocular infections.

**4.2 Active Intraocular Inflammation**

VABYSMO is contraindicated in patients with active intraocular inflammation.

**4.3 Hypersensitivity**

VABYSMO is contraindicated in patients with known hypersensitivity to faricimab or any of the excipients in VABYSMO. Hypersensitivity reactions may manifest as rash, pruritus, urticaria, erythema, or severe intraocular inflammation.

**5 WARNINGS AND PRECAUTIONS**
**5.1 Endophthalmitis and Retinal Detachments**

Intravitreal injections have been associated with endophthalmitis and retinal detachments [see *Adverse Reactions* (6.1)]. Proper aseptic injection techniques must always be used when administering VABYSMO. Patients should be instructed to report any symptoms suggestive of endophthalmitis or retinal detachment without delay, to permit prompt and appropriate management [see *Dosage and Administration* (2.6) and *Patient Counseling Information* (17)].

**5.2 Increase in Intraocular Pressure**

Transient increases in intraocular pressure (IOP) have been seen within 60 minutes of intravitreal injection, including with VABYSMO [see *Adverse Reactions* (6.1)]. IOP and the perfusion of the optic nerve head should be monitored and managed appropriately [see *Dosage and Administration* (2.6)].

**5.3 Thromboembolic Events**

Although there was a low rate of arterial thromboembolic events (ATEs) observed in the VABYSMO clinical trials, there is a potential risk of ATEs following intravitreal use of VEGF inhibitors. ATEs are defined as nonfatal stroke, nonfatal myocardial infarction, or vascular death (including deaths of unknown cause).

The incidence of reported ATEs in the nAMD studies during the first year was 1% (7 out of 664) in patients treated with VABYSMO compared with 1% (6 out of 662) in patients treated with aflibercept [see *Clinical Studies* (14.1)].

The incidence of reported ATEs in the DME studies during the first year was 2% (25 out of 1,262) in patients treated with VABYSMO compared with 2% (14 out of 625) in patients treated with aflibercept [see *Clinical Studies* (14.2)].

**6 ADVERSE REACTIONS**

The following potentially serious adverse reactions are described elsewhere in the labeling:

- Hypersensitivity [see *Contraindications* (4)]
- Endophthalmitis and retinal detachments [see *Warnings and Precautions* (5.1)]
- Increase in intraocular pressure [see *Warnings and Precautions* (5.2)]
- Thromboembolic events [see *Warnings and Precautions* (5.3)]

**6.1 Clinical Trial Experience**

Because clinical trials are conducted under widely varying conditions, adverse reaction rates observed in the clinical trials of a drug cannot be directly compared to rates in other clinical trials of the same or another drug and may not reflect the rates observed in practice.

The data described below reflect exposure to VABYSMO in 1,926 patients, which constituted the safety population in four Phase 3 studies [see *Clinical Studies* (14.1, 14.2)].

**Table 1: Common Adverse Reactions (≥ 1%)**

Adverse Reactions	VABYSMO		Active Control (aflibercept)	
	AMD N=664	DME N=1262	AMD N=622	DME N=625
Conjunctival hemorrhage	7%	7%	8%	6%
Vitreous floaters	3%	3%	2%	2%
Retinal pigment epithelial tear <sup>a</sup>	3%		1%	
Intraocular pressure increased	3%	3%	2%	2%
Eye pain	3%	2%	3%	3%
Intraocular inflammation <sup>b</sup>	2%	1%	1%	1%
Eye irritation	1%	1%	< 1%	1%
Ocular discomfort	1%	1%	< 1%	< 1%
Vitreous hemorrhage	< 1%	1%	1%	< 1%
<sup>a</sup> AMD only				
<sup>b</sup> Including iridocyclitis, iritis, uveitis, vitritis				

Less common adverse reactions reported in < 1% of the patients treated with VABYSMO were corneal abrasion, eye pruritus, lacrimation increased, ocular hyperemia, blurred vision, eye irritation, sensation of foreign body, endophthalmitis, visual acuity reduced transiently, retinal tear and rhegmatogenous retinal detachment.

**6.2 Immunogenicity**

The immunogenicity of VABYSMO was evaluated in plasma samples. The immunogenicity data reflect the percentage of patients whose test results were considered positive for antibodies to VABYSMO in immunoassays. The detection of an immune response is highly dependent on the sensitivity and specificity of the assays used, sample handling, timing of sample collection, concomitant medications, and underlying disease. For these reasons, comparison of the incidence of antibodies to VABYSMO with the incidence of antibodies to other products may be misleading.

There is a potential for an immune response in patients treated with VABYSMO. In the nAMD and DME studies, the pre-treatment incidence of anti-faricimab antibodies was approximately 1.8% and 0.8%, respectively. After initiation of dosing, anti-faricimab antibodies were detected in approximately 10.4% and 8.4% of patients with nAMD and DME respectively, treated with VABYSMO across studies and across treatment groups. As with all therapeutic proteins, there is a potential for immunogenicity with VABYSMO.

**8 USE IN SPECIFIC POPULATIONS**
**8.1 Pregnancy**
**Risk Summary**

There are no adequate and well-controlled studies of VABYSMO administration in pregnant women.

Administration of VABYSMO to pregnant monkeys throughout the period of organogenesis resulted in an increased incidence of abortions at intravenous (IV) doses 158 times the human exposure (based on C<sub>max</sub>) of the maximum recommended human dose [see *Animal Data*]. Based on the mechanism of action of VEGF and Ang-2 inhibitors, there is a potential risk to female reproductive capacity, and to embryo-fetal development. VABYSMO should not be used during pregnancy unless the potential benefit to the patient outweighs the potential risk to the fetus.

All pregnancies have a background risk of birth defect, loss, and other adverse outcomes. The background risk of major birth defects and miscarriage for the indicated population is unknown. In the U.S. general population, the estimated background risk of major birth defects is 2%-4% and of miscarriage is 15%-20% of clinically recognized pregnancies.

**Data**
**Animal Data**

An embryo fetal developmental toxicity study was performed on pregnant cynomolgus monkeys. Pregnant animals received 5 weekly IV injections of VABYSMO starting on day 20 of gestation at 1 or 3 mg/kg. A non-dose dependent increase in pregnancy loss (abortions) was observed at both doses evaluated. Serum exposure (C<sub>max</sub>) in pregnant monkeys at the low dose of 1 mg/kg was 158 times the human exposure at the maximum recommended intravitreal dose of 6 mg once every 4 weeks. A no observed adverse effect level (NOAEL) was not identified in this study.

**8.2 Lactation**
**Risk Summary**

There is no information regarding the presence of faricimab in human milk, the effects of the drug on the breastfed infant, or the effects of the drug on milk production. Many drugs are transferred in human milk with the potential for absorption and adverse reactions in the breastfed child.

The developmental and health benefits of breastfeeding should be considered along with the mother's clinical need for VABYSMO and any potential adverse effects on the breastfed child from VABYSMO.

**8.3 Females and Males of Reproductive Potential**
**Contraception**

Females of reproductive potential are advised to use effective contraception prior to the initial dose, during treatment and for at least 3 months following the last dose of VABYSMO.

**Infertility**

No studies on the effects of faricimab on human fertility have been conducted and it is not known whether faricimab can affect reproduction capacity. Based on the mechanism of action, treatment with VABYSMO may pose a risk to reproductive capacity.

**8.4 Pediatric Use**

The safety and efficacy of VABYSMO in pediatric patients have not been established.

**8.5 Geriatric Use**

In the four clinical studies, approximately 60% (1,149/1,929) of patients randomized to treatment with VABYSMO were ≥ 65 years of age. No significant differences in efficacy or safety of faricimab were seen with increasing age in these studies. No dose adjustment is required in patients 65 years and above.

**17 PATIENT COUNSELING INFORMATION**

Advise patients that in the days following VABYSMO administration, patients are at risk of developing endophthalmitis. If the eye becomes red, sensitive to light, painful, or develops a change in vision, advise the patient to seek immediate care from an ophthalmologist [see *Warnings and Precautions* (5)].

Patients may experience temporary visual disturbances after an intravitreal injection with VABYSMO and the associated eye examinations [see *Adverse Reactions* (6)]. Advise patients not to drive or use machinery until visual function has recovered sufficiently.

VABYSMO<sup>™</sup> [faricimab-svoa]

Manufactured by:

**Genentech, Inc.**

A Member of the Roche Group

1 DNA Way

South San Francisco, CA 94080-4990

U.S. License No.: 1048

VABYSMO is a trademark of Genentech, Inc.

©2022 Genentech, Inc.

M-US-00013249(v1.0) 2/22

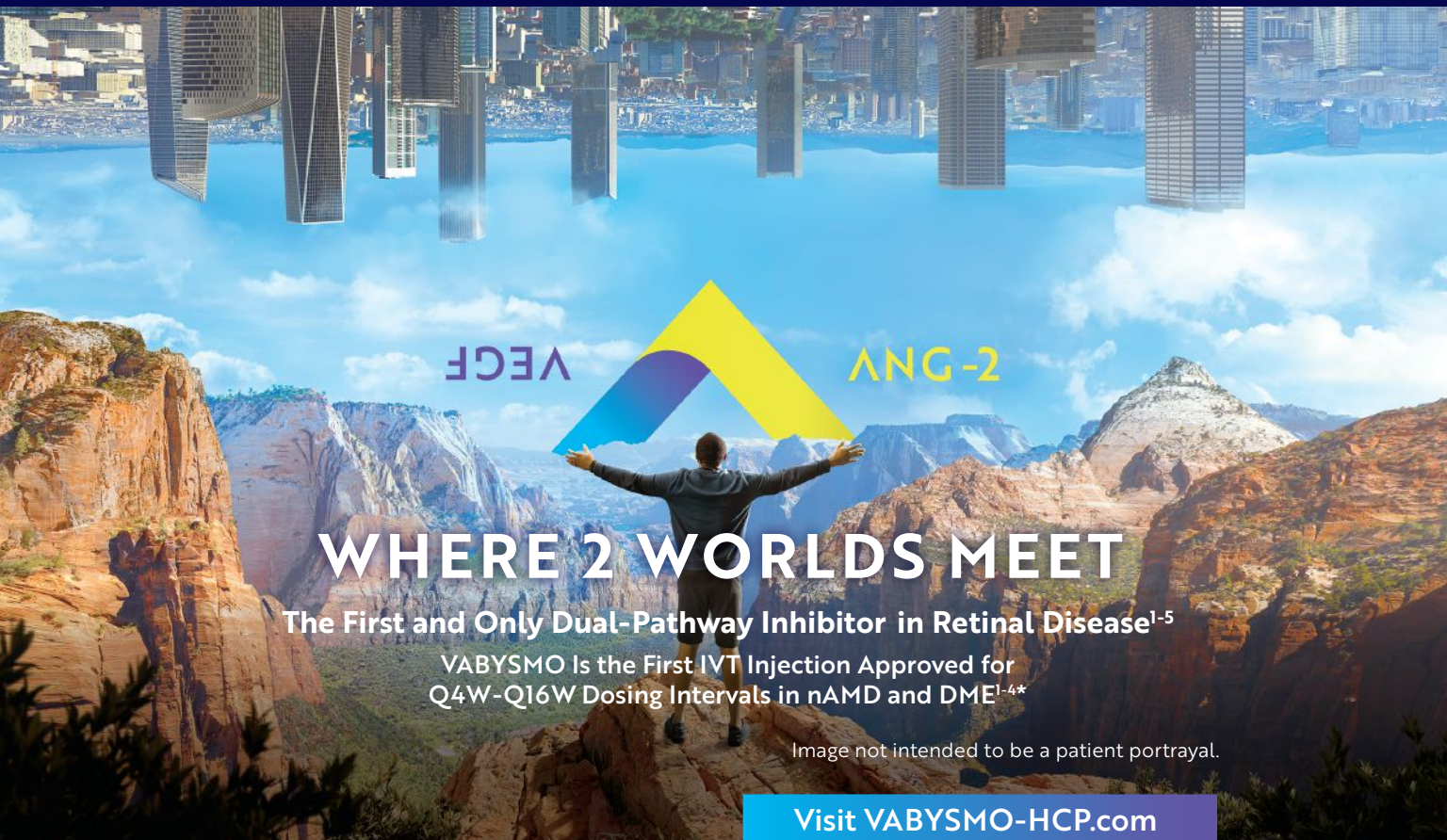

Image not intended to be a patient portrayal.

Visit [VABYSMO-HCP.com](https://www.vabysmo-hcp.com)

## INDICATIONS

VABYSMO (faricimab-svoa) is a vascular endothelial growth factor (VEGF) inhibitor and angiopoietin-2 (Ang-2) inhibitor indicated for the treatment of patients with Neovascular (Wet) Age-Related Macular Degeneration (nAMD) and Diabetic Macular Edema (DME).

## IMPORTANT SAFETY INFORMATION

### Contraindications

VABYSMO is contraindicated in patients with ocular or periocular inflammation, in patients with active intraocular inflammation, and in patients with known hypersensitivity to faricimab or any of the excipients in VABYSMO.

### Warnings and Precautions

- Endophthalmitis and retinal detachments may occur following intravitreal injections. Patients should be instructed to report any symptoms suggestive of endophthalmitis or retinal detachment without delay, to permit prompt and appropriate management.
- Increases in intraocular pressure have been seen within 60 minutes of an intravitreal injection.
- There is a potential risk of arterial thromboembolic events (ATEs) associated with VEGF inhibition.

### Adverse Reactions

The most common adverse reaction (≥5%) reported in patients receiving VABYSMO was conjunctival hemorrhage (7%).

You may report side effects to the FDA at (800) FDA-1088 or [www.fda.gov/medwatch](http://www.fda.gov/medwatch). You may also report side effects to Genentech at (888) 835-2555.

## Please see Brief Summary of VABYSMO full Prescribing Information on the following page.

### \*Dosing Information:

In nAMD, the recommended dose for VABYSMO is 6 mg (0.05 mL of 120 mg/mL solution) IVT Q4W for the first 4 doses, followed by OCT and visual acuity evaluations 8 and 12 weeks later to inform whether to extend to: 1) Q16W (weeks 28 and 44); 2) Q12W (weeks 24, 36, and 48); or 3) Q8W (weeks 20, 28, 36, and 44).

In DME, the recommended dose for VABYSMO is 6 mg (0.05 mL of 120 mg/mL solution) IVT Q4W for ≥4 doses until CST is ≤325 μm (by OCT), followed by treat-and-extend dosing with 4-week interval extensions or 4- to 8-week interval reductions based on CST and visual acuity evaluations through week 52. Alternatively, VABYSMO can be administered IVT Q4W for the first 6 doses, followed by Q8W dosing over the next 28 weeks.

Although VABYSMO may be dosed as frequently as Q4W, additional efficacy was not demonstrated in most patients when VABYSMO was dosed Q4W vs Q8W. Some patients may need Q4W dosing after the first 4 doses. Patients should be assessed regularly and the dosing regimen reevaluated after the first year.

CST=central subfield thickness; IVT=intravitreal; OCT=optical coherence tomography; Q4W=every 4 weeks; Q8W=every 8 weeks; Q12W=every 12 weeks; Q16W=every 16 weeks.

**References:** 1. VABYSMO [package insert]. South San Francisco, CA: Genentech, Inc; 2022. 2. Beovu® (brolucizumab) [package insert]. East Hanover, NJ: Novartis; 2020. 3. Eylea® (afibercept) [package insert]. Tarrytown, NY: Regeneron Pharmaceuticals, Inc; 2021. 4. LUCENTIS® (ranibizumab) [package insert]. South San Francisco, CA: Genentech, Inc; 2018. 5. SUSVIMO™ (ranibizumab injection) [package insert]. South San Francisco, CA: Genentech, Inc; 2022.