

EMJ

Gastroenterology

Review of UEG Week 2022

Editor's Pick

Medullary Carcinoma of the Pancreas: Report of a Rare Pancreatic Malignancy and Review of Literature

Interview

Michael Farthing

Contents

4 Editorial Board

6 Welcome

7 Foreword

8 Congress Review

Review of the United European Gastroenterology (UEG)
Week 2022
8th –11th October 2022

22 Congress Feature

Challenges and Opportunities for Treating *Clostridium
difficile* in 2022

Robin Stannard

Abstract Reviews

26 Clinical Effectiveness of Gluten Immunogenic Peptides
During Follow-Up of Coeliac Disease

Latras-Cortés et al.

28 Anxiety, Depression, and Quality of Life in Patients with
Functional Dyspepsia: A Cross-Sectional Study

Kugler

29 Barrett's Oesophagus Surveillance: Can We Do Better?

Soliman and Kapur

32 Interview

Michael Farthing

Articles

38 Editor's Pick: Medullary Carcinoma of the Pancreas: Report of a Rare Pancreatic Malignancy and Review of Literature

Saad et al.

46 Innovative Upper Gastrointestinal Stenting: Reboring the Blocked Path

Bale et al.

55 Implications of the COVID-19 Pandemic on the Management of Inflammatory Bowel Disease in the Low Resource Countries of Asia

Pal et al.

66 Gastrin-17 Levels in Pre-malignancy Gastritis Lesions

Halim and Siregar

73 Conservative Management in a Patient with Recurrent Boerhaave Syndrome

Kaye et al.

80 Retrorectal Teratoma: A Case Report

Saad et al.

Editorial Board

Editor-in-Chief

Prof Sorin Barbu

"Iuliu Hațieganu" University of Medicine and Pharmacy,
Romania

Editorial Board

Prof Dan Dumitrascu

"Iuliu Hațieganu" University of Medicine and Pharmacy,
Romania

Prof Christoph Gubler

Stadtspital Zürich, Switzerland

Dr Hasan Haboubi

Swansea University, UK

Prof Najib Haboubi

Spire Hospital, UK

Dr Waseem Hamoudi

Royal Hospital, Jordan

Dr Panagiotis Kasapidis

Central Clinic of Athens, Greece

Prof Milan Lukáš

Charles University, Czechia

Dr Venkata Pawan Kumar Lekharaju

Wirral University Teaching Hospital NHS Trust, UK

Dr Oliver Grundmann

University of Florida, USA

Dr Devika Kapuria

University of New Mexico, USA

Aims and Scope

EMJ is an online only, peer-reviewed, open access general journal, targeted towards readers in the medical sciences. We aim to make all our articles accessible to readers from any medical discipline.

EMJ allows healthcare professionals to stay abreast of key advances and opinions across Europe.

EMJ aims to support healthcare professionals in continuously developing their knowledge, effectiveness, and productivity. The editorial policy is designed to encourage discussion among this peer group.

EMJ is published quarterly and comprises review articles, case reports, practice guides, theoretical discussions, and original research.

EMJ also publishes 16 therapeutic area journals, which provide concise coverage of salient developments at the leading European congresses. These are published annually, approximately 6 weeks after the relevant congress. Further details can be found on our website: www.emjreviews.com

Editorial Expertise

EMJ is supported by various levels of expertise:

- Guidance from an Editorial Board consisting of leading authorities from a wide variety of disciplines.
- Invited contributors are recognised authorities from their respective fields.
- Peer review, which is conducted by EMJ's Peer Review Panel as well as other experts appointed due to their knowledge of a specific topic.
- An experienced team of editors and technical editors.

Peer Review

On submission, all articles are assessed by the editorial team to determine their suitability for the journal and appropriateness for peer review.

Editorial staff, following consultation with either a member of the Editorial Board or the author(s) if necessary, identify three appropriate reviewers, who are selected based on their specialist knowledge in the relevant area.

All peer review is double blind. Following review, papers are either accepted without modification, returned to the author(s) to incorporate required changes, or rejected.

Editorial staff have final discretion over any proposed amendments.

Submissions

We welcome contributions from professionals, consultants, academics, and industry leaders on relevant and topical subjects.

We seek papers with the most current, interesting, and relevant information in each therapeutic area and accept original research, review articles, case reports, and features.

We are always keen to hear from healthcare professionals wishing to discuss potential submissions, please email: editorial.assistant@emjreviews.com

To submit a paper, use our online submission site: www.editorialmanager.com/e-m-j

Submission details can be found through our website: www.emjreviews.com/contributors/authors

Reprints

All articles included in EMJ are available as reprints (minimum order 1,000). Please contact hello@emjreviews.com if you would like to order reprints.

Distribution and Readership

EMJ is distributed through controlled circulation to healthcare professionals in the relevant fields across Europe.

Indexing and Availability

EMJ is indexed on DOAJ, the Royal Society of Medicine, and Google Scholar®; selected articles are indexed in PubMed Central®.

EMJ is available through the websites of our leading partners and collaborating societies.

EMJ journals are all available via our website: www.emjreviews.com

Open Access

This is an open-access journal in accordance with the Creative Commons Attribution-Non Commercial 4.0 (CC BY-NC 4.0) license.

Congress Notice

Staff members attend medical congresses as reporters when required.

This Publication

ISSN 2054-6203

EMJ **Gastroenterology** is published **once** a year. For subscription details please visit: www.emjreviews.com

All information obtained by EMJ and each of the contributions from various sources is as current and accurate as possible. However, due to human or mechanical errors, EMJ and the contributors cannot guarantee the accuracy, adequacy, or completeness of any information, and cannot be held responsible for any errors or omissions. EMJ is completely independent of the review event (UEG 2022) and the use of the organisations does not constitute endorsement or media partnership in any form whatsoever.

Front cover and contents photograph: Vienna, Austria, home of the **UEG 2022** © **Iliya MITSKAVETS** / stock.adobe.com

Editor

Evgenia Koutsouki

Editorial Managers

Katherine Colvin,
Anaya Malik

Copy Editors

Noémie Fouarge
Kirsty Hewitt, Jaki Smith

Senior Editorial Assistant

Theo Wolf

Editorial Assistants

Natasha Meunier-McVey,
Janet Nzisa, Darcy Richards,
Robin Stannard

Head of Publishing**Operations**

Tian Mullarkey

Design Manager

Stacey Rivers

Senior Designer

Roy Ikoroha

Designers

Steven Paul, Emma Rayner

Junior Designers

Dominic Garwood,
Dillon Benn Grove

Head of Sales

Robert Hancox

Key Accounts Director

Billy Nicholson

Director of Performance

Keith Moule

Chief Executive Officer

Dan Scott

Executive Director

Dan Healy

**Founder and Executive
Chairman**

Spencer Gore



Koutsouki

Evgenia Koutsouki

Editor

Dear Readers,

I am delighted to present the 2022 issue of *EMJ Gastroenterology*, featuring all the key updates from United European Gastroenterology (UEG) Week 2022, which this year took place in Vienna, Austria, and online. As always, the congress was a hotbed for discussions at the forefront of the field, and consisted of many engaging presentations under the overarching theme of 'ingest the best'.

Our journal brings a summary of the congress and spotlights the themes of research presented. Among our congress coverage is a feature use of faecal microbiota transplants as a treatment for *Clostridium difficile* infection, an approach that has been widely discussed over the last decade. Our abstract highlights section includes, among others, a summary of a study on the clinical effectiveness of gluten immunogenic peptides in the follow-up of coeliac disease.

Of course, our journal would not be complete without our selection of reviews, research articles, and case reports. These include a review on management of inflammatory bowel disease during the COVID-19 pandemic in limited resource settings, and our Editor's pick, a case report on medullary carcinoma of the pancreas. Of interest is also a study among professionals and people with inflammatory bowel disease, which looked at the contributing factors in the difference of treatment between older and younger patients with inflammatory bowel disease, and the relation between frailty and therapy goals.

I would like to extend a big thank you to our contributors, reviewers, and Editorial Board, who, alongside the EMJ team have worked to bring this quality content to all of you. Enjoy reading *EMJ Gastroenterology*, and I look forward to next year's congress in Copenhagen, Denmark.

Contact us

Editorial enquiries: editor@emjreviews.com

Sales opportunities: salesadmin@emjreviews.com

Permissions and copyright: accountsreceivable@emjreviews.com

Reprints: info@emjreviews.com

Media enquiries: marketing@emjreviews.com

Foreword

Dear Readers,

I am delighted to welcome you to the 11th edition of *EMJ Gastroenterology*, which delivers the latest clinical advances, expanding knowledge in the field of the digestive system and associated disorders.

This issue presents the highest quality content, and includes a scientific highlights package summarising the most important content from United European Gastroenterology (UEG) Week 2022. Held in Vienna, Austria, as well as on a virtual congress platform provided by the UEG, it facilitated a superb dissemination of significant updates in the world of gastroenterology.

The independent congress review within this eJournal summarises some of the groundbreaking abstracts presented, alongside an insightful feature. Furthermore, the journal features an interview with Michael Farthing, Honorary Professor, University College London (UCL) Medical School, UK, as well as UEG Lifetime Achievement Awardee 2021.

Several peer-reviewed articles at the forefront of research are also enclosed in this edition; however, particular attention should be drawn to the Editor's Pick in this issue. Saad et al. present an enlightening paper on medullary carcinoma of the pancreas, which presents a report and a review of literature. This is an extremely rare subtype of pancreatic adenocarcinoma, and adds to the current data on this condition. Other articles that can be found in this journal include topics such as retrorectal neoplasms, innovative upper gastrointestinal stenting, perspectives on the treatment of inflammatory bowel disease, and so much more.

I hope you find this publication both interesting and thought-provoking, and that you enjoy engaging with the clinical research and medical expertise within this issue of *EMJ Gastroenterology*.



A handwritten signature in blue ink, consisting of stylized letters that appear to be 'S', 'T', and 'B'.

Sorin T. Barbu

Professor of Surgery, "Iuliu Hațieganu" University of Medicine and Pharmacy, Cluj-Napoca, Romania

UEG 2022



Review of the United European Gastroenterology (UEG) Week 2022

Location: Vienna, Austria, and online

Date: 8th–11th October 2022

Citation: EMJ Gastroenterol. 2022;11[1]:8-20. DOI/10.33590/emjgastroenterol/10114687. <https://doi.org/10.33590/emjgastroenterol/10114687>.

'INGEST the best' was the theme for the 30th anniversary of the United European Gastroenterology (UEG) Week, which took place in Vienna, Austria, and virtually on 8th–11th October 2022. The event welcomed over 10,000 registrars, with approximately 19% attending virtually. This year's conference was notable for being the first-ever hybrid UEG week. Attendees came from across the world, with over 113 countries represented, the majority of them in Europe. Helena Cortez-Pinto, UEG President, welcomed all the participants during the Opening Ceremony. Cortez-Pinto encouraged the attendees, especially those who attended virtually, to engage in discussions and access questions via the online platform.

The learning platform was diverse, with a range of live sessions. These included abstract presentations, novel clinical cases, research discussions, and poster exhibitions. With over 2,900 submitted abstracts and over 1,500 posters, there was a lot for everyone to engage with. There were over 430 livestreamed sessions, including a postgraduate teaching programme which kicked off the congress. At the opening ceremony, Cortez-Pinto invited speakers to "five fantastic talks from five fantastic specialists in gastroenterology." Hana Algül, University of Munich, Germany, presented a talk entitled 'Pancreatic

cancer: will it ever be solved?'. Christoph Sarrazin, Goethe-University Hospital Frankfurt, Germany, covered a session entitled 'The history of hepatitis C: a book closed, a problem solved.' Alessandro Repici, Humanitas Research Hospital, Milan, Italy, presented 'Everything has become resectable: is endoscopy the ultimate solution?' Séverine Vermeire, University Hospitals Leuven and Katholieke Universiteit (KU) Leuven, Belgium, discussed 'IBD: ever increasing treatment options and still not solved.' Finally, Michael Farthing, UEG Lifetime Achievement Awardee 2021, presented 'What UEG contributed in 30-years and where we are going.'

A selection of prizes were handed out during the opening ceremony, recognising particularly significant contributions in the field. The UEG Research Prize awardee was Neil Henderson, Centre for Inflammation Research, University of Edinburgh, UK, for his project 'Using integrated single cell genomics and spatial transcriptomics approaches to identify the key therapeutic targets driving the progression of human non-alcoholic steatohepatitis.' The UEG Lifetime Achievement Award was presented to Michael P. Manns, President and Board Member for Research and Education of Hannover Medical School, Germany, for his outstanding contributions to the field



of digestive health and his significant impact on the myUEG Community. The UEG Research Fellowship awardee was Antonio Molinaro, Consultant Hepatologist, Sahlgrenska University Hospital, Gothenburg, Sweden. This award involves UEG giving 50,000 EUR to a researcher to spend 12 months working with a renowned European principal investigator. Laurent Goessens, Department of Gastroenterology and Hepatology, Centre Hospitalier Universitaire UCL Namur, Yvoir, Belgium, received the Journal Best Paper Award. This is a UEG recognition of the best original scientific research published in the *UEG Journal* in the past year.

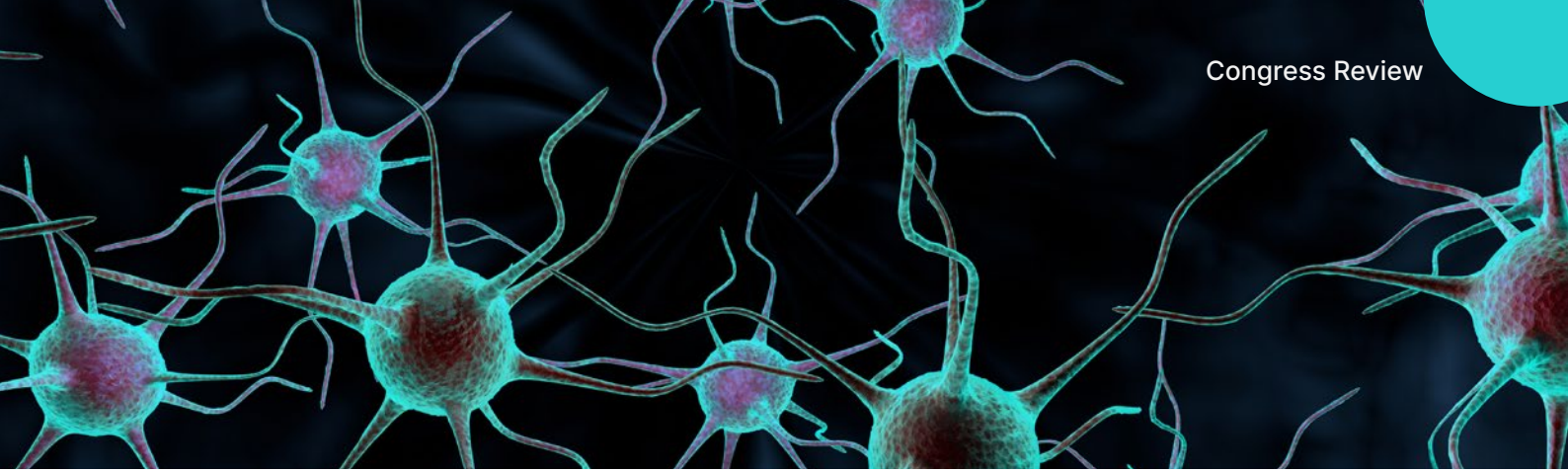
Rising Stars, which are selected by the National Societies Committee and the Scientific Committee based on a record of international quality research and developing scientific independence, were awarded to Liseth Rivero Sánchez, University of Barcelona, Spain; Maja Thiele, Odense University Hospital, Denmark; Julien Kirchgesner, Sorbonne Université, Paris, France; Benjamin Mullish, Imperial College Healthcare

NHS Trust, London, UK; Gianluca Pellino, Università degli Studi della Campania 'Luigi Vanvitelli', Naples, Italy; Salvatore Piano, University of Padova, Padua, Italy; Pedro M. Rodrigues, Donostia University Hospital, San Sebastian, Spain; Fotios Sampaziotis, Cambridge University Hospitals NHS Foundation Trust, UK; David James Tate, University Hospital of Ghent, Belgium; and Tim Vanuytsel, KU Leuven, Belgium.

"We should be incredibly proud of what we, as a community, have achieved," concluded Cortez-Pinto. Indeed, this was a successful event with a great turnout. The next UEG Week in 2023 will be held in Copenhagen, Denmark. The scientific highlights that follow will illuminate those who were unable to attend UEG Week 2022. ●

"We should be incredibly proud of what we, as a community, have achieved."





CXCL8 Aids Recruitment and Proliferation of Myeloid-Derived Suppressor Cells

FURTHER research supports the theory that CXCL8 activity helps to recruit myeloid-derived suppressor cells (MDSC) to nerves that have been invaded by pancreatic cancer cells. Carmen Mota Reyes, Klinikum Rechts der Isar, Technische Universität München, Germany, detailed the findings at this year's UEG Week.

MDSCs are mediators of T cell immunosuppression, which are associated with poor clinical outcomes in patients with solid tumours, including those with pancreatic cancer, and CXCL8 is a known MDSC chemoattractant.

Reyes explained that investigations into 40 patients with pancreatic cancer discovered that MDSCs were in the tumour microenvironment and also the perineural niche of tumour cells. Using RNA sequencing and spatial transcriptomic technology to define the transcriptomic signature of pancreatic cancer with severe neural invasion, the researchers determined the differential gene expression on nerves that had been invaded by tumours and those that had not. The potential invasiveness of pancreatic tumour cells on dorsal root ganglion neurons in the presence of MDSCs was analysed with *in vitro* migration assays and secretome arrays.

Researchers discovered that patients with pancreatic cancer with severe neural invasion had more intratumoural MDSCs, and that the perineural niche of tumour-invaded nerves had increased MDSC infiltration compared with non-invaded nerves. Furthermore, the migratory behaviour of pancreatic cancer cells towards neurons was enhanced by interacting with MDSCs, which lead to more proliferation of MDSC, and increased CXCL8 and CCL5 secretion.

"Researchers discovered that patients with pancreatic cancer with severe neural invasion had more intratumoural MDSCs."

CXCL8 expression was marked significantly highly in tumour-invaded nerves; however, its expression remained constant on tumour cells. Researchers noted that there was increased chemokine activity and CXCR-chemokine receptor binding after enrichment analysis of bulk RNA sequencing.

Reyes believes that these findings support the theory that CXCL8 activity aids the recruitment of MDSCs to nerves that have been invaded by pancreatic cancer cells. ●

Turning Up the Heat for *Helicobacter pylori*

ERADICATION of *Helicobacter pylori* can reduce the risk of upper gastrointestinal (UGI) ulcer bleeding in aspirin users, according to HEAT, a large-scale trial in UK primary care. The results were shared by Christopher John Hawkey, Simple Trials for Academic Research (STAR) Unit, Nottingham Digestive Diseases Centre, University of Nottingham, UK, at the 30th UEG Week.

HEAT researchers investigated whether *H. pylori* eradication could reduce UGI ulcer bleeding with aspirin therapy. Between 2012 and 2017, 30,024 patients aged ≥ 60 years who had been receiving aspirin for a minimum of 4 months were recruited from UK primary care databases. Individuals using proton pump inhibitors, H₂ receptor antagonists, and non-steroidal anti-inflammatory drugs were excluded.

The patients took a C13 urea *H. pylori* breath test. A total of 5,353 had positive tests, and were randomised to receive active eradication treatment (lansoprazole 30 mg, clarithromycin 500 mg, and metronidazole 400 mg twice daily; n=2,677) or matched placebo (n=2,676).

Of the 10% of patients who had an end-of-trial breath test, 90.7% in the treatment group tested negative for *H. pylori*; however, only 24.0% of the controls did. Furthermore, there were

only 18 episodes of UGI ulcer bleeding in the treatment group versus 27 in the control.

"Of the 10% of patients who had an end-of-trial breath test, 90.7% in the treatment group tested negative for *H. pylori*; however, only 24.0% of the controls did."

Researchers found that, during the first 2.5 years, there were 6 episodes of UGI bleedings in the treatment group compared to 17 in the control group. Furthermore, antiplatelet medication use dropped by 12.7% and 12.3% in the treatment and control groups, respectively; however, an analysis of adjusted medication use during the follow-up remained significant, and use of proton pump inhibitors increased in both groups.

There was no advantage in the treatment group after the first 2.5 years for 22 ulcer bleeds, and there was no benefit for eradication for other clinically significant gastrointestinal bleeding, clinically detected uncomplicated ulcers, or dyspepsia. Unfortunately, 306 patients in the treatment group and 351 in the control group died. ●





Upadacitinib Effective in Treating Ulcerative Colitis

UPADACITINIB 15 mg or 30 mg is more effective in the treatment of moderately to severely active ulcerative colitis (UC) than placebo, in terms of clinical remission at Week 52. The results of the Phase III U-ACHIEVE study were presented at UEG Week 2022.

Upadacitinib, an oral selective and reversible Janus kinase inhibitor, was shown to be superior to placebo. The multicentre, randomised, double-blind, placebo-controlled study evaluated the safety and efficacy of maintenance upadacitinib in patients with UC. The primary endpoint was clinical remission, defined by an adapted Mayo score of ≤ 2 , and secondary endpoints included endoscopic improvement and remission, maintenance of clinical remission, steroid-free clinical remission, and histologic endoscopic mucosal improvement. Participants had achieved clinical response when using 45 mg of upadacitinib once daily following 8 weeks of induction therapy. They were randomised to receive placebo, upadacitinib 15 mg, or upadacitinib 30 mg. At Week 52, the number of patients who achieved clinical remission was significantly higher in those treated with upadacitinib 15 mg and 30 mg (40.4% and 53.6%, respectively), compared to those who received placebo (10.8%). Those who received upadacitinib

were also more likely to achieve the secondary endpoints. Furthermore, those who received the treatment showed reductions in bowel urgency.

Regarding safety, 9.4% of patients taking placebo experienced a serious adverse event, compared to 8.4% with upadacitinib 15 mg and 30 mg. This led to treatment discontinuation in 10.2% of the placebo group, 4.0% of the upadacitinib 15 mg group, and 7.2% of those taking upadacitinib 30 mg. Other adverse events included worsening UC, which occurred in 30.0% of those receiving placebo and 11.6% of those receiving 15 mg of upadacitinib. In those receiving 30 mg, the most common adverse event was nasopharyngitis (10.4%). Furthermore, 3.6% of patients on 15 mg, 2.8% of those on 30 mg, and 3.3% of those on placebo reported serious infections. In those taking upadacitinib 15 mg and 30 mg, thromboembolic events were reported in two patients for each group, as well as herpes zoster in 4.8% and 5.6%, respectively. Finally, one patient from the placebo group and from the 15 mg group, and two patients from the 30 mg group reported malignancies, excluding non-melanoma skin cancer; and one patient in the placebo group and the 30 mg group reported major adverse cardiovascular events. ●

"At Week 52, the number of patients who achieved clinical remission was significantly higher in those treated with upadacitinib 15 mg and 30 mg (40.4% and 53.6%, respectively), compared to those who received placebo (10.8%)."

Immune Checkpoint Blockade Leads to Longitudinal Changes in Gut Microbiome

NEW data following a study that explored the dynamics of the gut microbiome during immune checkpoint blockade (ICB) shows longitudinal changes in the gut microbiome in response to the treatment.

By profiling the longitudinal gut microbiome of patients with advanced cancer, pharmacomicrobiomic interactions associated with the increased success of ICB could be better understood. The study analysed the gut microbiome of 75 patients affected by advanced melanoma, who were undergoing ICB. The researchers performed shotgun metagenomic sequencing on stool samples in order to compare the microbiome before and during treatment, as well as to explore its correlation with treatment success, which was measured through 12-month progression-free survival. Through a regression model, researchers estimated the changes in metabolic pathways and bacterial species, and disentangled the longitudinal effects of these factors.

Researchers also analysed the effects of treatment characteristics, such as the differences between patients who responded to single or combination ICB; patients who experienced immune-related adverse events such as colitis; and patients with prior exposure to antibiotics or proton pump inhibitors.

The findings showed that patients who did not respond to ICB experienced a greater loss of diversity compared to those who did respond. They also confirmed that the microbial biomarkers that were found at baseline increased longitudinally during treatment. The

researchers found higher and increasing abundances of *Actinomycetaceae* and *Lachnospiraceae* in those who responded to single ICB treatment, and of several *Bacteroides* species in those receiving combination ICB. Furthermore, there were higher abundances of *Roseburia faecis*, *R. lactaris*, and *Coproccoccus* after the last treatment injection in those who responded to both ICB regimens compared to non-responders. In those who were affected by colitis and received both regimens, three *Clostridia* species were found to be increased; however, those who did not develop colitis and responded to single ICB showed more *F. prausnitzii*, *Bifidobacterium bifidum*, and *K. pneumoniae*; and those who received combination ICB had more *Bacteroides caccae*, *R. lactaris*, and *Parasutterella excrementihominis*.

"The results show that the design of microbiome-based interventions should not rely solely on baseline predictive biomarkers, in order to increase their efficacy."

The results show that the design of microbiome-based interventions should not rely solely on baseline predictive biomarkers, in order to increase their efficacy. Furthermore, the study identified species biomarkers which clinicians could use to monitor patients who are receiving immunotherapy, and to monitor the development of colitis. ●

Type 1 Diabetes Complications Linked to Alterations in Gut Microbiota

A STUDY conducted in the Netherlands has discovered that patients with long-term Type 1 diabetes (T1D) have altered gut microbiota in comparison to the general population. These changes, in both composition and function, are linked to the characteristics and vascular complications of T1D. The study's findings also suggest that a dysbiotic gut microbiome could be a contributor to the disease progression of T1D.


Researchers carried out metagenomic sequencing using stool samples, in order to pinpoint the characteristics of gut microbiota. The sample size was 239 patients, all of whom had longstanding T1D. These patients were compared to a control cohort, including 2,937 age-, sex-, and BMI-matched subjects, none of whom reported any serious or chronic diseases.

No difference in α -diversity was discovered between cohorts. However, 82 bacterial taxa were found to be significantly altered in patients with T1D. Of these, 37 were enriched, including with *Clostridiales* and *Oscillibacter* pathogens; and 43 were

depleted, including *Alistipes*, *Dorea*, and *Bifidobacterium*. A multivariate analysis of variance and logistic regression allowed researchers to discover that multiple phenotypes related to diabetes were associated with microbiota composition, biochemical functions, and individual microbial species.

"The study's findings also suggest that a dysbiotic gut microbiome could be a contributor to the disease progression of T1D."

Diabetic nephropathy was linked to variations in nine taxa, including bacterial increases from the order *Clostridiales*, and alterations in 29 microbial pathways, including increases in pathways involved in bacterial cell membrane biosynthesis, and reduced lipid metabolism. Lower effects were found with other comparable results, including Hb1Ac, diabetic retinopathy, and micro- and macrovascular complications. ●



Novel System Finds Potentially Avoidable Cases of Pancreatic Cancer

A NOVEL system, which uses cross-sectional imaging, has identified previously missed instances of pancreatic cancer. These cases may have been avoidable, and led to poorer clinical outcomes, as there is only a brief period of time when curative surgery can be carried out.

In this first detailed analysis, which aimed to establish a plausible explanation for cases of potentially missed pancreatic cancer on imaging, researchers discovered that missed opportunities to avoid instances of post-imaging pancreatic cancer were identified in 36% of cases.

Electronic records of 600 patients, who were diagnosed with pancreatic cancer between 2019–2021 at two National Health Service (NHS) sites in the UK, were explored. Post-imaging pancreatic cancer was characterised as a pancreatic cancer diagnosed between 3–18 months following either abdominal computed tomography or magnetic resonance imaging, which did not diagnose pancreatic cancer. The cross-sectional imaging, which did not diagnose the cancer, and later diagnostic imaging, which did, were independently reviewed. Researchers created an algorithm to categorise post-imaging pancreatic cancer, and to identify the most fitting reason for the cancer being missed.

Post-imaging was categorised in the following way: Type 1 as a missed pancreatic cancer lesion, and imaging proved inadequate to exclude the lesion (10.6%); Type 2 as a missed pancreatic cancer lesion because of perceptual error, which was detected on later scans

(25.5%); Type 3 as a pancreatic cancer abnormality detected, for instance, pancreatic or bile duct dilatation without focal lesion, but without a follow-up plan for management of disease (10.6%); Type 4 as a pancreatic cancer-associated lesion located, with adequate follow-up management (12.8%); and Type 5 as a new pancreatic cancer lesion with no abnormality, which was detected on initial imaging, and with adequate imaging to exclude a lesion (40.4%).

"Researchers created an algorithm to categorise post-imaging pancreatic cancer, and to identify the most fitting reason for the cancer being missed."

Of the 600 reviewed cases in the study, 46 (7.7%) were categorised as post-imaging pancreatic cancer, from CT (n=32) and MRI scans (n=4). Seven CT scans were without contrast. To conclude, 26% of patients were found to have imaging signs of pancreatic cancer which were investigated further following review. Thirty-six percent of cases were considered to be potentially avoidable, a figure which calls attention to the frequency of missed opportunities in clinical settings.

Researchers believe that using this analysis system has the ability to standardise the investigation of post-imaging pancreatic cancer, and also to improve the outcomes for patients diagnosed with pancreatic cancer. ●

Artificial Intelligence to Predict Abdominal Pain in Children

ABDOMINAL pain is a common complaint in childhood, with prevalence rates ranging from 0.3% to 19.0%. Although various risk factors have been reported, additional studies are necessary to determine which of these play a more significant role. A presentation at UEG Week 2022 spotlighted findings from a study that employed artificial intelligence (AI) models to predict clinical outcomes and help delineate the main factors involved in abdominal pain in children.

Researchers examined the records of 1,274 children with abdominal pain in the Born in Bradford birth cohort, and assessed the frequencies of comorbidities associated with the condition. These were compared with the records of children in the same cohort without abdominal pain who experienced one of the associated comorbidities. The children's mothers were also included.

The Cox proportional hazards model was used to analyse the relationship between the risk factors and abdominal pain in children. Allergic diseases, such as asthma, hay fever, urticaria, and eczema, were significant protective factors for children's abdominal pain. Conversely, mothers' abdominal pain was shown to be a significant risk factor (hazard ratio: 1.33; 95% confidence interval [CI]: 1.17–1.50; $p < 0.001$).

Three AI models were created based on the variables used in the Cox model. Model 1 included 40 clinical features from children and their mothers, Model 2 excluded children's allergic diseases, and Model 3 included only children's clinical features. Model 1 (area under the curve [AUC]: 0.84; 95% CI: 0.82–0.87) was found to outperform Model 2 (AUC: 0.65; 95% CI: 0.61–0.68; $p < 0.001$). Further comparison found that the performance of Model 1 was similar to that of Model 3 (AUC: 0.83; 95% CI: 0.80–0.86; $p = 0.164$). Feature importance of Model 1 highlighted that allergic comorbidities of children, chiefly eczema, primarily contributed to the model.

"A presentation at UEG Week 2022 spotlighted findings from a study that employed artificial intelligence (AI) models to predict clinical outcomes and help delineate the main factors involved in abdominal pain in children."

Ultimately, this research could aid the diagnosis of abdominal pain in children. Going forward, a more detailed clinical picture input might improve prediction. ●



Findings from GI-COVID-19 Presented at UEG WEEK 2022

RESULTS from GI-COVID-19 were shared at UEG Week 2022, which took place in Vienna, Austria, between 8th–11th October. This prospective, multicentre study investigated the prevalence of gastrointestinal (GI) symptoms and post-infection disorders of gut–brain interaction up to 12 months after hospitalisation with COVID-19, as well as factors associated with their occurrence.

Patients with and without a diagnosis of COVID-19 were recruited at hospital admission and asked for GI symptoms after 1, 6, and 12 months, using the validated Gastrointestinal Symptoms Rating Scale (GSRS), the Rome IV Diagnostic Questionnaire to screen for functional GI disorders in adults, and the Hospital Anxiety and Depression Scale (HADS).

The study included patients from 36 centres across 12 countries. In total, 883 patients (614 who tested positive for COVID-19 and 269 controls) were included for the primary analysis. Of these, 435 with COVID-19 and 188 controls completed the 12 month follow-up. At enrolment, GI symptoms occurred more frequently in patients with COVID-19 (59.3%) than in the control group (39.7%) ($p < 0.001$). Individuals with COVID-19 reported a higher presence of nausea, diarrhoea, loose stools, and urgency compared to controls.

At 1-month follow-up, nausea and acid regurgitation were significantly more prevalent in patients with COVID-19 compared to the control group (8.7% versus 1.7%; $p = 0.015$ and 8.4% versus 2.1%; $p = 0.006$, respectively). At the 6-month evaluation, those with COVID-19 reported lower rates of flatus, constipation, and hard stools relative to the controls. At 12 months, constipation and hard stools were significantly less prevalent in people with COVID-19 than in the controls (9.6% versus 16%; $p = 0.019$ and 10.9% versus 17.7%; $p = 0.011$, respectively).

"RESULTS from GI-COVID-19 were shared at UEG Week 2022, which took place in Vienna, Austria, between 8th and 11th October."

During follow-up, disorders of the gut–brain interaction were more frequently reported by patients with COVID-19. Of note, statistically significant differences were found only for irritable bowel syndrome according to Rome III and Rome IV criteria. Factors significantly associated with irritable bowel syndrome diagnosis were anamnestic allergies, chronic intake of proton pump inhibitors, and dyspnoea. ●





Does Colonoscopy Screening Reduce Incidence of Colorectal Cancer?

PERFORMING one colonoscopy screening reduces the incidence of colorectal cancer (CRC) over 10 years, according to data presented at UEG Week 2022. This trial was performed due to the lack of randomised trials to assess the benefits of screening for colorectal cancer through colonoscopy.

The NordICC trial included participants aged 55–64 years in Norway, Sweden, and Poland, who were randomised to a standard-of-care with no screening (56,365 participants) or a colonoscopy (28,220 participants). The incidence and mortality of CRC were assessed after 10 years, adjusted for screening participation. Screening attendance was 42.0%, and there were no perforations or screening-related deaths following the 30 days after the procedure. Fifteen patients experienced bleeding after polyp removal.

The median follow-up was 10 years, during which 622 CRCs were diagnosed in the no screening group, versus 259 in the screening group. The incidence of CRC was 1.20% in the no-screening

group, compared to 0.98% in the screening group, leading to a risk reduction of 18% (risk ratio [RR]: 0.82; 95% confidence interval [CI]: 0.70–0.93). Furthermore, CRC mortality in the no screening group was 0.31%, versus 0.28% in the screening group (RR: 0.90; 95% CI: 0.64–1.16).

"The incidence of CRC was 1.20% in the no-screening group, compared to 0.98% in the screening group, leading to a risk reduction of 18%."

To prevent one CRC, the number of invitations to screening required was 455 (95% CI: 270–1,429). CRC incidence and mortality were reduced from 1.22% to 0.84% (RR: 0.69; 95% CI: 0.27–0.77), and from 0.3% to 0.15% (RR: 0.50; 95% CI: 0.27–0.77), respectively. All-cause mortality was the same in both groups (11.04% in the no screening group versus 11.03% in the screening group). ●

Post-Endoscopic Submucosal Dissection Oesophageal Stricture Prevention: Oral Prednisolone versus Local Triamcinolone Injection

PHASE III multi-institutional, open label randomised controlled trial (JCOG1217) data has revealed that administration of oral prednisolone following endoscopic submucosal dissection (ESD) is not superior in preventing oesophageal stricture development when compared to local triamcinolone injection (LTI) administration.

LTI is the current standard practice for prevention of oesophageal stricture following ESD; however, there is the risk of serious adverse events as well as technical difficulties associated with the procedure. Although steroids have their own associated side effects and adverse events, oral prednisolone administration (OPA) has been considered as an alternative to LTI because no specialist skill is required.

Researchers from the Gastrointestinal Endoscopy Study Group of the Japan Clinical Oncology Group trial sought to assess whether OPA conferred benefits compared to LTI in preventing post-ESD oesophageal stricture, measured by stricture-free survival (SFS). SFS was defined as need for endoscopic balloon dilation, dysphagia score ≥ 2 , and inability to pass standard endoscope, or death.

Between September 2014–November 2020, the team enrolled 281 patients aged between 20–85 years of age with a histologically confirmed diagnosis of thoracic oesophageal squamous cell carcinoma (Tumour in-situ or T1a

staging and primary lesion covering $\geq 50\%$ of the luminal circumference).

Candidates were randomised on a 1:1 basis to either LTI (n=141) or OPA (n=140). Of these 281 patients, 272 underwent ESD followed by either LTI or OPA. Those in the OPA arm received an 8-week tapering course of oral prednisolone, starting at 30 mg/day on Day 3 post-ESD. Those in the LTI arm received a one-off 100 mg triamcinolone injection directly after ESD.

"Overall, the findings showed that OPA was not superior to LTI in preventing post-ESD oesophageal stricture."

SFS at 12 weeks was 94.8% (95% confidence interval [CI]: 89.4–97.5) in the OPA arm and 88.5% (95% CI: 81.6–92.9) in the LTI arm. The hazard ratio was 0.672; 90% CI: 0.361–1.250; one-sided $p=0.1444$, showing no superiority in using OPA versus LTI. No significant difference in endoscopic balloon dilation rates or adverse events were seen between the two arms, and there were no treatment-related deaths. Hyperglycaemia and hypertension were seen in both arms and there were three instances of delayed perforation in the LTI arm. Overall, the findings showed that OPA was not superior to LTI in preventing post-ESD oesophageal stricture. ●



EMJ Podcasts

The EMJ Podcast aims to provoke conversations around the latest trends and innovations in healthcare, provide engaging and educational content for healthcare professionals, and hosts conversations with physician entrepreneur, Jonathan Sackier.

Listen today

www.emjreviews.com

EMJ



Challenges and Opportunities for Treating *Clostridium difficile* in 2022

Authors: Robin Stannard, Editorial Assistant

Citation: EMJ Gastroenterol. 2022;11[1]:22-25. DOI/10.33590/emjgastroenterol/10181909. <https://doi.org/10.33590/emjgastroenterol/10181909>.



IN A symposium session presented at United European Gastroenterology (UEG) Week 2022, experts delved into the challenges presented by *Clostridium difficile* infection (CDI) and the opportunity that faecal microbiota transplants (FMT) can provide. Benjamin Mullish, Gastroenterology and Hepatology Division of Digestive Diseases, Imperial College London, UK, and Georgiana-Emmanuela Gîlcă-Blanariu, Grigore T. Popa University of Medicine and Pharmacy, Iași, Romania, shared novel research and real-world experience. The symposium examined all aspects of CDI from the importance of understanding pathways of pathophysiology to the logistical challenges that pioneering an FMT clinic can present.

THE BURDEN OF CLOSTRIDIUM DIFFICILE INFECTION

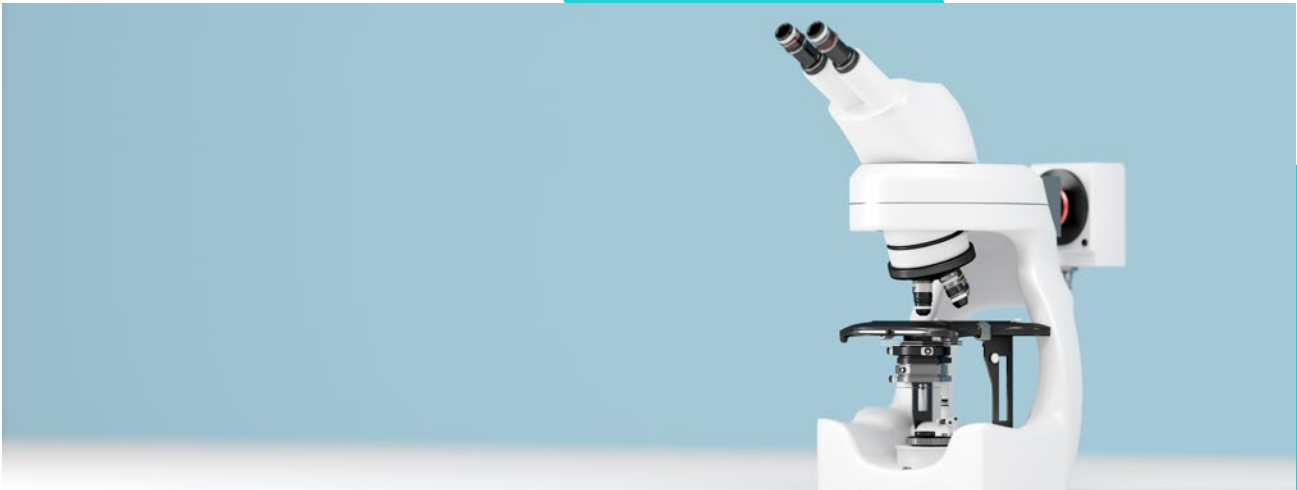Mullish, a thought-leader on the topic of CDI, introduced the challenge of the infection and the impact it has on individuals and populations. In the USA, more than 500,000 cases of CDI are diagnosed per year; however, more concerning is the apparent shift in epidemiology, with CDI increasingly affecting the young and healthy, a population without typical risk factors. The infection still presents considerable risk of morbidity and mortality, resulting in huge implications for healthcare resourcing and patient quality of life. Novel challenges in the microbiology of CDI include hypervirulent strains and high rates of non-responsiveness to antibiotics and infection recurrence. All these aspects of CDI make it difficult to treat. New therapies such as FMT offer opportunities for improved outcomes; however, challenges regarding expense, logistics, and availability prevent FMT from acting as a silver bullet for treating patients with CDI.

UNDERSTANDING THE PATHOMECHANISMS OF CLOSTRIDIUM DIFFICILE INFECTION

Mullish questioned the audience on how to better respond to and treat patients. Mullish's answer was simple: treatment options and new therapies can be improved by better understanding the underlying mechanisms of pathology behind CDI. Mullish broke down these into three mechanism categories: bacterial factors, host-bacterial interaction, and host factors. Mullish went on to discuss novel research that demonstrates how increased understanding can lead to innovative treatment options.

The essential bacterial factor that Mullish wished to highlight was the *C. difficile* adhesin proteins, called surface layer proteins (SLP). Anti-SLP antibodies can be detected in the serum of patients with CDI. Previous experiments in mice have demonstrated a protective immune response against CDI after rectal SLP exposure. This was further confirmed

2022
UEG



by detectable serum Ig following exposure. A further study where SLP was genetically engineered to be constitutively expressed in lab animals resulted in a protective response against CDI.

Mullish then focused on the host–bacterial interaction, more specifically gut microbial metabolites. Firstly, p-Cresol is a metabolite produced by *C. difficile*. *C. difficile* is one of only four gut-residing bacteria that can produce the organic compound. When formed, p-Cresol kills other Gram-positive bacteria in the gut, therefore giving *C. difficile* a competitive advantage in this environment. Although it is not currently a druggable target, p-Cresol has the potential to be a target for future therapies aiming to undermine the competitive advantage of *C. difficile*. Furthermore, p-Cresol could become a sensitive and specific potential diagnostic factor. Mullish then highlighted succinate, a chemical produced by bacterial fermentation in the gut. *C. difficile* can exploit succinate for energy to produce butyrate. FMT from a healthy human microbiota reduces the availability of luminal succinate for *C. difficile* to exploit. Here, FMT acts as a source of competitive niche exclusion for the carbon energy source *C. difficile* requires.

Small chain fatty acids (SCFA) are produced from undigested protein and carbohydrate elements and exert a net anti-inflammatory effect over the gut. Previous investigations have suggested that SCFAs have anti-*C. difficile* effects, which are induced by the inhibition of toxin production. FMT is associated with the restoration of SCFAs, as well as the variety of biofluids in the gut back to pre-morbid levels in patients with CDI.

The final group of metabolites that Mullish drew attention to were the bile acids. Primary bile acids are metabolised to secondary bile acids by enzymes, 7- α -hydroxylase, and bile salt hydroxylase, in the gut. Primary bile acids exert pro-*C. difficile* effects, whereas secondary bile acids have anti-*C. difficile* effects, inhibiting growth and toxin activity. Both enzymes for metabolising bile acids are found lacking in the gut of patients with CDI. Furthermore, secondary bile acids can be used as a predictive tool for the recurrence of CDI. Mullish shared research that they carried out as part of their own PhD, which demonstrated that FMT can restore secondary bile acids, and that FMT therapies are associated with restoration of the pre-morbid gut bile enzyme profile.

"Mullish summarised their presentation by highlighting how FMT can impact CDI on multiple levels, from changing metabolites in the gut to optimising elements of host physiology."

Finally, Mullish delved into the interactions of host factors such as Igs, glycans, and microRNAs. Evidence has shown that hosts secrete different IgAs pre- and post-FMT. Additional studies have demonstrated significant differences in serum glycan before and after FMT, with a marked simplification of glycans relating to Igs. Researchers were able to demonstrate changes in host microRNAs, as well as transcriptional changes and differences in protein production linked to changes in the level of toxins post-FMT. Mullish summarised their presentation by highlighting how FMT can impact CDI on multiple levels, from changing metabolites in the gut to optimising elements of host physiology.

PIONEERING FAECAL MICROBIOTA TRANSPLANTS CLINICS

The challenges of treating CDI were also explored by Gîlcă-Blanariu. In their presentation, however, Gîlcă-Blanariu focused on the logistical challenges that surround the provision of FMT treatment. Gîlcă-Blanariu discussed the barriers that they had experienced and overcome when introducing the first FMT clinic to Romania. Over the last year, studies have established FMT as both safe and efficacious, with overall success rates of approximately 90% for treating recurrent CDI (at least two episodes). Furthermore, emerging evidence suggests that FMT is an effective option for treating first-line CDI.

Gîlcă-Blanariu began their presentation by discussing the key steps involved in implementing and running an FMT clinic in Romania. Gîlcă-Blanariu highlighted the necessity of learning and training from experts around the globe who already have practicing FMT clinics; the complexity of conceiving national guidelines for FMT practice; identifying clinical and legal frameworks; and the logistics of building an electronic database for managing details of donors and FMT recipients. Although the projected steps were at initial assessment

clear and achievable throughout the project, Gîlcă-Blanariu and their team encountered numerous unexpected challenges to the provision of FMT for patients with CDI.

The COVID-19 pandemic delayed training activities planned at an FMT facility in Birmingham, UK, forcing the training to occur online. This also delayed the creation of national guidelines surrounding FMT practice so that they could include updated advice about COVID-19 safety.

Legal framing also presents a unique challenge. FMT is not yet formally regulated in Europe, with regulations differing in classification as a medical treatment versus a transplant across different locations. This resulted in the need for insurance coverage, which led to the practice being defined as an advanced therapeutic medicinal product by Romania. A proposal for regulation has recently been made in July 2022 to the European Commission (EC) to define FMT as a transplant.

Gîlcă-Blanariu and their team encountered further issues with the understanding of FMT amongst medical practitioners. In a survey of medical students, only 34% of the respondents were classified as having a medium level knowledge of FMT. Furthermore, 75% of respondents were worried about the risk of transmitting a disease undetected by donor screening to recipients. This level of understanding in the field indicates a general lack of knowledge about the benefits FMT can provide. This lack of understanding extends to, and

"Over the last year, studies have established FMT as both safe and efficacious, with overall success rates of approximately 90% for treating recurrent (at least two episodes) CDI."

is multiplied in, the general population. This misconception can hugely impact the number of willing donors, making programmes difficult to initiate and run.

The presentation closed with a summary by the session chair Juazos Kupinskas, Department of Gastroenterology & Institute for Digestive Research, Lithuanian University of Health Sciences (LSMU), Kaunas, Lithuania, who explained that lack of knowledge, logistical barriers, expense, and unforeseen challenges result in underserving patients with CDI, and in a lack of access to the proven effective treatment of FMT.

CONCLUDING COMMENTS

CDI is a globally ubiquitous challenge, which demonstrates concerning epidemiological profiles of increasingly younger and healthier populations. Research has demonstrated that FMT can fight infection on multiple pathological mechanistic levels. However, logistics, expense, and educational and regulatory barriers can make FMT clinics difficult to establish and run. Further investment in research, education, and provision is needed to make treatment accessible to all the populations that need it. ●





Abstract Reviews

Sharing insights from abstracts presented at the United European Gastroenterology (UEG) Week 2022, global gastroenterologists and researchers have provided these overviews of their fascinating studies.

Clinical Effectiveness of Gluten Immunogenic Peptides During Follow-Up of Coeliac Disease

Authors: *I. Latras-Cortés,¹ M. Cid Martínez,² S. Diez Ruiz,¹ V. Blázquez Ávila,¹ I. González Puente,¹ L. Alcoba Vega,¹ R. González Núñez,¹ A. Martín Izquierdo,¹ S. Borrego Rivas,¹ L. Vaquero Ayala,¹ A.B. Domínguez Carbajo,¹ D. López Cuesta,¹ S. Vivas Alegre,¹ F. Jorquera Plaza¹

1. Department of Gastroenterology, University Hospital of León, Spain

2. University of Salamanca, Spain

*Correspondence to irenelatras cortes@gmail.com

Disclosure: The authors have disclosed no conflicts of interest.

Keywords: Coeliac disease, gluten immunogenic peptides (GIP).

Citation: EMJ Gastroenterol. 2022;11[1]:26-27. DOI/10.33590/emjgastroenterol/10070852. <https://doi.org/10.33590/emjgastroenterol/10070852>.

BACKGROUND AND AIMS

A gluten-free diet is the only therapy that provides clinical and histological remission of coeliac disease. The detection of gluten immunogenic peptides (GIP) in faecal samples, only present if gluten is ingested, may constitute a useful tool to evaluate dietary adherence.

MATERIALS AND METHODS

This is an observational, retrospective, longitudinal, between-groups study design. The

authors collected clinical data from patients who had GIP measurement during follow-up from January 2017–June 2021. A descriptive and comparative analysis was performed using SPSS software (IBM, Armonk, New York, USA).

The primary objective was to evaluate the clinical effectiveness of GIP measurement during follow-up of patients with coeliac disease. The secondary objective was to analyse the relation between GIP levels and demographic data (gender and age), laboratory results, and histopathology.

RESULTS

Of the 103 patients included, 182 faecal samples were obtained. The characteristics are summarised in [Table 1](#). A total of 29 patients had positive levels of GIP; 12 of them normalised during follow-up (41.38%).

No differences were found between haemoglobin, ferritin, mean corpuscular volume, or antibody levels, and the result (positive/negative) of GIP in the total samples, nor when analysing the samples of adults and children separately. Only anti-gliadin IgG antibodies were higher in GIP-positive patients ($p=0.028$). No differences were found between the result (positive/negative) of GIP and histology at diagnosis, gender, or age (adults/children). It is important to mention that 77 patients had negative anti-tissue transglutaminase levels and 21 of them (27.27%) had GIP in faeces.

The authors did not find differences in the result of GIP depending on age or disease duration. However, when paediatric patients were selected, positivity for GIPs increased with age ($p=0.032$).

CONCLUSION

GIPs are a useful tool in the follow-up of patients with coeliac disease to monitor dietary compliance, and may detect dietary transgression in subjects with negative

antibodies. Antibody levels, age, and disease duration are not associated with positivity rates of GIP. Only adolescents in the paediatric group had more dietary transgressions according to detection of GIP. ●

Table 1: Characteristics of patients included (N=103).

Age (years)	18.32 (SD=17.55)
Children/adults	58 (57%)/43 (43%)
Gender (female/male)	73 (71%)/30 (29%)
Disease duration (months)	65.14 (SD=59.86)
GIP-positive	29 (28%)
Anti-tissue transglutaminase IgA (UI IgA/mL)	9.37 (SD=24.45)
Anti-gliadin IgA (mg/L)	11.87 (SD=33.44)
Anti-gliadin IgG (mg/L)	7.91 (SD=22.16)
Haemoglobin (g/dL)	14.08 (SD=1.23)
Mean corpuscular level (fL)	85.01 (SD=8.65)
Ferritin (ng/mL)	51.79 (SD=42.34)

Quantitative variables are expressed as means and SD; qualitative variables are presented as total number of events and percentage.

GIP: gluten immunogenic peptides; SD: standard deviation.

Anxiety, Depression, and Quality of Life in Patients with Functional Dyspepsia: A Cross-Sectional Study

Authors: *Tatyana Kugler

Donetsk National Medical University, Ukraine
*Correspondence to kugler2@mail.ru

Disclosure: The author has declared no conflicts of interest.

Keywords: Anxiety, depression, functional dyspepsia (FD), quality of life (QoL).

Citation: EMJ Gastroenterol. 2022;11[1]:28-29.
DOI/10.33590/emjgastroenterol/10141377. <https://doi.org/10.33590/emjgastroenterol/10141377>.

BACKGROUND AND AIMS

Functional gastrointestinal disorders are often associated with changes in the psycho-emotional sphere. The urgency of the problem is determined by the fact that functional diseases mainly affect young people of working age. This makes the problem not only medical but also social.

The aims of this study were to evaluate the clinical characteristics of anxiety and depression in different subtypes of functional dyspepsia (FD) group in comparison to a control group and to establish the presence of a possible correlation between anxiety/depression and quality of life (QoL).

Table 1: Hospital Anxiety and Depression Scale (HADS) indicators of functional dyspepsia and control groups.

		Functional dyspepsia group		Control group	
		Anxiety	Depression	Anxiety	Depression
Factors					
Sex	Male	6.54±3.55*	5.86±3.57†	4.96±2.76	3.17±2.79
	Female	8.54±3.70*	7.47±3.80†	3.56±2.13	4.20±3.31
Subtype	PDS	7.43±3.56†	6.90±3.71†	N/R	N/R
	EPS	8.18±3.57†	6.45±3.80		
	Overlap	8.50±4.06†	7.16±3.96†		
Severity of symptoms	Moderate	7.92±3.74*	6.94±3.78*	N/R	N/R
	Severe	7.96±3.80*	7.06±3.80*		
Duration	<3 years	7.45±3.67†	6.54±3.76†	N/R	N/R
	3–5 years	7.12±3.88†	6.96±3.89†		
	>5 years	8.01±3.47†	7.34±3.23†		

*p<0.05 in comparison with the control group and intragroup indicators.

†p<0.05 in comparison with the control group.

EPS: epigastric pain syndrome; N/R: not reported; PDS: postprandial distress syndrome.

MATERIALS AND METHODS

In total, 125 patients with FD (Rome IV criteria) and 70 healthy volunteers were included in this cross-sectional study. All participants filled out the Hospital Anxiety and Depression Scale (HADS) to identify anxiety and depression, the Short Form-8 (SF-8) questionnaire (standard 4-week form) to assess QoL, and the Leuven Postprandial Distress Scale (LPDS) to rate the severity of epigastric pain (burning) or abdominal discomfort. Linear regression analysis was performed in the case of functional relationships between two groups of random variables. Results obtained with $p < 0.05$ and 95% confidence intervals were considered statistically significant.

RESULTS

Anxiety and depression were observed in 50.4% and 42.4% of patients with FD, respectively, and in 13.3% and 6.66% of healthy volunteers ($p < 0.001$). The average anxiety score in patients with FD was higher than in controls (7.93 versus 4.17; $p < 0.001$), with a maximum score of 17. The average score of depression in patients with FD was also higher (6.94 versus 3.40; $p < 0.001$), with

a maximum score of 15. All patients with FD had a low level of QoL, both due to physical health and emotional and psychological components compared with controls ($p < 0.001$). A positive correlation was found between the levels of anxiety and depression and the severity of clinical manifestations of the disease ($r = 0.353$ and $r = 0.291$; $p < 0.05$). A negative correlation was observed between the severity of dyspepsia and the QoL of patients ($r = -0.264$; $p < 0.05$). The linear correlation was found between the QoL (physical health) and depression ($r = -0.311$; $p = 0.004$). The results are summarised in [Table 1](#).

CONCLUSION

Mental disorders are associated with changes in visceral sensitivity in patients with FD, who perceive pain impulses as aggravated. The HADS assessment showed that anxiety outweighed depression. The most significant factors influencing the level of anxiety and depressive disorders in the FD group were the patient's gender and the severity of clinical symptoms. Self-reported symptom severity, anxiety, and depression were clearly and independently associated with QoL. ●

Barrett's Oesophagus Surveillance: Can We Do Better?

Authors: *Mina Soliman,¹ Kapil Kapur²

1. Medicine, Medway Maritime Hospital, Gillingham, UK

2. Gastroenterology, Barnsley Hospital NHS Foundation Trust, UK

*Correspondence to Mina.Soliman123@hotmail.com

Disclosure: The authors have declared no conflicts of interest.

Keywords: Barrett's oesophagus (BO), dedicated lists, surveillance.

Citation: EMJ Gastroenterol. 2022;11[1]:29-30. DOI/10.33590/emjgastroenterol/10163417. <https://doi.org/10.33590/emjgastroenterol/10163417>.

BACKGROUND AND AIMS

Barrett's oesophagus (BO) has a premalignant potential. Several guidelines to optimise surveillance and early detection of dysplasia were produced.¹⁻³ A previous audit in the authors' hospital revealed significant departure from the guidelines. Dedicated lists and educational intervention were suggested to improve the quality of surveillance.^{4,5} The authors aimed to evaluate the compliance of BO surveillance with the published guidelines in their centre between 1st February 2021 and 31st March 2022 after the introduction of dedicated lists with longer time slots of 30 minutes.

MATERIALS AND METHODS

A retrospective database search was performed for the word "Barrett" using the built-in audit tool of Infoplex v.5 reporting system and cross-

referenced with the histopathology database. Surveillance details were added to an Excel (Microsoft, Redmond, Washington, USA) spreadsheet against criteria extracted from both the British Society of Gastroenterology (BSG) and the European Society of Gastrointestinal Endoscopy (ESGE) guidelines. Results were compared with the previous audit.

RESULTS

During the study period, 204 BO reports were found. The number of patients undergoing surveillance was 112/204 (55%) and 92/204 (45%) were newly diagnosed. In the surveillance group, 80 were males (71%) and 32 were females (29%). The age range was 41–83 years, with a mean age of 62 years. Barrett's segment was described according to Prague criteria in 111/112 (99% compared to 89% in the previous audit). Thirty-one were short segment (i.e., <3 cm) and 81 were long segment (\geq 3 cm). Seattle protocol of biopsies was followed in 104/112 (93% compared with 70% previously) and chromoendoscopy (narrow-band imaging and 2% acetic acid spray) was performed in 66/112 (59% compared with 33% in previous audit). Inspection time was recorded in seven out of 112 (6% versus 2.5% in previous audit). Correct surveillance interval from last examination occurred in 103 (92% as opposed to 88% in previous audit).

Intestinal metaplasia was not confirmed in six patients. All were discharged from surveillance as this was the second endoscopy with negative intestinal metaplasia in compliance with the guidelines. Dysplasia was detected in 10 cases (nine low-grade and one high-grade). Seven low-grade dysplasias and one high-grade dysplasia were appropriately followed up and managed. A lesion within the Barrett's was seen in two cases. Both had distance from incisors recorded and targeted biopsies taken, but no

Paris classification or position was described according to the clock face.

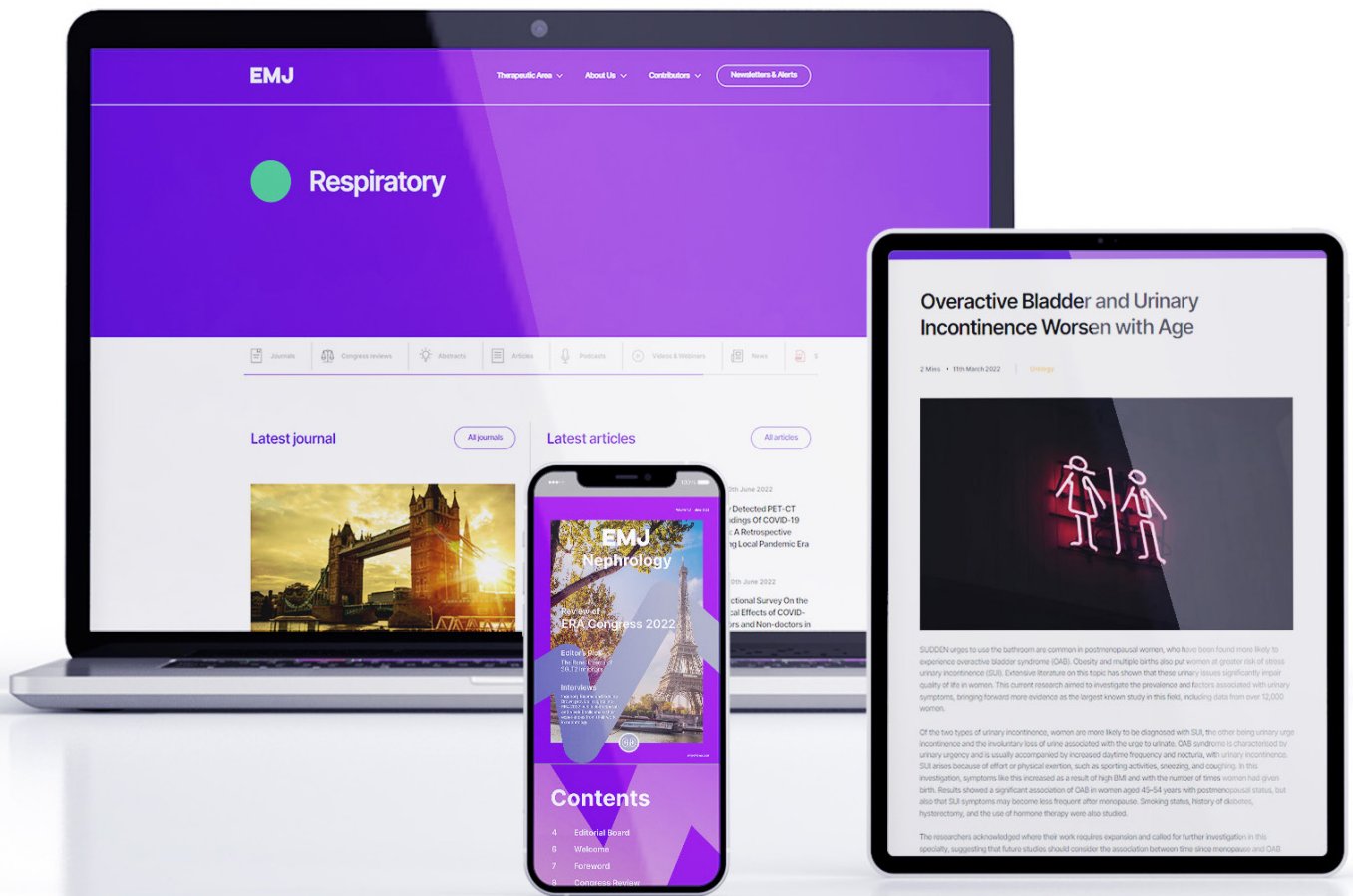
There was also a discrepancy in the length of Barrett measured between the initial and follow-up endoscopies in 40/112 cases (35%), but a significant difference affecting the surveillance interval was observed in seven cases only (6%).

CONCLUSION

Despite significant improvements from the previous audit, namely the use of Seattle protocol and chromoendoscopy, dedicated lists have not achieved >90% in all parameters that was intended. There is still more that needs to be done to optimise surveillance in relation to recording the BO inspection time, accurate measurement of the BO length, and lesion description. The authors introduced mandatory fields in the endoscopy reporting that would be triggered once BO surveillance has been chosen, to improve the above with further re-audit. ●

References

1. Fitzgerald RC et al. BSG guidelines on the diagnosis and management of Barrett's oesophagus. *Gut*. 2013;63(1):7-42.
2. Beg et al. Quality standards in upper gastrointestinal endoscopy: a position statement of the BSG and Association of Upper Gastrointestinal Surgeons. *Gut*. 2017;66(11):1886-99.
3. Bisschops R et al. Performance measures for upper gastrointestinal endoscopy: a European Society of Gastrointestinal Endoscopy (ESGE) quality improvement initiative. *Endoscopy*. 2016;48(09):843-64.
4. Britton J et al. Dedicated service improves the accuracy of Barrett's oesophagus surveillance: a prospective comparative cohort study. *Frontline Gastroenterol*. 2019;10:128-34.
5. Parasa S et al. Educational intervention to improve quality of care in Barrett's oesophagus: the AQUIRE randomized controlled trial. *Gastrointestinal Endoscopy*. 2022;95:239-45.



Stay up to date with new advancements across European healthcare

Visit EMJ for our comprehensive collection of peer-reviewed research articles, latest interviews, and features across a range of therapeutic disciplines.

[Visit EMJ](#)

www.emjreviews.com

EMJ



Interview



Michael Farthing

United European Gastroenterology (UEG) Lifetime Achievement Awardee 2021; Honorary Professor, University College London Medical School; Former President, British Society of Gastroenterology (BSG), European Association of Gastroenterology, Endoscopy & Nutrition (EA-GEN), and UEG.

Citation: EMJ Gastroenterol. 2022; DOI/10.33590/emjgastroenterol/10179885. <https://doi.org/10.33590/emjgastroenterol/10179885>.

Q1 With your extensive experience in the field of gastroenterology and other associated disciplines, what initially sparked your interest in the field and what has motivated you to continue researching?

Well, I think it's a combination of things, as always. I think the most common reason why people select a particular career is, firstly, the inspirational figures that you come across that lead you towards it. That was certainly true for me. I had some very remarkable early role models. As a medical student, I was on the gastroenterology firm, and I managed to maintain that contact until I needed to make a life decision.

I was also really interested in the patients. In gastroenterology, we cover a wide spectrum of age. There are lots of young people, sadly, who have got, for instance, inflammatory bowel disease, and it was rather nice having that spectrum rather than purely dealing with one set of patients.

It was quite extraordinary. My wife and I had dinner with a man who's now very successful, a businessman who has created a major software package that works for remote reporting of radiology X-rays, and I met him when he was 14. I went to Great Ormond Street, where we used to transition young people

into the adult clinic at St Barts; I had an arrangement with the paediatricians. I will never, ever forget the day that I first met that young 14-year-old, and now, it must be 40 years later, I have had dinner with him and got the rest of his life story, having looked after him for 21 years.

Q2 As former President of both the UEG and BSG, what were the biggest challenges that you faced in these positions, and how did you overcome them?

Let me say at the outset that I've always enjoyed these sorts of jobs; I've seen them as a privilege, frankly. Although, they do take up quite a lot of time, and I work as a volunteer. I loved both. Both were in a state where they were ready to change, and I guess that's my professional life story. I've always been at the heart of change, in the changing of organisations.

At BSG, we had a very strong academic collection of clinicians and researchers, but needed to do something about our administration. I was able to hire a professional chief executive who ran the business for us in a much stronger way. This gave us continuity; because presidents change, secretaries change, and you need consistency.

You need a continuum in a strong administration.

Then of course, there's UEG. The joke I often say is that people talk about the accounts being presented on the back of an envelope, and I literally did go to a meeting in the late 1990s where the accounts were presented by the treasurer on the back of an envelope. Again, it was a question of professionalising the administration. Obviously, there was a need to build the clinical and research side, but that's what we do, that's our job. The thing that I think we all started to focus on was the need to professionalise administration. We took the organisation from back when I think it was actually run part-time in a travel agency in Barcelona, and created a major centre in Vienna. This was what really strengthened the core of the organisation and allowed us to function with a much stronger financial base, and a stronger organisational base.

Q3 You described attending this year's UEG Week to collect your award as 'unmissable'. Do you think that the virtual design of congresses over the last few years should continue, or are there benefits to meeting in person that hybrid congresses cannot offer? If so, what are these benefits?

To be absolutely honest, the reason I went to Vienna this time was because, at this stage, we are all starved of interpersonal contact. I've known that team for years and years. I know the senior leaders now, and it was a complete joy to go and meet them, to see them all in person, to go out for dinner, and to have a bit of a laugh. This was really important to me.

But I remember back when I was Chairman of the Scientific Committee of UEG, and then the President, constantly asking the question of our council: how long are we going to go on having conferences with more than 12,000

"This gave us continuity; because presidents change, secretaries change, and you need consistency. You need a continuum in a strong administration."

people on an annual basis? How long are we still going to be doing that? Partly because of the costs of running it, that's just one thing. But also flying people in from all over the world; It's becoming increasingly scrutinised and yes, it's probably not a great thing to do. That being said, everybody agrees that there are times when that person-to-person, face-to-face interaction is absolutely critical, particularly when you're thinking about future strategy and future developments.

If young people grow up in a situation where they only see UEG online, then they will have missed out. They will have missed out on all of the wonderful experiences that I've had over, now, more than 30 years with UEG, or UEGF as it was before that, and all of the friends I've made. So I think there's a place for both, and we've got to find a way of doing that. We've got to find a way of allowing people to dip in and out as they choose. I think that is the future.

Q4 What do you see as the highlight of your professional career?

Being recognised in this way, and to be given a Lifetime Achievement Award by one of the most influential organisations in gastroenterology in the world, is a huge honour. That has to be a highlight.

I've had some research highlights; I've done often quite simple studies that

seem to have had quite a lot of impact. I mentioned one of these at UEG Week, which was a very simple study for travellers' diarrhoea. One of my main academic interests has been in intestinal infection. We did a study which showed that a single tablet of an antibiotic could reduce the severity, and the duration, of travellers' diarrhoea by about 50%. Everybody is worried about antibiotic resistance, and the widespread use of antibiotics. But I can tell you, if you're about to go up that morning and give a lecture on stage; you're in a tropical country somewhere, and you can feel the gurgling going on, knowing you're going to be in trouble up on that stage; to drop one pill, and be pretty much reassured that you're going to be okay, that's huge. I think all my colleagues then went on and used this, and it was a great study but a very simple one; not high science. I knew it would work because I had done it on myself. I did the "n=1" study a number of times, and knew that it would work. When we did the formal study, it then certainly did work.

One of my more personal research highlights is that I, and a research fellow of mine, went to set up a research project in Zambia. This was in Lusaka, and he is still there. Some 25 years later, he married a local Zambian paediatrician, has kids out there, and he's still running the centre that we established on a major Wellcome Trust grant many years ago. This was all about building capacity; it wasn't about going and doing a smash-and-grab, a bit of research, taking the data, and running off. It was about embedding what we were doing, and training other people. I take very little credit for this, because he is the person that's done it. But it's a great tribute really, to think that one was able to be part of that, at a stage in one's career, and that there is still something to see.

Q5 You have served lasting terms as an educator in Glasgow, Sussex, and London, amongst other locations. Where do you believe you gained the most valuable experience to make it to where you are today?

I think I would say two places.

One was a very small, impoverished mission hospital in South India, where I went as a medical student. It opened my eyes to the fact that not everybody lives the way that I lived in southwest London, where I was brought up. It was going to India, seeing a completely different world, and getting to really engage with the care of patients. I was working with a Scottish missionary paediatrician, who taught me a lot about childhood illnesses, including childhood diarrhoea and malnutrition. I think that had a major influence on what I eventually chose as my research area for the rest of my academic career. I went back to India, and also repeatedly sub-Saharan Africa and Central America, but I've worked mainly in the south of England throughout my academic career. So that was hugely influential, and gave me a curious sort of confidence. Although I was only a medical student at the time, and had very little clinical experience, I realised that I was going to be able to do the job. It was fantastic.

Maybe the other was when I did some research training in this country. I did my doctorate with a very distinguished physician. He was a great researcher, Sir Anthony Dawson. But I think I learnt my best science in Boston. I went to do a postdoctoral in Boston immediately after my doctorate. I worked with a guy called Jerry Keusch, who was an infectious disease physician. I moved right out of gastroenterology for two years, and immersed myself in what then was called geographic medicine. This was effectively tropical resource, poorer country-type medicine in the southern hemisphere. I learnt a lot there; I learnt a lot of good laboratory science, got some quite good publications, and I gained

a personal friend, which I've kept. He's 10 years older than me, but we're great pals. We see each other a lot, and he was hugely influential in the way in which the infectious diseases side of my career developed; he gave me lots of opportunities.

Q6 What do you believe to be the current gaps in literature within the specialty of gastroenterology?

I'm very much committed to the microbial world. Firstly, I am interested in the continuing impact of intestinal infection. I don't think this is traditional



gastroenterology, and I it's now under-represented; there aren't that many people working with pathogenic organisms who would call themselves a gastroenterologist. So, I probably personally would like to see a bit more of that.

I know there's plenty of it already, but the whole question of our relationship with our internal microbiome, and with the intestinal microbiota, is massive. There are times when I read something and think "This is going too far", or "This is being used to explain everything that goes wrong in the human body". I frankly can't believe that.

I would like to see a new wave of research on the microflora, which perhaps is just a bit more critical: analysing not just whether it has an effect, but what the size of this effect is. We've established a very interesting link with obesity. There was a wonderful study, now probably 15–18 years ago, which showed that you could transfer the microbiota from a genetically obese mouse, put this into other ordinary mice, and they would become obese. I think that's fascinating stuff. How important is that really for humans? I think it is important, but I don't always understand the size of the effect, and that's a very difficult question to answer. But it's a very important question.

It's like drugs. I worked for years in irritable bowel syndrome, as one of my side interests, which also has an infectious disease story to it. But there were lots of drugs that came out during the 90s and the early 2000s, drugs that were going to really solve irritable bowel disease, but, they didn't. The reason they didn't was because, although there were some very well-run clinical trials with new compounds, they were very large trials. Therefore, the larger the trial, the easier it was to get a significant difference. So, they got significant differences between the placebo and the treatment, but the size of the effect was sometimes no more than 5, 8, or

"Being recognised in this way, and to be given a Lifetime Achievement Award by one of the most influential organisations in gastroenterology in the world, is a huge honour."

10 percent. I would argue that it's very difficult for an ordinary patient to be able to tell whether they are 10 percent better or not. It's a huge market. And if you can sell a new compound based on a positive significant result in a clinical trial, that's usually enough, and the regulator lets it through. They don't always ask the question: is anybody going to notice any difference when they are taking this?

Q7 Where do you see the focal points for research lying in the near future, and are there any notable innovative topics on the horizon?

Well, I think inevitably the increasing role of artificial intelligence and large-scale computers. I've always been a watcher of industrial revolutions, and I think we're probably in the 6th or the 7th now: that's the digital revolution. I'm told we are still only halfway through this revolution's normal cycle, and I think there's potential to upscale our computing capacity when quantum computers arrive. We will see some massive changes.

I was having a discussion with an ex-patient of mine, who's now involved in artificial intelligence in terms of reporting X-rays. This patient said to me that there won't be any radiologists in 10 years because machines are going to be able to read across an X-ray, pick up digital signals, endlessly compute these, turn them into 3D images, and then give

you the diagnosis. Human eyes, I think, eventually will become significantly less able to deliver what a machine can do in terms of reading digital X-rays.

The digital world is really going to take shape; we've now got microscopes down in endoscopes so that you can see individual cells of the mucosa. These sorts of machines will distinguish between healthy cells and pre-cancer cells. I think this sort of technology is going to be driving surgical endoscopy and intestinal surgery. We will be using Level 3 and Level 4 robots to do a lot of our procedures. I've seen that coming in, and again, that's going to be driven through computer technology.

Q8 Speaking now after your illustrious career, what advice would you give to a younger self setting out on their journey in research science?

I think it's actually much more difficult now than it was when I was at that stage. The rate of change in careers, and the way that career pathways are going to change over the next 10 or 20 years, is probably ten times the speed that they changed over the same period during my experience as a student, and as a young doctor. It's about spotting the future, and seeing where the developments are going to be.

I was talking to the same ex-patient of mine, who has a daughter wanting to

study medicine. He said to my wife, who is a radiologist, "I'd love you to meet my daughter, and I would love you to inspire her to continue, but for goodness' sake don't tell her to be a radiologist!" He is genuinely worried that this career is going to look very different. There will be radiologists, of course there will, but their jobs will be very different.

You've really got to spot where the opportunities are going to be. For instance, when I was a young doctor, all cardiac surgeons were spending most of their time doing coronary artery bypass grafts, vein grafts (now a rare operation) with most done by interventional cardiologists putting in stents as a standard. That has changed in 30 years. So, I think it's really important to look at the horizon, but follow your passion. You've got to follow something which is really going to sustain you, because training as a doctor is not just for Christmas: it's for life. You've got to be able to try and see that horizon for yourself.

The other final thing is, ultimately, we're going to have to become much more flexible as professionals. We've got to be happy to change. I changed my career in a way: I was a full-time clinician academic, then an academic leader manager. Now that I'm doing some very different things, the trick is to look at the horizon, but also to teach yourself how to be flexible and re-train as the future changes ahead of you.

Medullary Carcinoma of the Pancreas: Report of a Rare Pancreatic Malignancy and Review of Literature



Editor's Pick

Medullary carcinoma of the pancreas is an extremely rare subtype of pancreatic adenocarcinoma. Due to how rare this condition is, there are currently no global guidelines for its treatment and management. This report and review article is essential, and adds to the current literature. It is necessary for clinicians to combine their knowledge and experience in treating patients with medullary carcinoma of the pancreas, as this may have a positive effect on patient outcomes.

Sorin T. Barbu

Professor of Surgery, "Iuliu Hațieganu" University of Medicine and Pharmacy, Cluj-Napoca, Romania

Authors:	*Melissa Kyriakos Saad, ¹ Evangelia Triantafyllou, ¹ Domenico Papaleo, ¹ Virginie Cahn, ² Elias Saikaly, ³ Yann Martin Proske ¹
	1. Department of Visceral Surgery, Sud Francilien Hospital, University Paris-Sud XI, France 2. Department of Pathology, Sud Francilien Hospital, University Paris-Sud XI, France 3. Department of General Surgery, St. George Hospital University Medical Center, Beirut, Lebanon *Correspondence to melissa.kyriakossaad@gmail.com
Disclosure:	The authors have declared no conflicts of interest.
Received:	26.06.21
Accepted:	13.01.22
Keywords:	Medullary carcinoma, pancreas, rare malignancy.
Citation:	EMJ Gastroenterol. 2022; DOI/10.33590/emjgastroenterol/21-00140.

Abstract

Medullary carcinoma of the pancreas is an extremely rare malignant tumour. To the best of the authors' knowledge, only 26 cases have been reported in the medical literature. A case of medullary carcinoma of the pancreas treated surgically by distal splenopancreatectomy is reported here.

Key Points

1. An extremely rare cancer, medullary carcinoma of the pancreas has, to the best of the authors' knowledge, only been reported 26 times and has been classified by the World Health Organization (WHO) as a subtype of pancreatic ductal carcinoma.

2. A literature review of the previous 26 cases indicated that the wild-type KRAS gene was found in 15 cases and six other cases had mutated KRAS, suggesting that this is an identifiable inherited cancer syndrome, where the identification of medullary carcinoma of the pancreas is essential.

3. The authors believe that, due to its rarity, an international database on treatment for patients with medullary carcinoma of the pancreas would be beneficial to patients.

INTRODUCTION

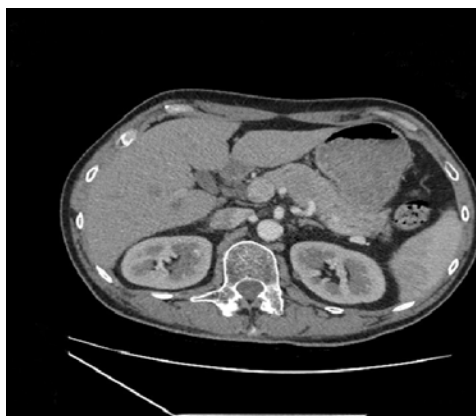An extremely rare subtype of pancreatic adenocarcinoma that has recently been described is medullary carcinoma of the pancreas. The first reported case of this type of tumour was by Goggins et al.¹ in 1998 and, since then, only 25 other cases have been reported in the medical literature. Medullary carcinoma of the pancreas is currently classified by the World Health Organization (WHO) as a subtype of pancreatic ductal carcinoma.¹ However, medullary carcinoma differs from traditional pancreatic ductal carcinoma due to its special genetic profile, as it has been reported that approximately 69% of medullary carcinoma tumours have wild-type KRAS genes and 22% have microsatellite instability (MSI).² From a histological perspective, medullary carcinoma of the pancreas is described by the presence of highly pleomorphic cells with syncytial morphology, expansive tumour growth, and

necrosis.¹ Given its rarity, there are no universal guidelines for treatment and its management is extrapolated from the management of pancreatic ductal carcinoma. Here, a case of a 47-year-old male with medullary cancer in the body of their pancreas is presented.

CASE PRESENTATION

A 47-year-old male patient with no personal or family history of malignancy presented to the clinic for work-up of epigastric pain. On physical exam, a mild tenderness in the epigastric area was notable. Radiologic work-up with abdominal ultrasound showed enlarged lymph nodes on the coeliac trunk, and a CT scan of the abdomen and pelvis with intravenous contrast revealed a hypodense lesion in the body of the pancreas measuring 40×25 mm, with no evidence of vascular invasion (Figure 1). Magnetic resonance cholangiopancreatography showed a pancreatic

Figure 1: CT scan revealing a hypodense lesion in the of body of the patient's pancreas measuring 40×25 mm.



The lesion had no evidence of vascular invasion and there was no dilation of the pancreatic duct.

body lesion measuring 30×25 mm, with heterogeneous density and delayed contrast uptake (Figure 2). An endoscopic ultrasound revealed a well-defined mass in the pancreatic body measuring 35×21 mm, which was hypoechoic, non-infiltrative, and inhomogeneous with central enhancement.

Multiple biopsies were taken, and histopathology revealed a non-invasive intraductal tubular papillary neoplasm. A PET-CT scan was performed, and no distant metastases were identified (Figures 3 and 4). Afterwards, a laparoscopic distal splenopancreatectomy was performed. Histopathology showed a 4.0×3.8 cm mass in the body of the pancreas that was compatible with medullary carcinoma, with negative surgical margins and perineural and

perivascular invasion (Figure 5A). Microscopic examination showed a poorly differentiated carcinoma with limited gland formation, syncytial growth pattern, and stroma characterised by abundant tumour-infiltrating lymphocytes (Figures 5B and 5C). The borders of the tumour were well-defined in three-quarters of its periphery, where it was surrounded by a fibrinous pseudo-capsule (Figure 5D), and in the other quarter, there was an aspect of infiltrating stroma.

Immunohistochemistry for the neuroendocrine markers, cytokeratin-7, caudal-related homeobox transcription factor 2, B cell lymphoma 10, and cytokeratin-20 were negative. Tests for mutations of the *EGFR* (exons 18–21), *KRAS*

Figure 2: Magnetic resonance cholangiopancreatography showing a pancreatic body lesion measuring 30×25 mm, with heterogeneous density and delayed contrast uptake.

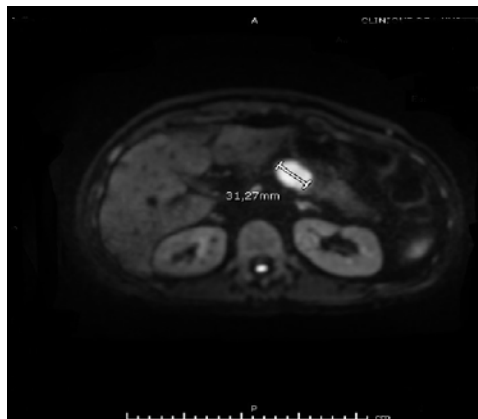


Figure 3: CT (left) and PET (right) scans of the patient's abdomen showing a hypermetabolic lesion of pancreatic body (arrow) with no distant metastasis.

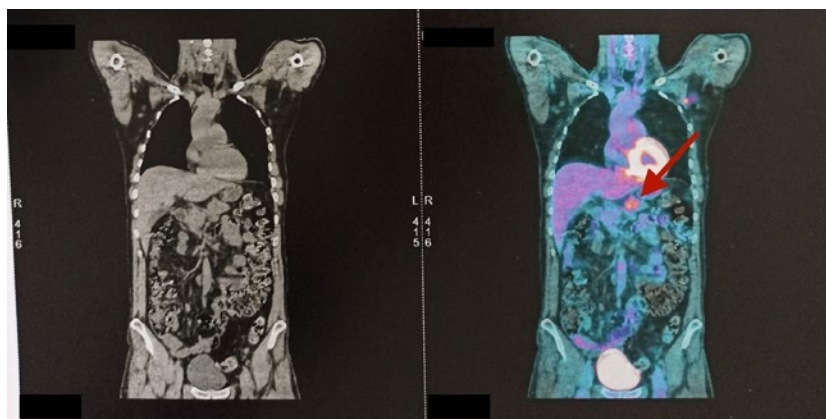


Figure 4: CT (left) and PET (right) scans of the patient's pancreas showing a hypermetabolic lesion of the pancreatic body with no distant metastasis.

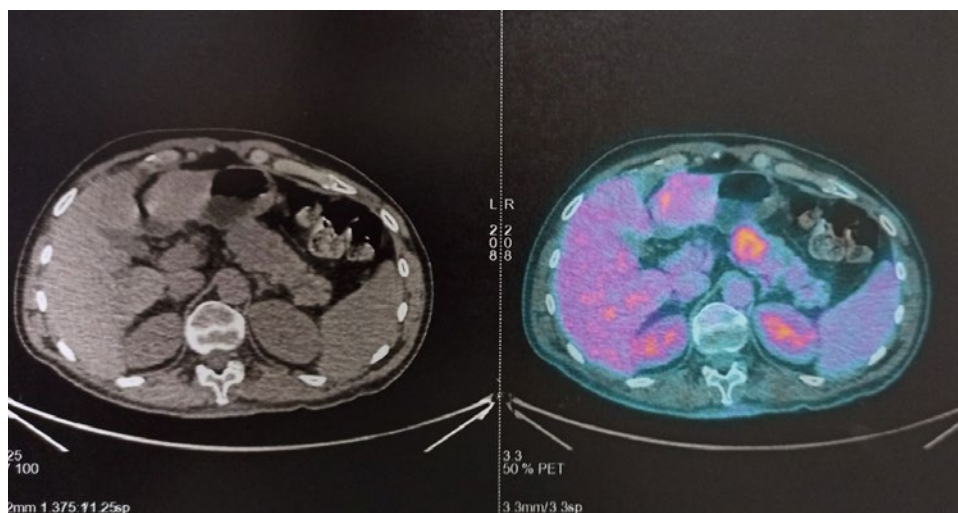
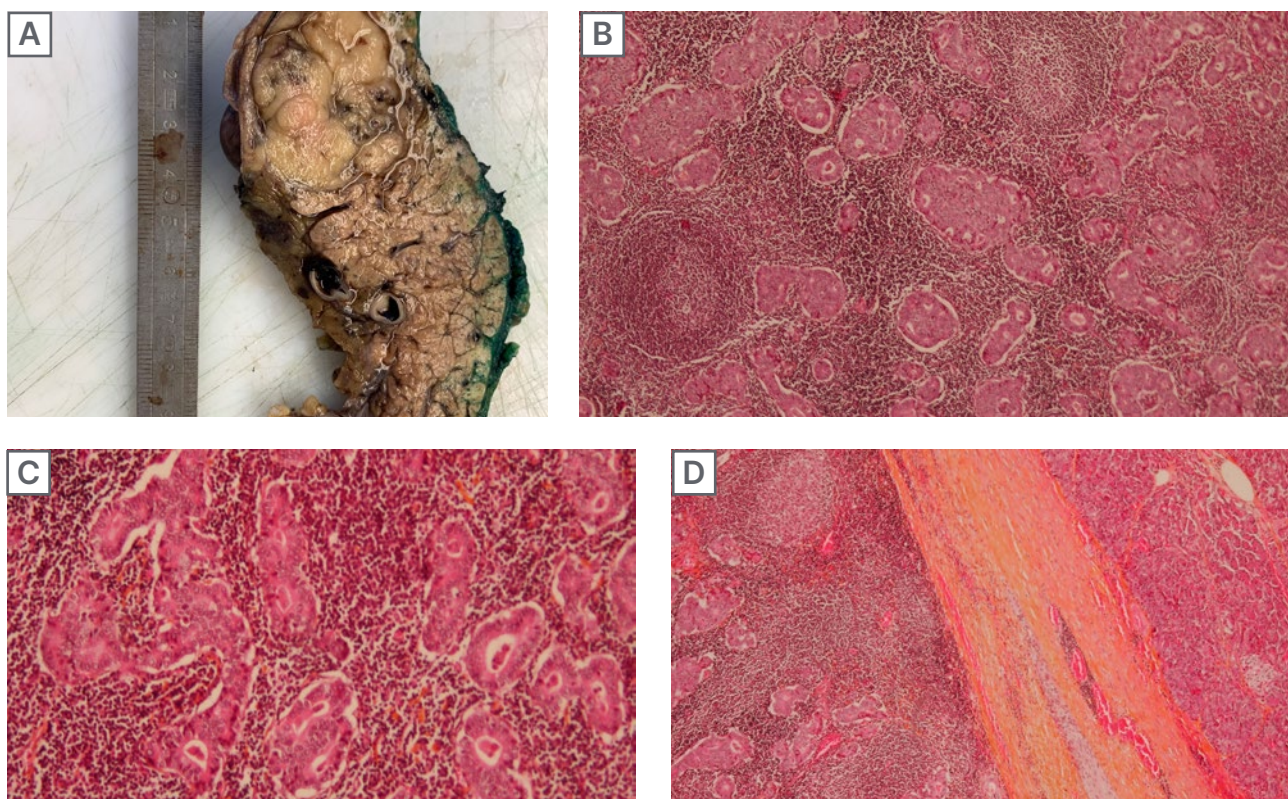


Figure 5: Histopathology performed after laparoscopic distal splenopancreatectomy.



A) Macroscopic image of the tumour after formalin fixation, measuring 4.0×3.8 cm. B) Microscopic image showing the syncytial growth and formation of glandular masses, which represent the tumour proliferation. The stroma has a basophilic appearance characterised by abundant lymphocyte proliferation forming lymphocyte follicles with a clear centre (arrows). C) Microscopic image showing the syncytial growth and formation of glandular masses, which represent the tumour proliferation. D) A fibrinous pseudo-capsule, covering most of the circumference of the tumour.

(exons 2 and 34), *NRAS* (exons 2, 3, and 4), *BRAF* (exons 11 and 15), *KIT* (exons 8, 9, 11, 13, 14, 17, and 18), and *PI3KCA* (exons 10 and 21) genes were all negative. Henceforth, the tumour was considered to have a genetic profile of wild-type *KRAS*. No MSI was identified (phenotype: microsatellite stability [MSS]), which does not favour a diagnosis of Lynch syndrome. *In situ* hybridisation for Epstein–Barr virus peptide nucleic acid was also negative. Cytokeratin-19 was positive, and antigen Ki-67 proliferation was 30–40% in favour of an aggressive neoplasm. Moreover, an additional molecular study in search of a hypermutated tumour in the *POLE* gene profile was performed and came back as negative. After 12 weeks post-surgery, the patient started adjuvant chemotherapy with folinic acid plus fluorouracil plus irinotecan plus oxaliplatin and was disease-free up to 7 months post-surgery.

DISCUSSION

Medullary carcinoma of the pancreas is a recently described rare subtype of pancreatic adenocarcinoma with a special genetic profile.² Its true incidence, prognosis, and optimal treatment are yet to be determined, and its management is currently extrapolated from the management of pancreatic ductal carcinoma. However, medullary carcinoma of the pancreas

is genetically distinct from conventional ductal adenocarcinomas of the pancreas. In fact, Goggins et al.¹ found that 60% of patients with pancreatic medullary carcinoma had both MSI and a wild-type *KRAS* gene. These data are atypical for non-medullary ductal adenocarcinomas of the pancreas, which nearly universally harbour *KRAS* gene mutations and seldom, if ever, have MSI.^{1,3} Its diagnosis depends on histologic findings, and there are no specific imaging or tumour markers that could aid these diagnoses. Consequently, pathologists should differentiate between medullary carcinoma and the conventional ductal adenocarcinoma as this will highlight the possibility of an inherited cancer syndrome, such as hereditary non-polyposis colorectal cancer, which will translate directly into better genetic counselling.

To the best of the authors' knowledge, medullary carcinoma of the pancreas has been reported in 26 cases (Table 1). The mean age at diagnosis is 65 years, with 60% of patients being male and 40% being female, and 59% of these cases had a positive family history of cancer. However, regarding the anatomical location of the tumour, the case outlined here is the fourth reported case located in the body of the pancreas. Furthermore, despite the lack of information for all cases, it is worth mentioning that a personal history of colon cancer was reported in three cases.

Table 1: Characteristics of previously reported medullary carcinoma of the pancreas.

Author (year)	Gender/age (years)	Size (cm)	Location in pancreas	Family history	Personal history of CRC	Pre-op imaging	Pre-op metastases	Surgery	Tumour markers	MSI	KRAS mutation	LN's	Survivor (months/status)
Goggins et al. ¹ (1998)	M/71	5.0	N/A	Positive (kidney, lung)	Positive (x2)	N/A	No	Whipple	N/A	Positive	Wild	Positive	52/AWD
Goggins et al. ¹ (1998)	F/84	2.0	N/A	Positive (breast, lung)	Negative	N/A	No	Whipple	N/A	Positive	Wild	Positive	4/DOD
Goggins et al. ¹ (1998)	M/72	2.5	N/A	Positive (breast)	Negative	N/A	No	Whipple	N/A	Positive	Wild	Negative	16/AWD
Goggins et al. ¹ (1998)	M/65	7.0	N/A	Positive	N/A	N/A	No	N/A	N/A	Negative	G12R	Negative	13/DOD

Table 1 continued.

Goggins et al. ¹ (1998)	M/55	4.0	N/A	Positive	N/A	N/A	No	N/A	N/A	Negative	Wild	Positive	12/AWD
Goggins et al. ¹ (1998)	M/85	8.0	N/A	Positive	N/A	N/A	No	N/A	N/A	Negative	G12D	Negative	7/DOD
Wilentz et al. ² (2000)	M/72	N/A	N/A	Positive	N/A	N/A	N/A	N/A	N/A	Negative	CGT	N/A	0/DOD
Wilentz et al. ² (2000)	F/74	N/A	N/A	Unknown	N/A	N/A	N/A	N/A	N/A	Negative	Wild	N/A	8/DOD
Wilentz et al. ² (2000)	M/79	N/A	N/A	Positive	N/A	N/A	N/A	N/A	N/A	Negative	GAT	N/A	5/DOD
Wilentz et al. ² (2000)	F/53	N/A	N/A	Positive	N/A	N/A	N/A	N/A	N/A	Negative	Wild	N/A	45/DOD
Wilentz et al. ² (2000)	M/44	N/A	N/A	Unknown	N/A	N/A	N/A	N/A	N/A	Negative	Wild	N/A	11/DOD
Wilentz et al. ² (2000)	M/49	N/A	N/A	Unknown	N/A	N/A	N/A	N/A	N/A	Negative	Wild	N/A	15/DOD
Wilentz et al. ² (2000)	M/74	N/A	N/A	Positive	N/A	N/A	N/A	N/A	N/A	Negative	Wild	N/A	12/DOD
Wilentz et al. ² (2000)	F/74	N/A	N/A	Unknown	N/A	N/A	N/A	N/A	N/A	Negative	Wild	N/A	12/DOD
Wilentz et al. ² (2000)	M/34	N/A	N/A	Positive	N/A	N/A	N/A	N/A	N/A	Positive	Wild	N/A	13/AWD
Wilentz et al. ² (2000)	M/33	N/A	N/A	Negative	N/A	N/A	N/A	N/A	N/A	Negative	Wild	N/A	126/AWD
Wilentz et al. ² (2000)	F/67	N/A	N/A	Positive	N/A	N/A	N/A	N/A	N/A	Negative	TTT	N/A	15/DOD
Wilentz et al. ² (2000)	M/67	N/A	N/A	Positive	N/A	N/A	N/A	N/A	N/A	Negative	GAT	N/A	15/DOD
Wilentz et al. ² (2000)	F/66	N/A	N/A	Positive	N/A	N/A	N/A	N/A	N/A	Negative	Wild	N/A	7/DOD
Banville et al. ⁴ (2006)	M/63	11.0	Body and distal tail	Negative	Rectal adenocarcinoma, metachronous cecal adenocarcinoma (at 53 years)	CT: mass of distal body and tail involving stomach	Yes	DP, partial gastrectomy, splenectomy, small bowel resection	N/A	Positive	Not done	N/A	Unknown

Table 1 continued.

Cumplido Burón, Toral Peña (2011) ⁵	M/59	N/A	Body	Unknown	Negative	MRI: mass in body of pancreas, no vascular penetration	No	Whipple	EMA: positive CK-20, CEA, NET, S100, and CD45: negative	Not done	Wild	Positive	5/DOD
Krvavica et al. ⁶ (2012)	F/69	6.0	Tail	Positive (breast)	Negative	CT: two tumour nodules of left kidney and enlarged para-aortic LNs	Yes	DP with partial left nephrectomy, para-aortic LNs excision	N/A	Not done	Unknown	Positive	18/DOD
Laxton ⁷ (2017)	F/ middle age	N/A	Tail	Unknown	N/A	CT: hyper-enhancing mass in pancreatic tail and peripancreatic LNs	No	DP	N/A	Positive	Unknown	Positive	Unknown
Yago et al. ⁸ (2018)	F/73	2.2	Body	Positive (gastric, pancreatic)	Negative	US: cystic lesion of pancreas CT+EUS: no cyst but solid tumour in MPD of body and MPD dilatation	No	Whipple	CA 19-9, CEA, pancreatic Ca and Ag, DUPAN-2, Span-1: normal	Negative	G12V	Negative	29/AWD
Peña Anduya et al. ⁹ (2018)	F/80	N/A	Head	Unknown	Positive	CT: mass in pancreatic head and cecum	Yes	Total pancreatectomy, splenectomy, cholecystectomy, right hemicolectomy	N/A	Unknown	Unknown	Negative	Unknown
Kryklyva et al. ¹⁰ (2020)	F/60	7.0	Head	Negative	Negative	MRI+PET: pancreatic head mass	No	Whipple	N/A	Negative (POLE mutation)	Unknown	Negative	60/AWD
Case outlined in this report	M/47	3.5	Body	Negative	Negative	CT: 40×25 mm body of pancreas mass MRI: 30×25 cm tumour in body	No	DSP	CA 19-9: 19.6 U/mL CEA: 2.2 ng/mL	Negative	Wild	Negative	7/AWD

Ag: silver; AWD: alive without disease; Ca: calcium; CA 19-9: carbohydrate antigen 19-9; CD45: leukocyte common antigen; CEA: carcinoembryonic antigen; CK-20: cytokeratin-20; CRC: colorectal cancer; DOD: died of disease; DP: distal pancreatectomy; DSP: distal spleen pancreatectomy; DUPAN-2: duke pancreatic monoclonal antigen Type 2; EMA: epithelial membrane antigen; EUS: endoscopic ultrasound; F: female; LN: lymph node; M: male; MPD: main pancreatic duct; MSI: microsatellite instability; N/A: not available; NET: norepinephrine transporter; Pre-op: pre-operation; ref: reference; S100: S100 protein; Span-1: S-pancreas-1 antigen; US: ultrasound; Whipple: Whipple procedure.

Medullary carcinoma of the pancreas suggests two distinctive genetics: MSI and a wild-type *KRAS* gene. In the reported cases, six had MSI, 18 had MSS, two had no MSI testing done, and one was of unknown status; therefore, MSI was found in almost 22.22% of cases (six out of 26 cases), compared with 66.66% who had MSS. As for the *KRAS* gene, the literature showed a preservation of wild-type *KRAS* in 15 cases, while six had mutant *KRAS*, four were of unknown status, and in one case, no *KRAS* analysis was performed. The majority of cases of medullary carcinoma of the pancreas were with a wild-type *KRAS* (15 out of 26; 55.55%), and a *KRAS*-mutated gene was seen in six out of 26 cases (22.22%). In current oncology practice, where cancer genetics and the correlation between the genotype and phenotype of the cancer play a vital role, the identification of an inherited cancer syndrome is of the utmost importance. From here, the role of the pathologist in identifying medullary carcinoma of the pancreas is essential and should be considered as the cornerstone for

further investigations and genetic counselling. Furthermore, a high index of suspicion is necessary despite a negative diagnosis of malignancy on endoscopic ultrasound, so surgical consultation should be considered in these cases.

CONCLUSION

Medullary carcinoma of the pancreas is an exceptionally rare special subtype of pancreatic ductal carcinoma. The currently reported cases make it extremely difficult to elucidate the prognosis and optimal treatment for patients with medullary carcinoma of the pancreas. Finally, due to the rarity of this disease, combining the efforts of clinicians treating patients with medullary carcinoma of the pancreas through an international database would be of great benefit to patients.

References

- Goggins M et al. Pancreatic adenocarcinomas with DNA replication errors (RER+) are associated with wildtype K-ras and characteristic histopathology. Poor differentiation, a syncytial growth pattern, and pushing borders suggest RER+. *Am J Pathol.* 1998;152(6):1501-7.
- Wilentz RE et al. Genetic, immunohistochemical, and clinical features of medullary carcinoma of the pancreas. *Am J Pathol.* 2000;156(5):1641-51.
- Hruban RH et al. K-ras oncogene activation in adenocarcinoma of the human pancreas: a study of 82 carcinomas using a combination of mutant-enriched polymerase chain reaction analysis and allele-specific oligonucleotide hybridization. *Am J Pathol.* 1993;143(2):545-54.
- Banville N et al. Medullary carcinoma of the pancreas in a man with hereditary nonpolyposis colorectal cancer due to a mutation of the MSH2 mismatch repair gene. *Hum Pathol.* 2006;37(11):1498-502.
- Cumplido Burón JD, Toral Peña JC. The medullary carcinoma of the pancreas: a relative new entity. *Rev Esp Enferm Dig.* 2011;103(6):335-6.
- Krvavica A et al. Renal metastases of pancreatic medullary carcinoma: a case report. *Acta Clin Croat.* 2009;48(2):217.
- Laxton W, "Case 72: pancreatic ductal adenocarcinoma with medullary features," Zaheer A et al. (eds.), *Pancreatic Imaging* (2017) 1st edition, New York: Springer Publishing, pp.307-9.
- Yago A et al. Medullary carcinoma of the pancreas radiologically followed up as a cystic lesion for 9 years: a case report and review of the literature. *Surg Case Rep.* 2018;4(1):80.
- Anduaga Peña MF et al. The medullary carcinoma of the pancreas. *HPB (Oxford).* 2018;20(2):S549-50.
- Kryklyva V et al. Medullary pancreatic carcinoma due to somatic *POLE* mutation: a distinctive pancreatic carcinoma with marked long-term survival. *Pancreas.* 2020;49(7):999-1003. *Am J Respir Crit Care Med.* 2001;163(5):1256-76.


FOR REPRINT QUERIES PLEASE CONTACT: INFO@EMJREVIEWS.COM

Innovative Upper Gastrointestinal Stenting: Reborning the Blocked Path

Authors:

Abhijith Bale,¹ Irshad H. Ali,¹ Ajay Bale,² Vidyasagar Ramappa,³ *Umesh Jalihal²

1. Sapthagiri Institute of Medical Sciences and Research Centre, Bangalore, India
 2. Karnataka Gastro Center, Bangalore, India
 3. Columbia Asia Referral Hospital Yeshwanthpur, Bengaluru, India
- *Correspondence to drumeshj@yahoo.com



Disclosure:

The authors have declared no conflicts of interest.

Received:

24.10.21

Accepted:

16.03.22

Keywords:

Cervical oesophageal leak, congenital oesophageal stenosis, oesophageal diverticulum, post-corrosive antropyloric stricture, self-expanding metal stents.

Citation:

EMJ Gastroenterol. 2022; DOI/10.33590/emjgastroenterol/21-00227. <https://doi.org/10.33590/emjgastroenterol/21-00227>.

Abstract

Self-expanding metal stents (SEMS) have been established beyond doubt as an effective tool in the palliative management of malignant gastrointestinal tract strictures. The advent of fully covered retrievable SEMS has allowed its use in benign oesophageal strictures and gastric outlet obstruction, which are traditionally treated with balloon or bougie dilation. Although balloon and bougie dilations are effective, strictures may be refractory, requiring repeated sessions of dilation or complex surgeries. Endoluminal stenting spares the patient from complex surgical procedures and their associated complications. Here, the authors present four cases wherein fully covered SEMS were used as an effective therapy for the restoration of the gastrointestinal lumen in non-malignant conditions.

Key Points

1. The use of endoluminal stents means that healthcare professionals can treat patients with certain conditions such as anastomotic site leaks, strictures, and fistulas without complex surgical intervention.
2. The authors discuss the use of stents in four patients who presented with different benign conditions with failed prior endotherapy.
3. While there are advantages and disadvantages to specific stents, and they should be chosen depending on the condition, the clinical experience with self-expanding metal stent is better than self-expanding plastic stents and biodegradable stents.

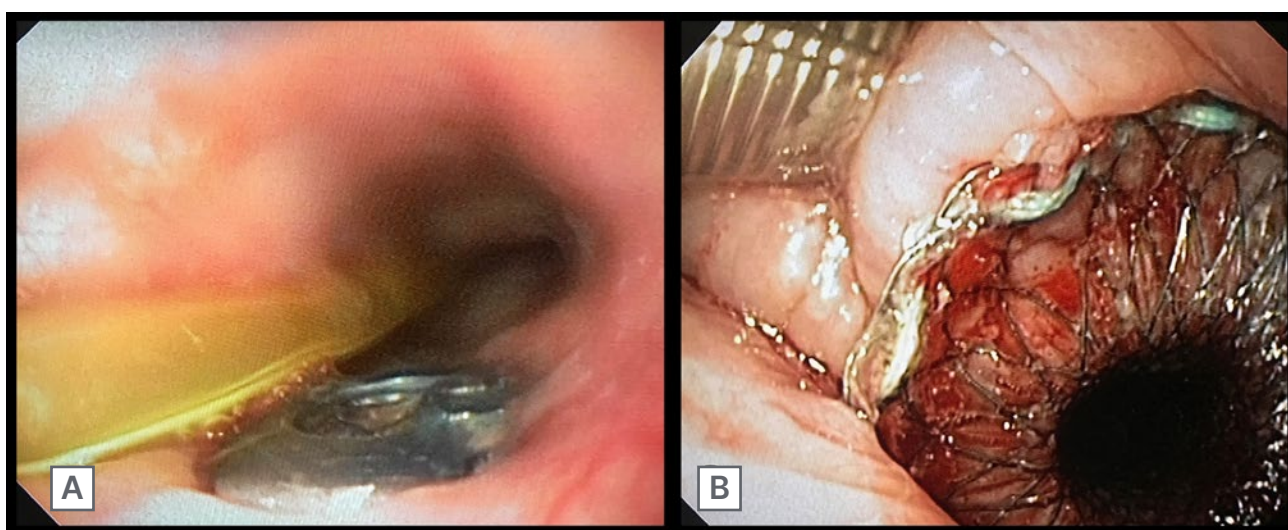
INTRODUCTION

Self-expanding metal stents (SEMS) have been established beyond doubt as an effective tool in the palliative management of malignant gastrointestinal (GI) tract strictures. Partially covered and uncovered stents are being frequently used in the case of oesophageal, gastric, and colonic malignancies, allowing for the endoscopic restoration of GI tract patency. The advent of fully covered retrievable SEMS has allowed its use in benign oesophageal strictures and gastric outlet obstruction (GOO), which are traditionally treated with balloon or bougie dilation. Although these dilations are effective, strictures may be refractory, requiring repeated dilations or complex surgeries such as gastric pull up, colonic transposition, and gastrojejunostomy. Endoluminal stenting spares the patient from complex surgical procedures and their associated complications, including anastomotic site leaks, strictures, and fistulas. Here, the authors present four unusual cases encountered in their clinical practice wherein fully covered SEMS were used as an effective therapy for the restoration of the GI lumen in non-malignant conditions.

CASE 1

A 70-year-old male presented to the hospital with a cervical fracture following a road traffic accident. The patient was subjected to cervical decompression and fusion. Nearly 2 weeks later, the patient developed an upper oesophageal leak that was secondary to the implant eroding through the posterior oesophageal wall (Figure 1A). The attempted closure of the leak with endoscopic clip placement and surgical correction, which involved a musculoskeletal flap placement and suturing of the oesophageal defect, failed. The patient was placed in an intensive care unit and underwent endotracheal intubation. Feeding was continued through a percutaneous endoscopic gastrostomy tube. A 10 cm long cervical SEMS (Niti-S™ Stent, Taewoong Medical, Seoul, South Korea) was placed across the defect under endoscopic and fluoroscopic guidance (Figure 1B). This SEMS had a 7 mm long proximal flange and a lumen diameter of 18 mm. The stent remained *in situ* for 8 weeks. Post-SEMS removal endoscopy and barium swallow showed no evidence of a leak; the patient was then started on oral feeds. The patient eventually ambulated and they were discharged without recurrence of leak.

Figure 1: A 70-year-old male with cervical spine implant eroding through the posterior oesophageal wall (A). Cervical oesophageal SEMS in situ (B)

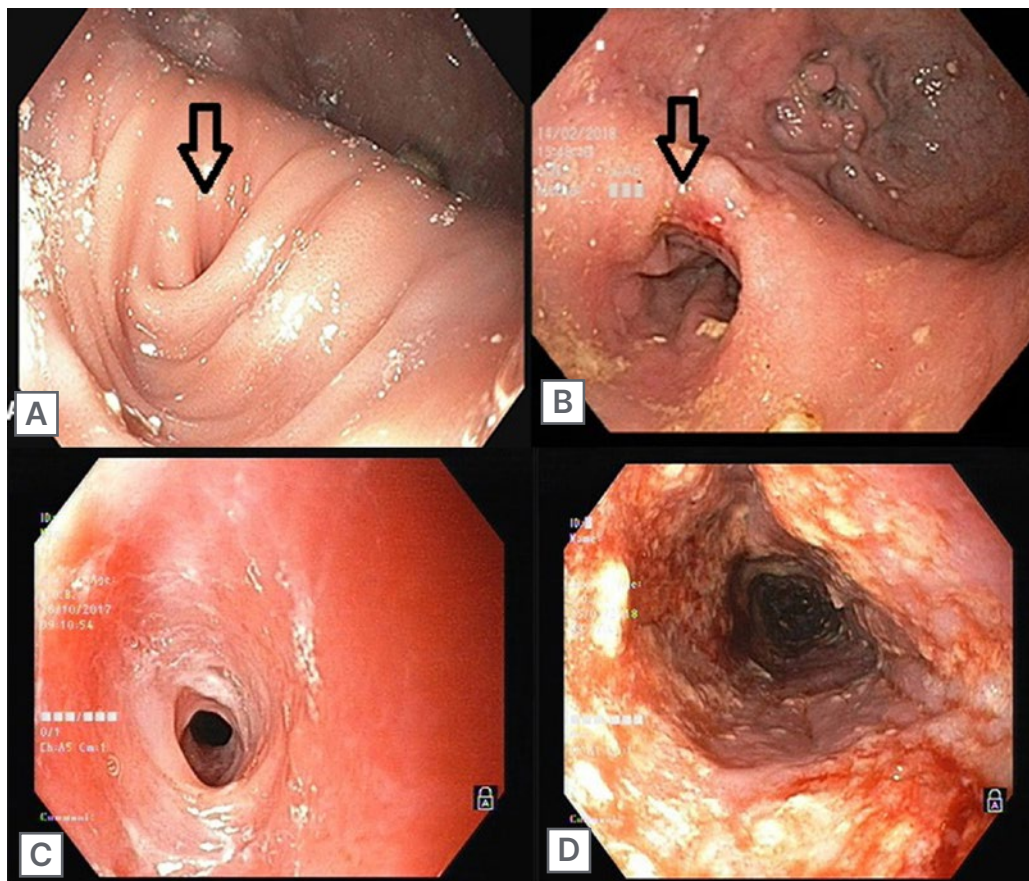


CASE 2

A 70-year-old male presented with recurrent episodes of dysphagia and regurgitation. An endoscopic evaluation revealed an epiphrenic diverticulum at the lower oesophagus (Figure 2A) and manometric evaluation revealed an underlying Type II achalasia cardia. Surgical correction with Heller's myotomy and diverticulectomy failed to provide symptomatic relief. The patient presented with recurrent episodes of acute onset dysphagia; endoscopy would reveal food bolus impaction in the diverticulum, prompting endoscopic foreign body removal. On barium swallow, barium would initially fill up the diverticulum, causing compression, kinking, and the narrowing of the infra-diverticular oesophagus. Repeated balloon dilation of the infra-diverticular oesophageal segment did not benefit the patient. Repeat surgery was deemed too difficult because of

significant comorbidities and the failure of the index surgery to provide symptomatic relief. This prompted an innovative endoscopic intervention: a padlock clip was applied at the apex of the diverticulum, shrinking it significantly, and a 10 cm long, fully covered anti-migratory oesophageal stent (Niti-S Beta™ Stent, Taewoong Medical, Seoul, South Korea) was placed, covering the diverticular region. Repeat barium studies showed a smooth flow of barium through the oesophagus into the stomach. Although stent removal was planned to take place after 3 months, the stent had to be removed prematurely at 2 months after it migrated into the stomach. Post-stent removal (Figure 2B), the patient remained asymptomatic without any further episodes of food bolus impaction and gained 10 kg of weight.

Figure 2: A 70-year-old male with an epiphrenic diverticulum with infradiverticular esophageal stricture (A) and post-stent removal (B); and a 45-year-old female with a congenital oesophageal stricture (C) and post-stent removal (D).



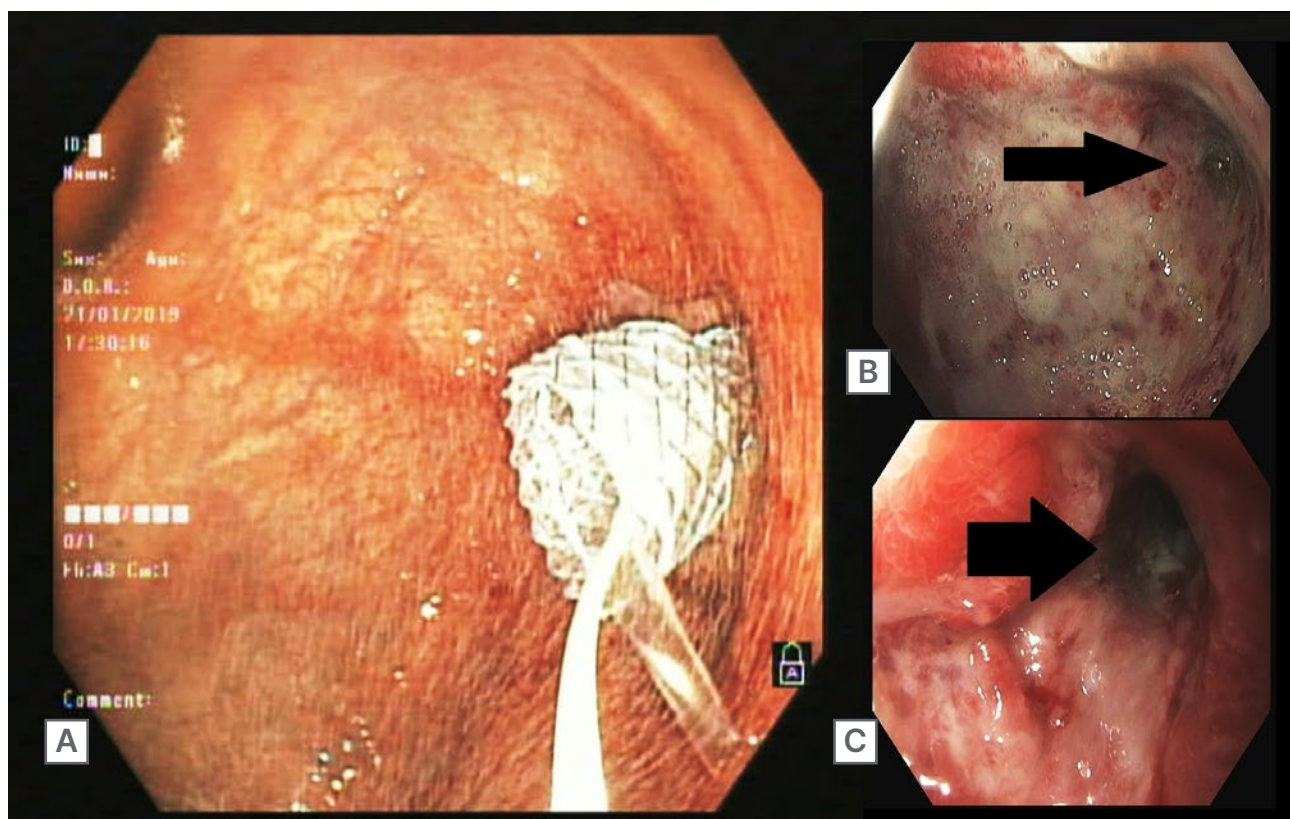
CASE 3

A 45-year-old female presented with a 3 month history of dysphagia for solids. Endoscopy showed a long segment stricture involving the mid-oesophagus with fragile mucosa (Figure 2C). The patient denied any history of caustic upper GI injury or radiation. Oesophageal biopsies were done to rule out eosinophilic oesophagitis. Multiple sessions of bougie dilations failed to provide results. A diagnosis of congenital oesophageal stenosis (COS) was considered, and a 10 cm long, fully covered SEMS (SX-ELLA Stent, ELLA-CS, Hradec Králové, Czechia) was placed across the stricture. The stent remained *in situ* for 2 months and, post-removal, the patient was relieved of dysphagia. Repeat endoscopy showed a restored lumen diameter, allowing for the free passage of an adult endoscope (Figure 2D). No recurrence of symptoms have been reported over 3 years of follow-up.

CASE 4

A 56-year-old male with no comorbid illness presented with a history of accidental ingestion of an unidentified volume of unlabelled floor cleaning agent. On admission, their main complaints were retrosternal and upper abdominal burning. Chest and abdomen X-rays showed no evidence of perforation. An upper GI endoscopy was performed the next day, which showed Zargar Grade IIA and IIB injuries to the oesophagus and the stomach, respectively. The patient was treated initially with intravenous fluids and proton pump inhibitors. Oral feeds were gradually introduced, after which the patient was discharged on oral proton pump inhibitor therapy. The patient presented again 25 days later with complaints of recurrent vomiting and post-prandial upper abdominal distention. Upper GI endoscopy showed scarring of gastric mucosa in the fundus and the body, with a stenosed, eccentrically located pyloric opening (Figure 3B). The antropyloric stricture was subjected to endoscopic balloon dilation

Figure 3: A 56-year-old male with corrosive gastric outlet obstruction (B), SEMS *in situ* (A), Post- SEMS removal (C)



(CRE™ Balloon 12–13.5–15 mm, Boston Scientific, Marlborough, Massachusetts, USA), which was repeated three times in the following 3 months to prevent recurrence of the stricture. As the stricture was refractory to multiple sessions of balloon dilation, the option of surgery versus SEMS placement was discussed. Consequently, a 10 cm long, fully covered SEMS (Niti-S™ Stent, Taewoong Medical, Seoul, South Korea) was placed across the stricture (Figure 3A). The patient remained asymptomatic and gained approximately 10 kg of weight post-procedure. The pyloric SEMS was removed endoscopically 3 months later (Figure 3C). At a 24-month follow-up, no stricture recurrence was observed.

DISCUSSION

Since the introduction of SEMS in the 1990s for the palliation of oesophageal malignancies, stents have evolved in design and composition, allowing for their use in treating novel indications. Several types of stents are available on the market; nonetheless, careful selection of an appropriate type of stent is vital for achieving desired results.

Self-Expanding Metal Stents

SEMS can be uncovered, partially covered, or fully covered. Uncovered (or bare-metal) stents were widely used in the palliation of inoperable oesophageal malignancies. Although effective, these had the disadvantage of dysphagia recurrence due to tumour ingrowth, which was seen in up to 36% of the patients that required repeat stenting.¹ The issue of tumour ingrowth was addressed by using fully covered metal stents, which had a polymer coating around the metal frame that prevented ingrowth. However, fully covered stents presented a unique problem: stent migration.² Currently, partially covered stents, which are covered in the middle and have uncovered portions at both the ends, are used to balance the risk of migration and tumour overgrowth. In cases of benign strictures, only fully covered SEMS can be used as tissue ingrowth makes stent removal more difficult. The risk of migration can be addressed by using stents with flared ends and fixing stents using haemoclips,³ over-the-scope clips,⁴ or endoscopic suturing.⁵

SEMS have also been modified according to the intended location of their use. In cases where the lesions are in proximity to the upper oesophageal sphincter, foreign body sensation and injury preclude the use of regular SEMS. A special modification of the SEMS with a short and narrow funnel in the proximal end has allowed for its use in lesions of the cervical oesophagus.⁶ In cases involving the oesophagogastric junction, the placement of SEMS across the lower oesophageal sphincter complex has been associated with severe gastro-oesophageal reflux; however, SEMS with anti-reflux valves have been shown to reduce reflux symptoms.⁷

Self-Expanding Plastic and Biodegradable Stents

Although fully covered SEMS have made the non-surgical treatment of refractory benign strictures possible, they are not devoid of drawbacks. Complications such as the recurrence of the stricture, hyperplastic tissue reaction at the ends, perforation at the edges, and migration present difficulties.⁸ Plastic stents were introduced, which were proposed to have several advantages including low cost, minimal tissue reaction, and easy placement and removal. Several studies have shown good results with self-expanding plastic stents (SEPS).^{9,10} Biodegradable stents (BDS), which are made of biodegradable material that gradually disintegrates over 11–12 weeks post-stent placement, are a newer addition to the armamentarium. The radial force of these stents is maintained over 5–6 weeks, avoiding the need for reinterventions for stent removal.¹¹

Analysis

A meta analysis by Fuccio et al.¹² compared the results of 18 studies that used SEPS, SEMS, and BDS in treating refractory benign oesophageal strictures. Overall, the pooled clinical success rate was 40.5%. The use of SEPS and SEMS did not result in significantly higher success rates than with BDS (46.2% versus 40.1% versus 32.9%, respectively). The migration rate for SEPS and SEMS were reported as not being significantly higher than for BDS (33.3% versus 31.5% versus 15.3%, respectively). Another prospective, multicentre study¹³ comparing the three different stent types concluded that BDS or a fully covered SEMS may lead to long-term relief of dysphagia in 30% and 40% of

patients, respectively. The use of SEPS was the least preferable option due to frequent stent migrations and the need for reinterventions.

Although each stent category has its advantages and drawbacks, experience with fully covered SEMS is generally better than with SEPS and BDS. Moreover, the design of stents and our experience with novel stents may improve with time. However, SEMS placement, although capable of marvellous clinical outcomes, is not without complications. These complications can be early, occurring within 4 weeks of stent placement, or late, occurring after 4 weeks.¹⁴ Early complications include foreign body sensation, pain, gastro-oesophageal reflux, migration, bleeding, and perforation. Late complications include stent migration, stent block due to food impaction, tumour ingrowth, and tumour overgrowth.

In a retrospective analysis by Na et al.,¹⁵ complications related to stent placement were found in nearly 40.3% of patients. The complication rate was lower, at 32.6% in cases using the latest generation stents. Chest pain following stent placement was seen in 6.7% of patients, but the majority responded to analgesic therapy. Few patients required stent removal due to intractable pain that did not respond to analgesics. The pain was more common in stents made of stainless steel rather than those made of nitinol, and in patients who had undergone radiation therapy before stent placement. Stent migration was seen in 10.9% of the patients and was managed either by stent repositioning or stent replacement. Bleeding after stenting was seen in 1.9% of patients; in most, the bleeding stopped spontaneously within 48 hours. Only one patient required adrenaline injection and another required embolisation after stent removal. Membrane degradation, membrane separation, and incomplete expansion of the stent are other less common complications. Nonetheless, further development in stent design and materials may decrease the complication rates and increase clinical success in the near future.

In the first case mentioned, the patient presented with a post-traumatic cervical spine injury. Anterior cervical spine surgery with implant fixation is a commonly performed surgery for the management of degenerative or post-traumatic cervical injury. Although rare, oesophageal

perforation occurring post-anterior cervical spine surgery can cause significant morbidity.¹⁶ Factors thought to contribute include the suboptimal placement of the implant and implant failure or breakage, exposing sharp edges that can erode through the oesophagus. The mass effect of the implant on the oesophageal wall, and ischaemia secondary to pressure while swallowing have also been proposed as possible causative factors.¹⁷

Whatever the cause, the resultant perforation is usually managed with implant removal whenever feasible. Surgical correction with primary closure and a sternocleidomastoid flap is considered the gold standard for the treatment of such cases.¹⁸ In this case, as the flap placement and primary closure failed to plug the leak, an out-of-the-box solution was used wherein the SEMS effectively closed the oesophageal leak while retaining the cervical implant for effective healing of the fracture. The choice of an appropriate stent was crucial. As per conventional wisdom, stent placement within 1–2 cm of the upper oesophageal sphincter is contraindicated as it is associated with a high risk of perforation, aspiration, tracheal compression, and foreign body sensation.¹⁹ However, the introduction of the cervical stent has made this task possible. The stent had a narrow proximal flare, resulting in less pressure in the proximal oesophagus, thereby minimising injury. The authors chose a fully covered stent as this was a benign case with stent removal planned after 10–12 weeks. Although distal migration of the stent was another concern, the use of clips was not possible in this case due to the proximity of the stent to the upper oesophageal sphincter.

In the second case, a symptomatic oesophageal diverticulum recurred post-surgical correction. As a repeat surgery was considered risky due to comorbid conditions, SEMS was utilised. Oesophageal diverticula are rare disorders presenting with dysphagia, chest pain, and regurgitation. Depending on their location, they can be categorised as epiphrenic, Zenker's, or Rokitansky diverticula. Epiphrenic diverticula are pseudodiverticula of the pulsion type that are located in the distal oesophagus. Oesophageal motility disorders and congenital weakness in the oesophageal wall have been thought to be pathological factors, and 75–100% of patients with an epiphrenic diverticulum have an underlying

primary oesophageal motility disorder.²⁰ Many patients may remain asymptomatic and do not require interventions. Symptomatic patients may have dysphagia and/or regurgitation, and some may present with respiratory symptoms like aspiration, asthma, etc.^{21,22} All symptomatic patients require intervention.

Traditionally, surgical resection of the diverticulum has been advised either with a transthoracic approach, or by laparoscopy. Myotomy and fundoplication are usually performed together alongside the resection when an underlying motility disorder is suspected.²³ Endoscopic peroral endoscopic myotomy with septotomy for the treatment of distal oesophageal diverticula was also considered. While these approaches have good long-term results, leaks are common, which can cause significant morbidity, so these may be a difficult option in high-risk patients. Only a few cases have been reported in the literature where a surgically unfit patient has been treated with SEMS placement.²⁴

The Niti-S Beta™ Stent (Taewoong Medical, Seoul, South Korea) used in the present case is a fully covered oesophageal stent that was designed for the treatment of suture line leaks occurring after bariatric surgeries. The stent has two bumps over the body that prevent migration by increasing the radial pressure. As the oesophageal narrowing in this case was focal with proximal oesophageal dilation, the risk of stent migration was high. A Beta stent was chosen to minimise the risk of migration; additional stent fixation or suturing was not necessary. A study that used Beta oesophageal stents for anastomotic leaks and following a total or proximal gastrectomy reported a migration rate of 7.1%, without any additional stent-fixing procedures. The stent migration rate was 13% for conventional stents with clips and 17% for suture fixation.²⁵

On the other hand, another retrospective study investigating the use of Beta oesophageal stents in staple line leaks showed a migration rate of 32%, with no significant decrease in the stent migration rates.²⁶ In this case, despite using an anti-migratory stent, the stent migrated distally after 8 weeks. Although this duration was sufficient to dilate the stricture in the present case, an additional application of haemclip or an over-the-scope clip could be considered to prevent early migration.

Equally rare is the non-surgical management of an adult-onset presentation of COS, a rare disorder that usually presents in infancy or childhood and manifests with progressive dysphagia and vomiting.²⁷ Three forms of the disease are known to exist: membranous diaphragm; hypertrophy and fibrosis of the submucosa and muscularis propria; and tracheobronchial remnants like cartridges and glands in the oesophageal wall. As rare as its incidence, it is rarer for the disease to go unnoticed till adulthood. Nevertheless, many cases of mild stenosis going unnoticed and being diagnosed in adulthood have been reported in the literature.^{28,29} Classically labelled as 'slow eaters', a modification of diet in cases with mild dysphagia may lead to delayed recognition of the problem. Once diagnosed, the treatments that are usually considered include dilation and surgery.

Many case reports have reported success in treating adult-onset cases with bougie dilations.^{29,30} A systemic review by Terui et al.³¹ concluded that both balloon and bougie dilations are effective forms of treatment for COS. Dilation was less effective in the tracheobronchial subtype of COS, and surgery has been recommended in those instances. The success rate in dilation with or without case selection (endoscopic ultrasound to exclude the tracheobronchial subtype of COS) was reported to be 89.7% and 28.9%, respectively. The rate of perforation with or without case selection was 7.4% and 23.9%, respectively. In this case, repeated dilation failed. Although the next logical mode of therapy would be surgery, SEMS placement was an innovative, non-surgical therapy that was successful in alleviating the symptoms. The literature search did not return any clinical trials studying the use of SEMS in COS. Although SEPS and BDS could have been used in this case, the authors considered the metal stent as they had more personal experience using SEMS compared with SEPS and BDS. Stent migration was not considered to be a challenge in this case due to the length of the stricture, so stent fixation was not considered.

In the final case of post-corrosive injury with GOO, SEMS was used successfully to restore the patency of the GI tract. Corrosive injury of the upper GI tract remains a frequent problem with high post-injury morbidity. Alkali ingestion affects

the oesophagus, while gastric injuries are marked with acid burns; the squamous epithelium of the oesophagus is more resistant to acid penetration, while the free gastric acid buffers the alkaline agents, limiting injury.³²⁻³⁴ GOO usually manifests 3–4 weeks post-injury, but can be as early as 1 week, as per a few case reports.^{35,36} Endoscopic balloon dilation has been proved to be an effective intervention in patients with corrosive GOO. However, unlike in ulcer-related GOO, the recurrence of the stricture is common in caustic GOO, and is seen in up to two-thirds of patients.^{37,38} SEMS placement can be used as an alternative therapy in such patients.

Manta et al.³⁹ treated three patients with refractory corrosive antral stenosis with SEMS placement, and Choi et al.⁴⁰ treated 22 patients with benign antropyloric stenosis with SEMS. Despite stent migration being a major concern, most patients with late SEMS migration remained asymptomatic. SEPS and BDS are predominantly used for benign oesophageal lesions, and there is scant information in the literature regarding their use in either benign or malignant GOO. The authors used a fully covered SEMS with a wide flare; the duodenal bend also acts as an anchor,

decreasing the chances of migration, so no stent fixation methods were employed. Another unique problem reported with the use of SEMS in treating caustic strictures is the extensive granulation tissue proliferation at the ends of SEMS, leading to ingrowth and membrane disintegration. These factors can interfere with stent removal and may require the use of argon plasma coagulation to separate the stent from the granulation tissue.³⁹ SEMS placement may be an effective alternative to surgery in corrosive GOO, but more studies are needed to evaluate this treatment.

CONCLUSION

Benign oesophageal and gastric strictures and leaks may be managed by surgery or endoscopic therapy. In this paper, the authors outline a few complex and rare presentations of cases that were managed with innovative, mostly out-of-the-box treatment methods. SEMS placement successfully re-established the luminal patency with good clinical outcomes and minimal complications in all of these cases.


References

- Acunaş B et al. Palliation of malignant esophageal strictures with self-expanding nitinol stents: drawbacks and complications. *Radiology*. 1996;199(3):648-52.
- Saranovic D et al. Fluoroscopically guided insertion of self-expandable metal esophageal stents for palliative treatment of patients with malignant stenosis of esophagus and cardia: comparison of uncovered and covered stent types. *Dis Esophagus*. 2005;18(4):230-8.
- Vanbiervliet G et al. The role of clips in preventing migration of fully covered metallic esophageal stents: a pilot comparative study. *Surg Endosc*. 2012;26(1):53-9.
- Watanabe K et al. Feasibility of esophageal stent fixation with an over-the-scope-clip for malignant esophageal strictures to prevent migration. *Endosc Int Open*. 2017;5(11):E1044-9.
- Bick BL et al. Endoscopic suturing of esophageal fully covered self-expanding metal stents reduces rates of stent migration. *Gastrointest Endosc*. 2017;86(6):1015-21.
- Shim CS. Esophageal stent for cervical esophagus and esophagogastric junction. *Clin Endosc*. 2012;45(3):235-9.
- Dua KS et al. A phase III, multicenter, prospective, single-blinded, noninferiority, randomized controlled trial on the performance of a novel esophageal stent with an antireflux valve (with video). *Gastrointest Endosc*. 2019;90(1):64-74.e3.
- Hramiec JE et al. Expandable metallic esophageal stents in benign disease: a cause for concern. *Surg Laparosc Endosc*. 1998;8(1):40-3.
- Langer FB et al. Management of postoperative esophageal leaks with the Polyflex self-expanding covered plastic stent. *Ann Thorac Surg*. 2005;79(2):398-403.
- Radecke K et al. Impact of a self-expanding, plastic esophageal stent on various esophageal stenoses, fistulas, and leakages: a single-center experience in 39 patients. *Gastrointest Endosc*. 2005;61(7):812-8.
- Gkolfakis P et al. Biodegradable esophageal stents for the treatment of refractory benign esophageal strictures. *Ann Gastroenterol*. 2020;33(4):330-7.
- Fuccio L et al. Clinical outcomes following stent placement in refractory benign esophageal stricture: a systematic review and meta-analysis. *Endoscopy*. 2016;48(2):141-8.
- Canena JMT et al. A comparison of the temporary placement of 3 different self-expanding stents for the treatment of refractory benign esophageal strictures: a prospective multicentre study. *BMC Gastroenterol*. 2012;12:70.
- Kim KY et al. Self-expandable metallic stent placement for the palliation of esophageal cancer. *J Korean Med Sci*. 2017;32(7):1062-71.
- Na HK et al. How to design the optimal self-expandable oesophageal metallic stents: 22 years of experience in 645 patients with malignant strictures. *Eur Radiol*. 2013;23(3):786-96.
- Newhouse KE et al. Esophageal

- perforation following anterior cervical spine surgery. *Spine (Phila Pa 1976)*. 1989;14(10):1051-3.
17. Dakwar E et al. Management of delayed esophageal perforations after anterior cervical spinal surgery. *J Neurosurg Spine*. 2009;11(3):320-5.
 18. Ahn S-H et al. Successful repair of esophageal perforation after anterior cervical fusion for cervical spine fracture. *J Clin Neurosci*. 2011;18(10):1374-80.
 19. Gislason GT, Pasricha PJ. Crossing the upper limit: esophageal stenting in the proximal esophagus. *Dysphagia*. 1997;12(2):84-5.
 20. Nehra D et al. Physiologic basis for the treatment of epiphrenic diverticulum. *Ann Surg*. 2002;235(3):346-54.
 21. Altorki NK et al. Thoracic esophageal diverticula. Why is operation necessary? *J Thorac Cardiovasc Surg*. 1993;105(2):260-4.
 22. Tedesco P et al. Cause and treatment of epiphrenic diverticula. *Am J Surg*. 2005;190(6):891-4.
 23. Soares R et al. Epiphrenic diverticulum of the esophagus. From pathophysiology to treatment. *J Gastrointest Surg*. 2010;14(12):2009-15.
 24. Aiolfi A et al. Endoscopic treatment of an epiphrenic diverticulum using a fully covered self-expanding metal stent. *Endoscopy*. 2013;45(Suppl 2):E101.
 25. Kim Y-I et al. Effectiveness of a novel covered stent without external thread fixation for anastomotic leakage after total or proximal gastrectomy for gastric cancer. *Cancers (Basel)*. 2021;13(15):3720.
 26. Boerlage TCC et al. A novel fully covered double-bump stent for staple line leaks after bariatric surgery: a retrospective analysis. *Surg Endosc*. 2018;32(7):3174-80.
 27. Murphy SG et al. Isolated congenital esophageal stenosis. *J Pediatr Surg*. 1995;30(8):1238-41.
 28. Katzka DA et al. Congenital esophageal stenosis in adults. *Am J Gastroenterol*. 2000;95(1):32-6.
 29. Younes Z, Johnson DA. Congenital esophageal stenosis: clinical and endoscopic features in adults. *Dig Dis*. 1999;17(3):172-7.
 30. McNally PR et al. Congenital esophageal stenosis presenting as noncardiac, esophageal chest pain. *Dig Dis Sci*. 1993;38(2):369-73.
 31. Terui K et al. Endoscopic management for congenital esophageal stenosis: a systematic review. *World J Gastrointest Endosc*. 2015;7(3):183-91.
 32. Gray HK, Holmes CL. Pyloric stenosis caused by ingestion of corrosive substances: report of case. *Surg Clin North Am*. 1948;28(4):1041-56.
 33. Maggi AL, Meeroff M. Stenosis of the stomach caused by corrosive gastritis. *Gastroenterology*. 1953;24(4):573-8.
 34. McAuley CE et al. Late sequelae of gastric acid injury. *Am J Surg*. 1985;149(3):412-5.
 35. Jalundhwala JM, Shah RC. Corrosive stricture of the stomach. *Am J Surg*. 1967;114(3):461-4.
 36. Gonzalez LL et al. Cicatricial gastric stenosis caused by ingestion of corrosive. *Ann Surg*. 1962;156(1):84-9.
 37. Kochhar R, et al. Endoscopic balloon dilatation of benign gastric outlet obstruction. *J Gastroenterol Hepatol*. 2004;19(4):418-22.
 38. Solt J et al. Long-term results of balloon catheter dilation for benign gastric outlet stenosis. *Endoscopy*. 2003;35(6):490-5.
 39. Manta R et al. Self-expandable metal stenting of refractory upper gut corrosive strictures: a new role for endoscopy? *Case Rep Gastrointest Med*. 2011;2011:346413.
 40. Choi WJ et al. Effects of the temporary placement of a self-expandable metallic stent in benign pyloric stenosis. *Gut Liver*. 2013;7(4):417-22.

FOR REPRINT QUERIES PLEASE CONTACT: INFO@EMJREVIEWS.COM

Implications of the COVID-19 Pandemic on the Management of Inflammatory Bowel Disease in the Low Resource Countries of Asia


Authors:

Partha Pal,¹ Joyce Wing Yan Mak,² Siew C Ng,²
*Rupa Banerjee¹

1. Department of Medical Gastroenterology, Asian Institute of Gastroenterology, Hyderabad, Telangana, India

2. Department of Medicine and Therapeutics, Institute of Digestive Disease, State Key Laboratory of Digestive Diseases, Li Ka Shing Institute of Health Sciences, Chinese University of Hong Kong, China

*Correspondence to dr_rupa_banerjee@hotmail.com

Disclosure:

The authors have declared no conflicts of interest.

Received:

11.05.21

Accepted:

26.11.21

Keywords:

Asia, COVID-19, inflammatory bowel disease, low- and middle-income countries.

Citation:

EMJ Gastroenterol. 2022; DOI/ 10.33590/emjgastroenterol/21-00104. <https://doi.org/10.33590/emjgastroenterol/21-00104>

Abstract

The COVID-19 pandemic has overwhelmed the already limited healthcare systems of low resource Asian countries. It has had a profound impact on inflammatory bowel disease (IBD) patient care in this region, where the disease is emerging. Fear of increased risk of COVID-19 due to disease or drugs, lack of access to medications, laboratory testing, endoscopy, surgery, infusion centres, and even remote medical consultation have made the lives of patients with IBD in this region more difficult than before. Similarly, physicians faced challenges due to limited testing facilities and therapeutic armamentarium for IBD management in the face of the COVID-19 pandemic. There was also the fear of potential spread of COVID-19 during colonoscopy or physical consultation, with the shortage of protective equipment, and unfamiliarity with teleconsultation and the remote monitoring of IBD. Most of the healthcare systems in these countries faced similar challenges in disease containment and management due to overwhelmed healthcare facilities in the face of crisis, inadequate vaccination drive in highly populous regions, and the unequal distribution of healthcare facilities centred in urban areas. COVID-19-specific safety norms, proper psychological support, and IBD-focused COVID-19 information can help alleviate patient concerns. Widespread adaptation of telemedicine, being up to date with current evidence, and performing endoscopy in high-priority cases, with precautions, can help physicians treat patients with IBD optimally. Additionally, the restructuring of the public health system, widespread vaccine rollout, and, ultimately, containment of the pandemic, can improve healthcare outcomes of patients with IBD in low resource countries.

Key Points

1. Healthcare in low resource countries in Asia has been overwhelmed due to the COVID-19 pandemic, particularly with regard to the emerging disease of inflammatory bowel disease (IBD).
2. Both patients with IBD and physicians treating the disease have faced myriad challenges, from lack of access to medications and limited testing facilities, to the fear of COVID-19 spreading during in-person consultations.
3. In this article, the authors propose many solutions to alleviate healthcare for patients with IBD during the pandemic, including widening the use of telemedicine and prioritising management guidelines for this patient group.

INTRODUCTION

Since the declaration of the COVID-19 pandemic on 11th March 2020, the disease has barrelled across 222 countries, infecting nearly 1.5 billion people. The spread continues unabated.¹ The rapidly increasing demand for health facilities and healthcare workers has had a huge impact and has overstretched the global healthcare systems in even the most developed of nations.²

In this scenario, management of patients with chronic lifelong diseases such as inflammatory bowel disease (IBD) requires special considerations.³ These patients are often malnourished and immunocompromised, and, therefore, are at high risk of COVID-19 infection. The medication protocol may need to be modified, ensuring disease control, and avoiding steroids in particular, which could be associated with a poor prognosis.⁴ Additionally, there are issues of hospital visits for follow-ups or infusions, performance of elective procedures and surgeries, and allaying the fears and anxieties of patients.⁵ These are global concerns as the pandemic continues, and second and third waves of infections are being reported.

There are unique challenges in IBD management in the developing world, which are quite distinct from those in developed countries.⁶ These range from the perspectives of patients regarding access to care and affordability of drugs during lockdowns, to the physician's perspective of diagnostic dilemmas due to high prevalence of other infectious febrile illnesses. The rural and primary healthcare network of these low resource countries is ill-equipped to deal with IBD with limited resources, management facilities, or physician awareness.

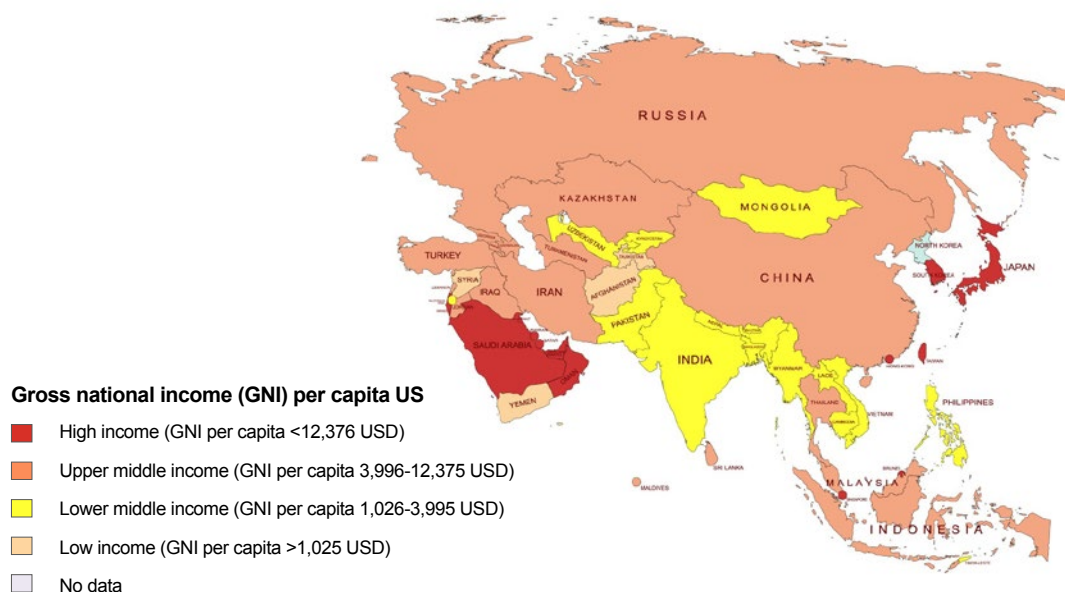
This review attempts to analyse the various challenges in the management of IBD amidst the pandemic in limited resource settings, the possible change in standard practices warranted, and future strategies to optimise therapy more suited to the region. For the purpose of the review, the authors considered low- and middle-income countries in Asia (Figure 1) based on World Bank classification as resource-limited countries, as they face similar challenges.⁷ The authors interviewed IBD specialists from these countries for their opinions and conducted a questionnaire-based survey of patients for the purpose of this review, since precise published data is limited.

THE IMPACT OF THE PANDEMIC ON INFLAMMATORY BOWEL DISEASE MANAGEMENT HAS BOTH PATIENT AND PHYSICIAN PERSPECTIVES

The Patient Perspective

The fear of increased risk of COVID-19 infection

The fear of contracting COVID-19 in patients with IBD is exacerbated by the general perception that IBD and its immunosuppressive therapies predispose an increased risk of contracting infection. Hence, most patients are afraid of visiting the hospital or IBD centre to consult a gastroenterologist. There is a lack of IBD management information for during the pandemic for the average patient, mainly due to the paucity of teleconsultation facilities and group awareness sessions.⁸ The majority of hospitals in India saw a drop in outpatient numbers by more than 50% for many months, and routine follow-ups also dropped by nearly 60%.⁹ Endoscopy

Figure 1: Gross national income per capita in Asian countries according to World Bank.⁷

units in India were performing at less than 10% of their usual volume during April 2020.¹⁰ Most teleconsultations did not focus on information and allaying of fears due to lack of adequate training in telemedicine (Figure 2).^{11,12}

This trend has been noted across the world. In fact, a 50% drop in emergency department visits was reported in the USA.¹³ In a global survey of 3,815 patients from 51 countries in Europe, America, Australia, Africa, and Asia, 85% of respondents feared developing the COVID-19 infection.⁵ About one-third of patients believed that IBD predisposes them to an increased risk of contracting COVID-19 infection. Eighty-seven per cent of patients were afraid to travel, and more than 70% were afraid to visit hospitals or IBD centres. Surprisingly a physician consultation did not help, and alleviated worries in only 11.1% of cases. Patient association and support groups were the most helpful (82.5%), but these are not available in the majority of low resource countries.⁵

Online consultation and telemedicine have become the norm in many countries. In a study from China, only 13% of patients with IBD visited hospitals, or emergency departments in non-COVID-19 hospitals, while 50% had online







consultations with their physicians. Scheduled follow-ups were impacted in up to 70% of cases due to the pandemic.¹⁴

In Wuhan, China, the epicentre of COVID-19, all 318 patients with IBD from a regional IBD centre only sought medical care, or contacted doctors and pharmacies online after receiving educational and instructional information from the regional IBD centre through mobile messages and WeChat (Tencent Holdings Ltd., Shenzhen, China).¹⁵

However, telemedicine and online consultations are not readily available in resource-limited countries. The internet penetration rate in India, with a relatively better economy, was still 45% in 2020.¹⁶ The availability is likely to be worse in other countries, and is less than 20% in Bangladesh.¹⁷

Apart from limited internet facilities, network coverage, the unavailability of regulatory frameworks for data protection, a lack of information technology training, accessibility, and affordability are issues that need to be resolved.¹⁸⁻²⁰ Another hurdle for widespread implementation of telemedicine in developing countries is the cultural resistance, as it is hard for patients to believe that they can receive

Figure 2: Summary of the challenges faced in low resource countries in Asia and proposed strategies to overcome them.

Challenges faced by low resource countries in managing IBD during the COVID-19 pandemic	Solutions on overcoming the challenges
<p>Patient perspectives </p> <ul style="list-style-type: none"> • The fear of increased risk of COVID-19 infection • Unavailability of IBD medications • Difficulty in accessing and utilisation of healthcare system • Lack of infusion centres in primary care and district level • Worry about effects of COVID-19 vaccination 	<p>Patient perspectives </p> <ul style="list-style-type: none"> • Staying at home, ensure social distancing • Maintain good hygiene • Actively conveying IBD-focused COVID-19 information • Proper psychological support
<p>Physician perspectives </p> <ul style="list-style-type: none"> • Diagnostic challenges (new IBD and flare) • Dilemmas in drug therapy • Unavailability of adequate protective gear/infrastructure • Issues with remote monitoring of IBD 	<p>Physician perspectives </p> <ul style="list-style-type: none"> • Improve patients' communication e.g., telemedicine • Consider alternative therapies, e.g., curcumin, enteral nutrition • Precautions when performing endoscopy for patients with IBD • Limiting endoscopy to patients with high priority • Keep up to date with recent evidence on COVID-19
<p>Hospital or government perspectives </p> <ul style="list-style-type: none"> • Lack of adequate infrastructure (ventilators, oxygen supply, point of care testing facilities and even hospital beds) • Lack of adequate vaccine and drug supply • Scarcity of public health and primary care facilities in rural areas 	<p>Hospital or government perspectives </p> <ul style="list-style-type: none"> • Restructuring of public health response • Increasing vaccine supply and design proper distribution campaign • Develop own drug and vaccine supply chain • Reducing SARS-CoV-2 transmission, point of care testing facilities • Increase public awareness

IBD: inflammatory bowel disease; SARS-CoV-2: severe acute respiratory syndrome coronavirus 2.

healthcare without an in-person physician visit.²¹ The lack of widespread availability and/or acceptability of telemedicine pose specific challenges to IBD management in these regions.

Unavailability of drugs

Shortage of drug supply, high cost and/or side effects of therapy, and a lack of universal health insurance have affected access to medications for patients with IBD during the pandemic.²² Nearly two-thirds of patients with IBD had the perception that immunosuppressive IBD medications predispose them to COVID-19 infection. Despite this, only a small proportion actually stop their medications (4%).⁵ The national Chinese Society of Gastroenterology (CSG) did recommend the temporary cessation of biologics and immunosuppressants in the initial phase of the COVID-19 outbreak.¹⁵ In a digital survey from India, 46% of patients reported difficulty in availability of immunomodulators and biologics. Availability was better in urban areas (64%) compared with rural areas (37%), although not statistically

significant.⁸ In the authors' experience, nearly 4% stopped their IBD medications mainly due to the fear of getting COVID-19 infection, unavailability, a switch to alternative medicines, or awaiting a doctor's approval pending consultation. Of the authors' patients on biologics, 12% missed their scheduled dose due to the inability to visit the infusion centre during lockdown, and the unavailability of local infusion centres with expertise. The lack of infusion centres or trained primary physicians or nurses with regard to biologic infusion in districts and primary care settings was the reason why the majority of patients missed their scheduled biologics, which can lead to disease flare.²³⁻²⁵

The unavailability of drugs is another issue inherent to resource-limited countries. The lockdown policy has made it difficult for patients to visit medical clinics or hospitals for drugs. There has been a disruption of many drug supply chains, and the import and export of pharmaceuticals. For example, India depends on China for around 70% of the active

pharmaceutical ingredients that it uses in pharmaceutical manufacturing.²⁶ On the other hand, Myanmar depends on India for supplies of mesalamine (Table 1). If the pandemic continues long-term, this may drastically affect drug availability in many countries in the developing world, who depend on others for drug supply. This is likely to increase the cost of medications, resulting in patients discontinuing therapy, and becoming inclined to switch to often unproven complementary and alternative medications, more so in resource limited settings.²⁷ Moreover, unscrupulous faith healers are commonplace in this region.²⁸ Loss of pay or employment due to economic crisis, mental stress due to COVID-19-related mortality, and paranoia around media coverage further complicates the situation.

Difficulty in accessing and utilising healthcare systems

Poor access to healthcare is a key factor contributing to sub-optimal disease outcomes in patients with IBD in resource-limited settings. It is well understood that there is an unequal distribution of healthcare systems, with gross disparity between rural and urban settings in this entire region.²⁷

The COVID-19 outbreak has highlighted these limitations. IBD management has been centred around urban tertiary care centres, with patients travelling to cities for adequate care. With continuing lockdowns and travel restrictions, including the risks of public transport such as buses and trains, this has not been possible. This has resulted in patients having no option but the local health centre. Diagnostic tests, including colonoscopies, are not available in the majority of rural settings.²⁷ Also, there is poor awareness and understanding about IBD in primary healthcare centres.

The authors found, as a part of our teleconsultation experience, that patients missed their biologic doses because the local physician was uncertain on the mode of administration and risks, as well as a lack of confidence on the part of the patients. In our survey, more than one-third of the patients could not consult a doctor in person or online.

In a survey of IBD physicians, a respondent from Pakistan reported that the fear and

stigma of testing positive for the severe acute respiratory syndrome coronavirus 2 infection inhibited patients from accessing medical care.²⁹ Family and community pressure to consult with faith healers, lack of social support or patient support groups, high cost of medications, and no universal health insurance are challenges patients with IBD face in day-to-day life in resource-limited settings, according to a patient survey from South Asia.²⁸ The COVID-19 pandemic has complicated these issues even further, with a lack of proper information and guidance, with patients stopping medications such as steroids and biologics, and taking herbal or other alternative therapies thought to be safer.²⁴ In the authors' survey, they found that more than a quarter of patients with IBD use complementary and alternative medications, the most common reason being perception of safety.³⁰

Physician Factors

New diagnosis of inflammatory bowel disease

Current recommendations for new diagnosis of IBD during the ongoing pandemic suggests a higher threshold for endoscopy in patients presenting with abdominal pain and altered bowel habit, and carefully ruling out gastrointestinal manifestations of COVID-19 infection, infectious causes of diarrhoea, and irritable bowel syndrome by throat swab testing, stool culture or toxin assay, and stool biomarker (faecal calprotectin), respectively.³¹ The International Organization For the Study of Inflammatory Bowel Disease (IOIBD) expert list of recommendations considers new diagnosis of IBD as a high priority for endoscopy, even during the pandemic.³²

However, such recommendations may not be practical in resource-limited countries. The lack of COVID-19 testing facilities; adequate colonoscopy services, particularly in rural hospitals; or widespread availability of calprotectin assay poses difficulties. Patients are unable to travel to higher centres with adequate diagnostic facilities due to lockdown restrictions.²² In an international survey of IBD physicians, including the IBD-Emerging Nations' Consortium (IBD-ENC) region

Table 1: Survey of inflammatory bowel disease specialists about challenges faced during the COVID-19 pandemic in resource-limited settings.

Country	IBD drug availability	Availability of IBD specialists	Key challenges
Philippines	Severely hampered	Via telemedicine	Disruption of supply chain of IBD drugs Delayed endoscopy schedules Managing IBD patients in flare
Bangladesh	Available	Most of the government hospitals are only providing emergency healthcare services, and many specialists have already stopped their private practices	Limited availability of specialists, either in public or in private hospitals Shortage of PPE and also lack of implementation of disinfection policy, and limited facilities for testing for COVID-19 Movement of patients has become difficult due to restrictions of transport Physicians are afraid that asymptomatic attendants or patients may spread infection
Nepal	Available	Already limited prior to pandemic	Follow-up difficult due to lockdown Non-urgent colonoscopies postponed, causing delay in diagnosis and assessment
Myanmar	Lack of mesalazine stock, which is imported from India	All gastroenterologists are currently available	Difficult to make decisions to start immunosuppression in COVID-19 era Difficult to differentiate acute IBD flare and COVID-19 symptoms later on Unable to test all patients with IBD for COVID-19, as resources are limited Drug availability
Indonesia	All are available	None	Vaccination for influenza and pneumonia
Thailand	Available, but people in several provinces had difficulty procuring medications	Not much different	Telemedicine is indispensable Risk of infection in patients who need high-dose immunosuppressants; confusion regarding safety of immunomodulators Endoscopic procedures or surgery are postponed Clinical research has to be temporarily paused
Sri Lanka	No big issues	Available 90% of the time	Getting down biologics in future Affordability of expensive medicine due to economic factors

IBD: inflammatory bowel disease; PPE: personal protection equipment.

consisting of the low resource countries of Asia, show that some centres were avoiding endoscopy, even in newly-diagnosed patients, and a few treated cases of likely colitis with empirical 5-amino salicylic acid (5-ASA) therapy.²⁹

Dilemmas in drug therapy

Immunosuppressive drugs have been associated with an increased risk of opportunistic viral infections, and, as such, physicians have been concerned of their usage during the pandemic.³³ In a questionnaire-based survey of 813 physicians from 72 countries, more than two-thirds of the physicians believed that IBD drugs are associated with increased risk of COVID-19. In fact, 10% of the physicians stopped IBD drugs as a preventative measure (highest: thiopurines -72.7%; followed by steroids: -43.6%).⁵ This has important clinical implications on treating those who cannot afford treatment. Stopping azathioprine, a low-cost therapy, may lead to severe flares requiring steroids that are even more harmful, or high-cost biologics, which most would not be able to afford. Biologic therapy, however, is considered to be relatively safe and not associated with adverse outcomes in patients with COVID-19, while systemic corticosteroid was associated with a nearly seven-fold higher risk of developing severe COVID-19 infection.⁴ However, cost, unavailability, and the high risk of latent tuberculosis in resource-limited settings precluded its widespread use.³⁴ These dilemmas between risk and benefit of therapy are unique in low resource settings, and should be balanced on individual basis (Table 1).²⁷

The Surveillance Epidemiology of Coronavirus Under Research Exclusion (SECURE)-IBD data also suggests increased risk of severe COVID-19 with mesalamine; more so if associated with anti-TNF therapy. Although this uncontrolled observational data has limitations, the current therapeutic armamentarium to combat IBD is limited in resource-limited countries.³⁵

Diagnosis and treatment of flare

For diagnosis of IBD flare, guidelines recommend initially non-invasive measures such as faecal calprotectin measurement, followed by drug level monitoring, failing which endoscopy can be considered.³⁶ Moreover, all

patients with IBD presenting with diarrhoea are recommended to test for COVID-19 infection to discriminate true IBD flare from diarrhoea due to COVID-19, as at least 5% of patients present with isolated gastrointestinal symptoms.³⁷ However, these facilities are often not available in resource-limited settings.

Surgeries for IBD have also been delayed due to fear of contamination of intensive care units and operating theatres. Setting up a network of COVID-19-free hospitals, with dedicated IBD physicians and surgeons, and co-operation with other centres in the region, can allow prompt management of patients with IBD with severe flare, and can improve outcomes.³⁸

Availability of protective gear and infrastructure

Colonoscopy is the diagnostic procedure of choice in IBD. The Asian-Pacific Society for Digestive Endoscopy (APSDE) recommends that the entire endoscopy and colonoscopy staff team should wear full personal protective equipment (PPE).³⁹ However, given the worldwide shortage of PPE, this is impossible, especially in resource-limited countries.⁴⁰ Countries such as India have started manufacture their own PPE to meet the shortage, but still more manufacturing machines are needed to reduce the supply and demand gap.^{41,42} The Centers for Disease Control and Prevention (CDC) has issued a guidance on the extended use of N95 respirators in order to conserve resources.⁴³ Perhaps this should also be considered in order to conserve resources to protect healthcare workers in resource-limited settings.

In a worldwide survey of IBD physicians, respondents from Bangladesh and Thailand reported a lack of PPE supply, and a discrepancy between private and public hospitals for availability was reported in Brazil.²⁹

To add to this problem, there are shortages of equipment and infrastructure (shortage of intensive care units, ventilators, oxygen supply, and critical care personnel) to manage COVID-19 patients with IBD, a lack of critical care specialists, and a lack of awareness of IBD in community physicians.⁴⁴ Managing the combination of IBD and COVID-19 in this pandemic is a major challenge in low resource countries.

Issues with remote monitoring of inflammatory bowel disease

Telemedicine has emerged as an important resource in the management of patients with IBD during the COVID-19 pandemic, particularly in remote regions.⁴⁵ However, it is a difficult proposition in resource-limited settings where the internet is not widely available, and many physicians are still not digital-friendly. Moreover, few physicians are concerned about a hindrance to direct clinical decision-making, loss of relationship and trust with the patient, and the vulnerability of digital record maintenance.⁴⁶ As a consequence, resource-limited settings are still seeing sizeable in-person outpatient clinic walk-ins, though reduced from normal numbers, in Indonesia, Myanmar and Vietnam, compared with New Zealand, Canada, the UK, Qatar, and the USA, where the outpatient departments were effectively closed.²⁹

Barriers to vaccination

The uptake of recommended vaccines amongst patients with IBD have been sub-optimal historically. Vaccine distribution across the general population in resource-limited settings may have inordinate delays. India vaccinated less than 2% of its population earlier in 2021, which has now improved, with 70% of the population receiving at least one dose of a COVID-19 vaccine.⁴⁴ Hence, an increase in vaccine supply and a distribution campaign are warranted to cover both urban and rural areas.⁴⁴ The cost of vaccination should be kept under control so that vaccines can reach poorer communities. Proper storage facilities are warranted to maintain the vaccine cold chain, which is essential for vaccine efficacy. In view of the immunocompromised state of many patients with IBD, priority status should be given for vaccination. Since the mortality of COVID-19 infection increases exponentially with age, vaccination strategy is largely based on age in many countries, where older people (>60–65 years) are often given priority. IBD is an underlying health condition that puts patients at higher risk of serious disease and mortality; hence, vaccination should be prioritised in patients with IBD aged between 16–64 years.⁴⁷

There are concerns among patients with IBD and physicians regarding the safety and long-term effects of COVID-19 vaccination in IBD. Perceived risk of increased adverse events, interaction

between IBD medications and vaccine, scepticism about long-term safety, and lack of typical scrutiny for COVID-19 vaccination are barriers to vaccination in patients with IBD.^{48,49} However, the risk of adverse event to COVID-19 vaccination in patients with IBD is very low, and similar to that of general population. However, patients with IBD on immunomodulators can have sub-optimal antibody responses to vaccination, especially after a single dose of vaccine. Two vaccine doses lead to seroconversion in most patients. Delayed second dosing of vaccinations should be avoided, especially in patients receiving infliximab.⁵⁰ Hence, dissemination of proper information to patients with IBD, all IBD care providers, practicing physicians, gastroenterologists, and local government authorities are required to improve vaccination drive in this subgroup of patients.

Perspectives on How to Overcome, and the Way Forward

The effect of the COVID-19 pandemic in the resource-limited settings of Asia (Figure 2) is less commonly recognised.²² There are unique challenges and obstacles to implement global guidelines.

Widespread implementation of telemedicine in resource-limited settings is difficult, given that only a limited number of patients could use this service. Lack of universal access to the internet and smartphone facilities has reduced the impact of telemedicine in these regions. In spite of the obstacles, digital and telephonic remote consultation technology has been used like never before for follow-up of patients with IBD during the pandemic. The Government of India (GoI) have legalised teleconsultation during the pandemic. They also introduced the eSanjeevani telemedicine service in August 2020, which performed nearly 3 million non-COVID-19 consultations to March 2021.¹² There was an overwhelming response to online certificate and diploma courses in telemedicine among physicians, which already indicates the increasing popularity of telemedicine.¹² This could have a lasting effect in India, where the healthcare system distribution is skewed towards urban areas. Group patient awareness programs and video conferences can be useful in educating patients about COVID-19 and IBD.⁸

Reorganisation of IBD management strategies is warranted in pandemic settings. Shortages of beds during the COVID-19 pandemic is an important issue in the developing world, as many centres were converted to COVID-19 centres. Rescheduling of appointments to video or telephonic consultation, treating flares with oral steroids after real-time PCR testing (available for free), and/or the escalation of 5-ASA dosage, limiting endoscopy for emergency (acute severe colitis, haemorrhage, etc.), and admitting only if steroids fail through online appointment, can help to manage patients with IBD in resource-limited settings.²

Optimising drug management in IBD in resource-limited settings is different from other parts of the world. According to the American and European guidelines of IBD in COVID-19, steroids and azathioprine are considered unsafe, whereas biologics and 5-ASA are considered safe. They also advise to stop or taper steroids quickly (10 mg/week) if used for treatment of flares and recommend anti-TNF monotherapy for maintenance of remission.^{36,51} However, due to the lack of universal health insurance, most of the treatment expenditure is borne by patients. Moreover, the risk of reactivation of tuberculosis is also substantial. This hinders the use of Western guidelines in the resource-limited Asian context. These guidelines are based more on opinions, rather than high-quality scientific evidence. In a digital survey of patients with IBD, the frequency of COVID-19 was not higher in patients using immunomodulators, although the sample size was small. Therefore, steroids and azathioprine remain attractive options for treating flares and maintaining remission, due to their low cost.²² COVID-19 testing prior to initiation of steroids or immunomodulators; adequate COVID-19 safety precautions; universal COVID-19 vaccinations for all patients with IBD;

and use of alternative therapies like enteral nutrition and curcumin can be useful drug management strategies in patients with IBD in the current scenario, in resource-limited settings.⁵²

Limiting endoscopy to high-priority cases (e.g., acute severe ulcerative colitis, acute gastrointestinal bleeding, cholangitis in concurrent primary sclerosing cholangitis, partial small bowel obstruction, and new diagnosis of IBD), postponing of screening endoscopy for cancer surveillance, and the use of faecal calprotectin to assess disease activity are useful strategies to manage endoscopy in patients with IBD during the pandemic. However, nearly a half of patients could not undergo investigations like faecal calprotectin and total leucocyte count, according to a telephonic survey of patients undergoing teleconsultation.⁸ Widespread availability of faecal calprotectin testing is an issue in resource-limited settings.

Limited outpatient services, initiation of telemedicine services, and admitting only complicated IBD cases such as acute severe colitis can help manage the shortage of beds.^{22,52}

Training physicians in telemedicine skills and biologic infusion, regular educational activity with IBD, and COVID-19-related information for physicians taking care of patients with IBD can improve care.¹²

IBD opinion leaders in this region should come together in resource-limited areas to prioritise management guidelines of patients with IBD, based on high-quality scientific evidence. Organisations like the IBD-ENC can play a crucial role in this by fostering a network for research collaboration and improving outcomes of patients with IBD in this challenging scenario.⁵³

References


1. Worldometer. Live COVID-19 pandemic cases. Available at: https://www.worldometers.info/coronavirus/?utm_campaign=homeAdvegas1. Last accessed: 27 April 2021.
2. World Health Organization (WHO). COVID-19 significantly impacts health services for noncommunicable diseases. Available at: <https://www.who.int/news/item/01-06-2020-covid-19-significantly-impacts-health-services-for-noncommunicable-diseases>. Last accessed: 7 January 2021
3. Ling KL et al. Asian Pacific Association of Gastroenterology (APAGE) Inflammatory Bowel Disease (IBD) Working Party guidelines on IBD management during the COVID-19 pandemic. *JGH Open*. 2020;4(3):320-3.
4. Brenner EJ et al. Corticosteroids, but not TNF α antagonists, are associated with adverse COVID-19 outcomes in patients with inflammatory bowel diseases: results from an international registry. *Gastroenterology*. 2020;159(2):481-91.e3.
5. D'Amico F et al. Views of patients with inflammatory bowel disease on the COVID-19 pandemic: a global survey.

- Lancet Gastroenterol Hepatol. 2020;5(7):631-2.
6. Hopman J et al. Managing COVID-19 in low- and middle-income countries. *JAMA*. 2020;323(16):1549-50.
 7. The World Bank. GNI per capita, Atlas method (current US\$) – Yemen, Rep. Available at: <https://data.worldbank.org/indicator/NY.GNP.PCAP.CD?locations=YE>. Date accessed: 9 May 2021.
 8. Ghoshal UC et al. Care of inflammatory bowel disease patients during coronavirus disease-19 pandemic using digital health-care technology. *JGH Open*. 2021;5(5):535-41.
 9. Vaishya R et al. Severe impact of COVID-19 pandemic on non-COVID patient care and health delivery: an observational study from a large multispecialty hospital of India. *Indian J Med Sci*. 2021;73(2):159-63.
 10. Goenka MK et al. Impact of COVID-19 on gastrointestinal endoscopy practice in India: a cross-sectional study. *Endosc Int Open*. 2020;8(7):E974-9.
 11. McConnochie KM. Webside manner: a key to high-quality primary care telemedicine for all. *Telemed J E Health*. 2018;25(11):1007-11.
 12. Dash S et al. Telemedicine during COVID-19 in India—a new policy and its challenges. *J Public Health Policy*. 2021;42(3):501-9.
 13. Wong LE et al. Where are all the patients? addressing Covid-19 fear to encourage sick patients to seek emergency care. *NEJM Catal Innov Care Deliv*. 2020;DOI:10.1056/CAT.20.0193.
 14. Bai X et al. COVID-19 outbreak and inflammatory bowel disease management: a questionnaire survey from realistic practice. *J Crohns Colitis*. 2020;14(10):1494-5.
 15. An P et al. Prevention of COVID-19 in patients with inflammatory bowel disease in Wuhan, China. *Lancet Gastroenterol Hepatol*. 2020;5(6):525-7.
 16. Keelery S. Internet usage in India – statistics & facts. Available at: <https://www.statista.com/topics/2157/internet-usage-in-india/#dossierKeyfigures>. Last accessed: 2 August 2021.
 17. Statista Research Department. Internet penetration rate in Bangladesh from 2010 to 2019. Available at: <https://www.statista.com/statistics/764102/internet-penetration-rate-bangladesh/>. Last accessed: 7 January 2021.
 18. Mahmood F et al. Current challenges of digital health interventions in Pakistan: mixed methods analysis. *J Med Internet Res*. 2020;22(9):e21691.
 19. Chowdhury SR et al. Telemedicine is an important aspect of healthcare services amid COVID-19 outbreak: its barriers in Bangladesh and strategies to overcome. *Int J Health Plann Manage*. 2021;36(1):4-12.
 20. Nit B et al. The introduction of telemedicine is required immediately in Cambodia: barriers and lessons from COVID-19. *J Glob Health*. 2021;11:03047.
 21. Al-Samarraie H et al. Telemedicine in Middle Eastern countries: progress, barriers, and policy recommendations. *Int J Med Inform*. 2020;141:104232.
 22. Sharma V et al. Cost concerns, not the guidelines, drive clinical care of IBD during COVID pandemic in a resource limited setting. *Expert Rev Gastroenterol Hepatol*. 2021;15(4):465-6.
 23. Rubin DT et al. Management of patients with Crohn's disease and ulcerative colitis during the coronavirus disease-2019 pandemic: results of an international meeting. *Gastroenterology*. 2020;159(1):6-13.e6.
 24. Clough JN et al. Managing an IBD infusion unit during the COVID-19 pandemic: service modifications and the patient perspective. *Inflamm Bowel Dis*. 2020;26(10):e125-6.
 25. Tan M et al. General practitioners' knowledge of and attitudes to inflammatory bowel disease. *Intern Med J*. 2012;42(7):801-7.
 26. India Today. India can take on China in API sector but not without govt easing regulation, say pharma giants. 2020. Available at: <https://www.indiatoday.in/business/story/india-can-take-on-china-in-api-sector-but-not-without-govt-easing-regulation-say-pharma-giants-1691028-2020-06-20>. Date accessed: 20 June 2020.
 27. Banerjee R et al. Challenges in the diagnosis and management of inflammatory bowel disease in resource-limited settings in Asia. *Lancet Gastroenterol Hepatol*. 2020;5(12):1076-88.
 28. Mukherjee S et al. The need for culturally competent care within gastroenterology services: evidence from research with adults of South Asian origin living with inflammatory bowel disease. *J Crohns Colitis*. 2021;15(1):14-23.
 29. Bernstein CN et al. Worldwide management of inflammatory bowel disease during the COVID-19 pandemic: an international survey. *Inflamm Bowel Dis*. 2021;27(6):836-47.
 30. Banerjee R et al. Sa517 High prevalence of complementary and alternative medicine (CAM) use in Indian IBD patients irrespective of educational and socioeconomic status: it's the perception of safety that matters! *Gastroenterology*. 2021;160(6):S532-3.
 31. Lacucci M et al. Endoscopy in inflammatory bowel diseases during the COVID-19 pandemic and post-pandemic period. *Lancet Gastroenterol Hepatol*. 2020;5(6):598-606.
 32. Ng SC et al. COVID-19 pandemic: which IBD patients need to be scoped-who gets scoped now, who can wait, and how to resume to normal. *J Crohns Colitis*. 2020;14(Suppl 3):S791-7.
 33. Kirchesner J et al. Risk of serious and opportunistic infections associated with treatment of inflammatory bowel diseases. *Gastroenterology*. 2018;155(2):337-46.e10.
 34. Ooi CJ et al. Best practices on immunomodulators and biologic agents for ulcerative colitis and Crohn's disease in Asia. *Intest Res*. 2019;17(3):285-310.
 35. Ungaro RC et al. Effect of IBD medications on & COVID-19 outcomes: results from an international registry. *Gut*. 2020;70(4):725-32.
 36. Rubin DT et al. AGA clinical practice update on management of inflammatory bowel disease during the COVID-19 pandemic: expert commentary. *Gastroenterology*. 2020;159(1):350-7.
 37. Taxonera C et al. 2019 novel coronavirus disease (COVID-19) in patients with inflammatory bowel diseases. *Aliment Pharmacol Ther*. 2020;52(2):276-83.
 38. Remzi FH et al. International Organization for the Study of IBD recommendations for surgery in patients with IBD during the coronavirus disease 2019 pandemic. *Dis Colon Rectum*. 2020 Jul;63(7):870-3.
 39. Chiu PWY et al. Practice of endoscopy during COVID-19

- pandemic: position statements of the Asian Pacific Society for Digestive Endoscopy (APSDE-COVID statements). *Gut*. 2020;69(6):991-6.
40. Repici A et al. Coronavirus (COVID-19) outbreak: what the department of endoscopy should know. *Gastrointest Endosc*. 2020;92(1):192-7.
 41. Balsari S et al. COVID-19 care in India: the course to self-reliance. *Lancet Glob Health*. 2020;8(11):e1359-60.
 42. Centers for Disease Control and Prevention (CDC). Implementing filtering facepiece respirator (FFR) reuse, including reuse after decontamination, when there are known shortages of N95 respirators. 2020. Available at: <https://www.cdc.gov/coronavirus/2019-ncov/hcp/ppe-strategy/decontamination-reuse-respirators.html>. Last accessed: 8 May 2021.
 43. The Lancet. India's COVID-19 emergency. *Lancet*. 2021;397(10286):1683.
 44. Berg EA et al. COVID-19—a guide to rapid implementation of telehealth services: a playbook for the pediatric gastroenterologist. *J Pediatr Gastroenterol Nutr*. 2020;70(6):734-40.
 45. Das N et al. Attitude to telemedicine in the times of COVID-19 pandemic: opinion of medical practitioners from India. *Psychiatry Clin Neurosci*. 2020;74(10):560-2.
 46. Alexander JL et al. SARS-CoV-2 vaccination for patients with inflammatory bowel disease: a British Society of Gastroenterology Inflammatory Bowel Disease section and IBD Clinical Research Group position statement. *Lancet Gastroenterol Hepatol*. 2021;6(3):218-24.
 47. Malhi G et al. Vaccination in inflammatory bowel disease patients: attitudes, knowledge, and uptake. *J Crohns Colitis*. 2015;9:439-44.
 48. Dalal RS et al. COVID-19 vaccination intent and perceptions among patients with inflammatory bowel diseases. *Clin Gastroenterol Hepatol*. 2021;19(8):1730-2.
 49. Wong SY et al. Serologic response to messenger RNA coronavirus disease 2019 vaccines in inflammatory bowel disease patients receiving biologic therapies. *Gastroenterology*. 2021;161(2):715-8.
 50. Kennedy NA et al. British Society of Gastroenterology guidance for management of inflammatory bowel disease during the COVID-19 pandemic. *Gut*. 2020;69(6):984-90.
 51. El Ouali S et al. Optimal inflammatory bowel disease management during the global coronavirus disease 2019 pandemic. *Curr Opin Gastroenterol*. 2021;37(4):313-9.
 52. Hassibian MR, Hassibian S. Telemedicine acceptance and implementation in developing countries: benefits, categories, and barriers. *Razavi Int J Med*. 2016;4:e38332.
 53. Banerjee R et al. Sa1801 – emerging IBD demographics in South Asia and Middle East: a Pilot Study from the IBD Emerging Nations' Consortium (IBDENC). *Gastroenterology*. 2019;156(6):S-406.

FOR REPRINT QUERIES PLEASE CONTACT: INFO@EMJREVIEWS.COM

Gastrin-17 Levels in Pre-malignancy Gastritis Lesions



Authors:	*Sahat Halim, Gontar Alamsyah Siregar Department of Internal Medicine, Faculty of Medicine, University of Sumatera Utara, Medan, Indonesia *Correspondence to sahatthalim88@gmail.com
Disclosure:	The authors have declared no conflicts of interest.
Acknowledgements:	The authors gratefully acknowledge that the present research is supported by the Ministry of Research and Technology and the Higher Education Republic of Indonesia. The support is under the research grant TALENTA, Contract Number: 363 UN5.2.3.1/PPM/SP-TALENTA USU/2020. Author contribution: All authors were involved in planning and supervising the work, processing the data, performing the analysis, drafting the manuscript, designing the figures, calculations and statistical analysis, discussing the results, and commenting on the manuscript.
Received:	28.07.21
Accepted:	28.09.21
Keywords:	Gastrin, gastritis, pre-malignant.
Citation:	EMJ Gastroenterol. 2022; DOI/10.33590/emjgastroenterol/21-00156. https://doi.org/10.33590/emjgastroenterol/21-00156

Abstract

Background: Gastritis is an inflammatory process on the lining of the stomach that could be caused by various factors. Untreated inflammatory processes could lead to ulcers. Gastrin hormone is released by gastrin-secreting enteroendocrine cells (G cells) in the stomach, which influence the secretion of gastric acid and helps the proliferation of gastric epithelial cells. Its abnormal secretion in *H. pylori* infection, with food-stimulated excessive release of gastrin, is the most prominent abnormality. One concern is the relationship of excess gastrin secretion to the incidence of gastric cancer. This study aimed to show the difference in gastrin levels on patients with gastritis, both with and without pre-malignant lesions.

Methods: This research was a cross-sectional study with 40 samples that had met the inclusion and exclusion criteria. Endoscopy was performed to assess the gastric mucosa and tissue biopsy was performed afterward. The data was analysed in univariate and bivariate ways.

Results: From this study, 20 people were positive for pre-malignant lesions (50%). Mann-Whitney test analysis was used to analyse the data and showed there was a significant difference between gastrin levels on patients with gastritis with and without pre-malignant lesions, with a p value of 0.01.

Conclusion: There is a significant difference between gastrin levels in patients with gastritis with and without pre-malignant lesions, which could be the basis for early detection of patients with gastric cancer.

Key Points

1. An inflammatory process on the stomach lining, gastritis, like other inflammatory processes, could cause ulcers when left untreated; gastritis could even become gastric cancer.
2. Gastric cancer is the second most common cancer and is responsible for approximately 700,000 across the world; therefore, the authors were determined to discover if there is an association between gastrin hormone levels in patients with gastritis with or without pre-malignant lesions.
3. A total of 40 patients were enrolled in the study, and half of the participants were positive for pre-malignant lesions after endoscopic examination and these patients had higher than normal gastrin levels.

INTRODUCTION

Gastritis is an inflammatory process on the lining of the stomach that is quite frequent and can have various causes. Various types of agents can cause gastritis, including painkillers, abrasive compounds (such as alcohol, acids, etc.), an unbalanced diet where the stomach will be damaged by the stomach acid itself, long-term physical or mental stress that can cause excessive production of gastric acid, as well as an infection caused by a micro-organism, namely *Helicobacter pylori*. When this inflammation is left untreated, it can eventually become ulcers or, at worst, gastric cancer.¹

The interaction of *H. pylori* with the gastric mucosa activates several body responses including the release of inflammatory factors, some ILs, TNF- α , and leukotriene, which is cytotoxic to the gastric epithelium. This inflammatory response causes changes in the function of the stomach, depending on the location in the stomach involved. When inflammation involves the gastric corpus, parietal cells are inhibited thereby reducing gastric acid secretion. If this inflammation continues, the parietal cells continue to experience damage so that the reduction in acid secretion is permanent.^{1,2}

Inflammation of the antrum changes the interplay of gastrin with somatostatin, affecting G cells (cells that secrete gastrin) and D cells (cells that produce somatostatin), in reverse. Specifically, gastrin secretion is abnormal in *H. pylori* infection, with food-stimulated excessive release of gastrin being the most prominent abnormality.²

Gastrin is an important growth factor for the development of the digestive system. Gastrin is released from G cells in the antrum of the stomach during normal physiological digestion of food and serves as the main stimulator of acid secretion from the parietal cells of the stomach.³

One of the main concerns regarding hypergastrinaemia is the potential link between gastrin level and gastric cancer. When gastrin was administered to animals, there was a marked increase in the mass of parietal cells and enterochromaffin-like (ECL) cells from the stomach. Increased levels of gastrin in mice and humans have been associated with gastric carcinoid tumours arising from ECL cells. In cell culture, gastrin has been shown to stimulate the growth of the cancerous cell lining in the human stomach.³

Approximately 700,000 deaths in the world are caused by gastric cancer; therefore, gastric cancer is the second most common cancer causing death.⁴ Gastric carcinogenesis is an ongoing process. The majority of cases of gastric cancer are preceded by atrophic events.⁵ Chronic atrophic gastritis is an important precursor lesion in the development of gastric cancer. The natural course of gastric cancer is known as the Correa cascade;⁶ according to the Correa cascade, prolonged mucosal inflammation can cause the gastric mucosa to atrophy, which can lead to invasive cancer.

Thus, this study was carried out to determine the association of gastrin levels in patients with gastritis with or without pre-malignant lesions.

METHODS

This research was a cross-sectional study. Subjects were patients who came to H. Adam Malik Hospital, Medan, Indonesia, and the General Hospital of North Sumatera, Indonesia, with chronic abdominal pain and discomfort with a high pre-test probability of gastritis. The data were collected from March to October 2020. All patients underwent endoscopic and histopathological examination, then were categorised into patients with or without pre-malignant gastric lesions. The inclusion criteria were minimum age 18 years and agreement to take part. Exclusion criteria were pregnancy, and systemic diseases such as diabetes, liver disease, renal disease, heart disease, and malignancy. Patients who were on chronic proton pump inhibitors and H₂-antagonist receptors had stopped their medication for at least 10 days. The patients were not allowed to medicate at all or switch to other medication such as antacids or rebamipide.

Endoscopy was performed to assess the presence of any pre-cancerous lesion in the stomach, such as gastric atrophy, chronic gastritis, metaplasia, and dysplasia. All subjects were checked for gastrin level using the ELISA Human Gastrin-17 Kit (BIOHIT OYJ, Laippatie, FI-00880, Helsinki, Finland), which was examined in Prodia Laboratory, Surakarta, Indonesia.

Data analysis was performed in univariate and bivariate analysis (Mann–Whitney test) using SPSS® 22nd version (SPSS Inc., Chicago, Illinois, USA). A value of $p < 0.05$ was considered statistically significant.

RESULTS

Characteristics of Clinical and Socio-demographic Subjects

A total of 40 patients were enrolled in this study (Table 1). There were 22 male (55%) and 18 female (45%) subjects of study. The mean age was 53 years, with ages ranging from 30 to 68 years.

Based on endoscopic examination, 20 subjects (50%) had positive pre-malignant lesions. The mean value of gastrin blood level was 15.4 (0.4–50.4) pmol/mL among all subjects.

Difference in Gastrin Level in Patients With Gastritis With and Without Pre-malignant Lesions

Shapiro–Wilk normality test showed that the data in this study were not normally distributed ($p < 0.05$). Table 2 shows the result of the Mann–Whitney statistical test. There was a significant difference between gastrin levels in patients with gastritis with and without pre-malignant lesions.

Because $p < 0.05$ ($p = 0.01$), the alternative hypothesis is accepted.

As seen in Table 3, the overall average level of gastrin in all subjects was 15.02 pmol/mL, with a minimum level of 0.4 pmol/mL and a maximum level of 50.4 pmol/mL. Gastrin levels in patients with gastritis with pre-malignant lesions showed a higher average (21.33 pmol/mL). The average gastrin level was 8.72 pmol/mL in patients with gastritis without pre-malignant lesions.

DISCUSSION

Gastrin is a peptide hormone primarily responsible for enhancing gastric mucosal growth, its motility, and the secretion of hydrochloric acid into the stomach, and is produced by G cells. Both the antrum and duodenum have G cells (G-17 and G-34) that function to produce gastrin. Its secretion into the systemic circulation allows delivery of gastrin to parietal cells and ECL cells in the gastric fundus and cardiac. Gastrin then stimulates the proliferation of gastric mucosal endocrine cells such as parietal cells.^{7,8}

A total of 40 patients with gastritis were enrolled in this study. Twenty-two were male, with the highest gastritis rate in the age group 50–59 years, but there was no statistical significance. The average serum gastrin level in this study was 15.02 pmol/mL. Histopathological examination showed 20 subjects with a pre-malignant lesion, with minimum gastrin level in this group of 3.0 pmol/mL. Other research by Wang and Chen⁹ also found a similarly high level of gastrin was associated with pre-cancerous lesions and gastric cancer in Asian populations. Their study stated that the prevalence of atrophic gastritis tended to increase from benign to malignant lesions. Lesions such as atrophy might decrease acid secretion, while gastrin would increase

Table 1: Clinical and socio-demographic characteristics of research subjects.

Variable	N=40
Sex	
Male	22 (55%)
Female	18 (45%)
Age (years)	
53 (30–68)	
Age group (years)	
30–39	5 (12.5%)
40–49	3 (7.5%)
50–59	21 (52.5%)
>60	11 (27.5%)
Ethnicity	
Bataknese	20 (50%)
Javanese	16 (40%)
Acehnese	2 (5%)
Nias	2 (5%)
Pre-malignant lesions	
Positive	20 (50%)
Negative	20 (50%)
Gastrin levels (pmol/mL)	
Mean	15.02
Minimum	0.4
Maximum	50.4

through the acid feedback adjustment. In addition, the use of a proton pump inhibitor could also inhibit acid secretion leading to the elevated levels of gastrin.⁹

Based on this statistical study, the authors found a significant difference between gastrin levels on the incidence of gastritis with and without pre-malignant lesions. In the present study, gastrin level tended to be higher in subjects with pre-malignant lesions; other studies showed some similar and some varied findings (Table 4). A study by Shafaghi et al.¹⁰ showed a significant difference in gastrin blood level in patients with atrophy or metaplasia compared to patients without ($p < 0.05$). The study also showed that gastrin had fair sensitivity (59%) and specificity (61%) in diagnosing pre-malignant gastric lesions.¹⁰

Another study by Murphy et al.¹¹ showed that study subjects with elevated gastrin levels had an increased risk of gastric non-cardia adenocarcinomas (odds ratio: 1.92; 95% confidence interval: 1.21, 3.05).¹¹ A study by Soumyodhriti et al.¹² showed that serum gastrin was found to be elevated in all 30 patients who were planned to undergo gastric resection. This study also concluded that serum gastrin serves as a marker for diagnosis of gastric cancer but was not necessarily associated with an advanced stage of disease.¹²

Contradicting the previous studies, a study by Nejadi-Kelarijani et al.¹³ showed that gastrin-17 blood level was higher in non-atrophic gastritis (13.82 ± 1.7 pmol/L) compared to atrophic gastritis (8.32 ± 1.6 pmol/L) and gastric cancer (10.81 ± 2.8

Table 2: Mann–Whitney test.

Pre-cancer lesion	Gastrin-17 (mean ranks)	p
Positive	26.45	0.01
Negative	14.55	N/A

Table 3: Gastrin level differences in patients with gastritis (pmol/mL).

	N	Mean	Median	SD	Min–max
Whole study population	40	15.02	10.5	15.22	0.4–50.4
With pre-malignant lesion	20	21.33	18.1	15.75	3.0–48.3
Without pre-malignant lesion	20	8.72	2.7	11.99	0.4–50.4

Max: maximum; min: minimum; SD: standard deviation.

pmol/L), although this result was insignificant ($p=0.34$).¹³ Overall, shreds of evidence imply gastrin levels are higher in pre-malignant gastric lesions. The study by Handayani and Krisnuhoni¹⁴ showed that atrophy of the gastric body is a condition marked by the existence of atrophy of the oxyntic mucosa, which leads to hyposecretion of gastric acid, sending negative feedback to increase gastrin levels, which also increases the risk for neoplasm in the stomach.¹⁴

A study by Song et al.¹⁵ showed that one in 256 patients with normal mucosa, one in 85 patients with gastritis, one in 50 patients with atrophic gastritis, one in 39 patients with intestinal metaplasia, and one in 19 patients with dysplasia, will develop gastric cancer within 20 years; in Cox regression analyses, hazard ratios also incrementally increased with successive cascade stage, from 1.8 for minor mucosal change to 10.9 for dysplasia.¹⁵

A study by Yanaoka et al.⁵ showed that among 5,209 participants who were followed up to 10 years, 63 cases of cancer developed in the cohort, representing an incidence rate of 125 per 100,000 person-years. The cancer incidence rate was 276 per 100,000 person-years for the atrophy-positive group and 70 per 100,000 person-years for the atrophy-negative group.⁵ These findings implicate the importance of

managing patients with gastritis, as there are still possibilities for benign gastritis to evolve into malignant lesions.

According to a guideline released by the European Society of Gastrointestinal Endoscopy (ESGE), all patients with atrophic gastritis with or without dysplasia should undergo screening for malignancy and *H. pylori* eradication management. Patients without dysplasia should be followed-up and re-evaluated every 3 years. Patients with low-grade dysplasia can be evaluated every 12 months, while patients with high-grade dysplasia should be evaluated every 6–12 months, and when a visible lesion appears on endoscopic examination undergo staging and resection surgical management.¹⁶

LIMITATIONS

The authors are fully aware that this study had several limitations. The study sample number was small, which related to limited funding and resource problems. There was no follow-up period, so the authors cannot conclude whether the subjects developed malignant gastric cancer. The authors also only took one-time blood measurements, thus damaged or inadequate blood samples and errors in blood extraction

Table 4: Comparison of studies assessing gastrin levels.

	Gastrin level (pmol/mL)		
Present study			
	Pre-malignant lesions		Malignant lesions
Mean (based on group)	8.72		21.33
Overall mean (min-max)	15.02 (0.40-50.40)		
p value	0.01		
Shafaghi et al.,¹⁰ 2013			
	Atrophic gastritis	Metaplasia	Dysplasia
Mean (SD)	6.31 (10.73)	5.96 (9.58)	5.96 (6.76)
p value	<0.001	0.005	0.050
Murphy et al.,¹¹ 2017			
	Control	GNCA	
Median	13.9	17.0	
Nejadi-Kelarijani et al.,¹³ 2014			
	Non-atrophic	Atrophic	Gastric cancer
Mean±SE	13.82±1.7	8.32±1.6	10.81±2.8
p value	0.34		

GNCA: gastric non-cardia adenocarcinomas; max: maximum; min: minimum; SD: standard deviation; SE: standard error.

procedure were a possibility. All the subjects had a history of proton pump inhibitor or H2-histamine antagonist medications, which can result in bias of gastrin blood level.

a significant difference between gastrin level in patients with gastritis with and without pre-malignant lesions. This finding could be the basis of further research in gastrin uses for screening in patients with a risk of developing gastric cancer.

CONCLUSION

A total of 40 patients with gastritis were enrolled in this study. From this study, the authors found

References

1. Tonino P (ed.), Gastritis and Gastric Cancer: New Insights in Gastroprotection, Diagnosis, and Treatments (2011), London: InTech Open.
2. Marcus AJ. Chronic Gastritis. Medscape. 2017. Available at: <https://emedicine.medscape.com/article/176156-overview>. Last accessed: 1 February 2020.
3. Smith JP et al. Gastrin and gastric cancer. *Cell Mol Gastroenterol Hepatol*. 2017;4(1):75-83.
4. Parkin DM et al. Global cancer statistics, 2002. *CA Cancer J Clin*. 2005;55(2):74-108.
5. Yanaoka K et al. Cancer high-risk subjects identified by serum pepsinogen tests: outcomes after 10-year follow-up in asymptomatic middle-aged males. *Cancer Epidemiol Biomarkers Prev*. 2008;17(4):838-45.
6. Ohata H et al. Progression of chronic atrophic gastritis associated with Helicobacter pylori infection increases risk of gastric cancer. *Int J Cancer*. 2004;109(1):138-43.
7. Prosapio JG et al. Physiology, Gastrin. 2021. Available at: <https://www.ncbi.nlm.nih.gov/books/NBK534822/>. Last accessed: 1 February 2020.

8. Mattar R et al. Diagnosis accuracy of GatroPanel for atrophic gastritis in Brazilian Subjects and the effect of Proton Pump Inhibitor. *Arg Gastroenterol.* 2020;57(2):154-160.
9. Wang R Chen XZ. Prevalence of atrophic gastritis in southwest China and predictive strength of serum gastrin-17: a cross-sectional study (SIGES). *Sci Rep.* 2020;10(1):4523.
10. Shafaghi A et al. Serum gastrin and the pepsinogen I/II ratio as markers for diagnosis of premalignant gastric lesion. *Asian Pac J Cancer Prev.* 2013;14(6): 3931-6.
11. Murphy G et al. Serum gastrin and cholecystokinin are associated with subsequent development of gastric cancer in a prospective cohort of Finnish smokers. *Int J Epidemiol.* 2017;46(3): 914-23.
12. Soumyodhriti G et al. Serum gastrin level estimation, is it a prognostic indicator in operated carcinoma stomach patients? *Sch J App Med Sci.* 2016;4(4B):1208-11.
13. Nejadi-Kelarijani F et al. Diagnostic values of serum levels of pepsinogens and gastrin-17 for screening gastritis and gastric cancer in a high-risk area in northern Iran. *Asian Pac J Cancer Prev.* 2014;15(17):7433-6.
14. Handayani L, Krisnuhoni E. Demographic characteristic of fundic gland polyp and its association with gastritis in pathology, Anatomy Department Faculty of Medicine, University Indonesia/Cipto Mangunkusumo Hospital. 2017. Available at: <https://media.neliti.com/media/publications/196231-demographic-characteristic-of-fundic-gla-3bb4a183.pdf>. Last accessed: 4 October 2021.
15. Song H et al. Incidence of gastric cancer among patients with gastric precancerous lesions: observational cohort study in a low-risk Western population. *BMJ.* 2015;351:h4134.
16. Dinis-Ribeiro M et al. Management of precancerous conditions and lesions in the stomach (MAPS): guideline from the European Society of Gastrointestinal Endoscopy (ESGE), European Helicobacter Study Group (EHS), European Society of Pathology (ESP), and the Sociedade Portuguesa de Endoscopia Digestiva (SPED). *Endoscopy.* 2012;44(1):74-94.

FOR REPRINT QUERIES PLEASE CONTACT: INFO@EMJREVIEWS.COM

Conservative Management in a Patient with Recurrent Boerhaave Syndrome


Authors:

*Alexander J Kaye,¹ Daniel Rim,¹ Sushil Ahlawat²

1. Department of Medicine, Rutgers New Jersey Medical School, Newark, New Jersey, USA

2. Division of Gastroenterology and Hepatology, Rutgers New Jersey Medical School, Newark, New Jersey, USA

*Correspondence to akaye2015@gmail.com



Disclosure:

The authors have declared no conflicts of interest

Author Contributions:

Kaye wrote the article; Rim and Ahlawat edited the article; and Ahlawat is the article guarantor.

Received:

17.01.22

Accepted:

16.03.22

Keywords:

Boerhaave syndrome, conservative management, oesophageal perforation, oesophageal tear.

Citation:

EMJ Gastroenterol. 2022; DOI/10.33590/emjgastroenterol/22-00018. <https://doi.org/10.33590/emjgastroenterol/22-00018>

Abstract

Boerhaave syndrome (BS) is a full thickness oesophageal tear. Most cases require surgical correction. In rare cases, conservative management can be attempted. This case describes a 30-year-old patient with a history of BS 9 months prior, managed conservatively at that time, presenting with 2 days of vomiting. Their vitals and physical examination were within normal limits. Imaging revealed extensive air tracking along the mediastinum, oesophagus, and bilateral neck and chest wall consistent with BS. Gastrographin and barium oesophagrams showed no contrast extravasation. The patient was successfully treated with conservative measures including pantoprazole, piperacillin-tazobactam, cessation of oral intake, and parenteral nutrition. This case represents one of only two documented cases of recurrent BS in an adult patient in which both cases were managed conservatively. Of these two cases, this is the first report with the second episode of BS occurring more than 4 weeks after the first episode. Additionally, unlike the other recurrent BS case that was conservatively managed, this patient lacked any known comorbid risk factors for development of BS. While the management of this case resembles the care provided in some prior case reports, the significant variation and lack of standardisation in the approach of conservative BS treatment posed a significant challenge in developing a therapeutic plan. Given the absence of high-quality studies about conservatively managed BS, an increased sample size of case reports detailing their non-procedural management approaches and their subsequent outcomes would hopefully eventually clarify an optimal treatment regimen, and allow for standardisation of conservative BS treatment.

Key Points

1. Boerhaave syndrome is a full thickness oesophageal tear, associated with high mortality if not identified and treated promptly. In most cases, Boerhaave syndrome is managed either endoscopically or surgically to repair the tear.

2. Rarely, the condition is managed conservatively. This case presents one of two documented in the literature in which recurrent Boerhaave syndrome in an adult patient was managed conservatively on both occasions. Uniquely, in this case, the Boerhaave syndrome recurrence occurred more than 4 weeks after the index event.

3. There is a lack of standardised guidance for the non-procedural management of Boerhaave syndrome. Further studies with high quality data are required to provide an evidence-base for the informal criteria currently used to help guide clinician decision making and determine the optimal conservative management strategy.

INTRODUCTION

First described by Herman Boerhaave in 1724, Boerhaave syndrome (BS) is rare and involves a full thickness tear of the oesophagus.¹ The annual incidence of BS is approximately 3.1 cases per 1 million individuals.² Risk factors for BS include alcohol abuse, excessive indulgence of food, gastroesophageal reflux, peptic ulcer disease, vomiting, neurologic disease, and hiatal hernia.^{3,4} Early identification and treatment of BS is crucial, as delay in treatment is associated with high mortality.⁵ Nearly all cases require correction of the tear, either surgically or endoscopically. In rare cases, conservative management can be attempted.⁶ Here, the authors report a patient with a history only notable for BS 9 months prior, who presented with another episode of BS.

CASE REPORT

A 30-year-old patient with a past medical history of BS, and an abdominal stab wound 11 years prior, presented with approximately 48 hours of diffuse abdominal pain worst in the upper abdomen, nausea, vomiting, and decreased oral intake. The past medical history of BS occurred 9 months prior, at which time the patient presented for vomiting. CT imaging was consistent with a lower third oesophageal injury. The patient was managed conservatively with 3 days of piperacillin-tazobactam and kept 1 day *nil per os* (NPO) with advancement of the diet over 3 days. The history was also notable for the patient being an occasional user of alcohol, although they had drunk 2–3 alcoholic

beverages immediately prior to the onset of their symptoms. Notably, they denied fevers, chills, lightheadedness, dizziness, or chest pain. Their presenting vitals were a temperature of 98.6 °F, blood pressure of 124/61 mmHg, pulse of 85 beats per minute, respiratory rate of 18 breaths per minute, and oxygen saturation that was 100% on room air. The physical examination was notable for a well-appearing, alert, and oriented adult in no acute distress, and a well-healed abdominal surgical scar. No chest wall crepitus, Hamman's sign, or abdominal tenderness were appreciated, and more generally no focal findings on exam were found. Laboratory results were notable for a white blood cell count of $16.1 \times 10^3/\mu\text{L}$ (normal range: 4×10^3 – $11 \times 10^3/\mu\text{L}$) with a differential of 87.1% neutrophils, 5.0% lymphocytes, 7.8% monocytes, 0.0% eosinophils, and 0.1% basophils, serum creatinine of 2.0 mg/dL (baseline: 0.8–1.0 mg/dL), blood urea nitrogen 37 mg/dL (normal range: 6–20 mg/dL), and serum magnesium of 1.5 mg/dL (normal range: 1.6–2.5 mg/dL). Serum sodium was slightly elevated from baseline, and both lactic acid and procalcitonin were within normal limits. CT scans of the chest, abdomen, and pelvis (Figure 1) demonstrated extensive gas tracking along the bilateral neck, chest wall, and all compartments of the mediastinum, but most prominently in the region of the lower third of the oesophagus above the level of the diaphragm. No overt oesophageal wall abnormality was detected. The CT imaging further demonstrated that the central tracheobronchial tree was patent and there was no direct evidence of alveolar rupture or gas traveling along the bronchovesicular interstitial sheaths. Cardiothoracic Surgery

and Gastroenterology services were consulted by the emergency department and neither recommended interventions. Specifically, the Gastroenterology service deferred upper endoscopy due to concern that the required air insufflation could worsen a perforation. Gastrografin oesophagogram and subsequent barium oesophagogram (Figure 2) showed subcutaneous emphysema of the bilateral neck and superior chest wall, but no evidence of oesophageal contrast extravasation, intramural tracking, or penetration. The patient was administered 2 L of lactated ringers, 4 mg of ondansetron, 2 g of magnesium sulfate, and started on piperacillin-tazobactam. Within 2–3 hours following these interventions, the patient reported complete resolution of symptoms. The patient was admitted to the Internal Medicine service for further care. The patient's laboratory abnormalities resolved with the following set of laboratory studies the subsequent day.

The patient met the Cameron criteria for conservative management of BS, which was discussed with the patient who agreed to non-procedural management.⁷ The patient was kept NPO for 7 days. Nasogastric and nasojejunal tubes were considered, and thought to be too risky in the setting of the recent oesophageal perforation. Interventional Radiology was consulted for placement of a peripherally-inserted central catheter, after which total parenteral nutrition was initiated. Additionally, the patient received pantoprazole 40 mg intravenously twice a day and a 7 day course of piperacillin-tazobactam.

After 7 days, total parental nutrition was discontinued and the patient was begun on a diet, starting with a clear liquids and then progressed to a regular diet, which was well tolerated. The patient was discharged from the hospital on Day 9. The patient did not experience any complications during the hospital course.

DISCUSSION

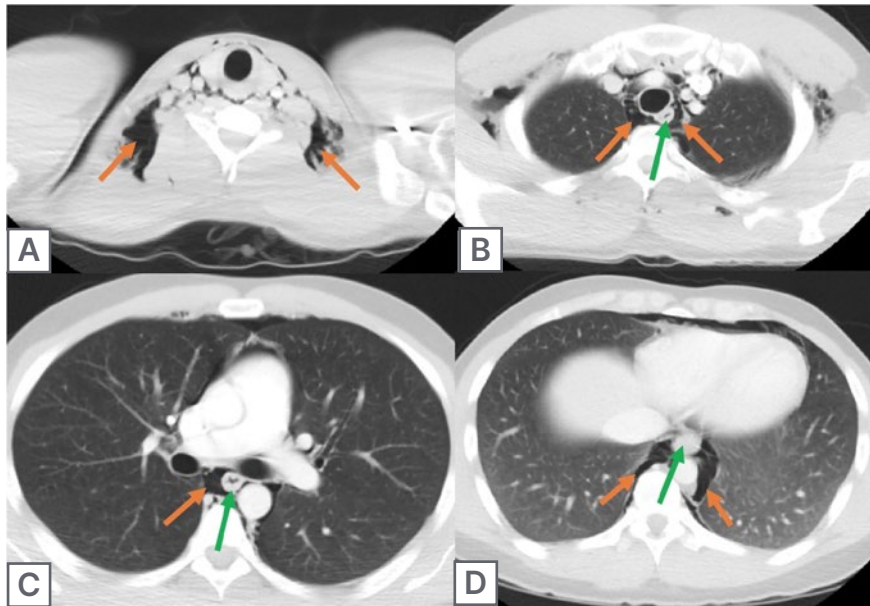
The diagnosis of BS was made in the emergency department based on the patient's history of BS, the presenting symptom of vomiting, and CT findings of extensive mediastinal air tracking that was most pronounced around the lower third of the oesophagus. These findings were collectively

highly suggestive of an oesophageal perforation.⁸ Although a site of oesophageal perforation was not confirmed with radiologic studies, CT imaging of the chest is not a sensitive modality to detect oesophageal perforation, with a 17% detection rate among patients with confirmed BS.⁸ In addition, there are other descriptions of CT imaging not identifying oesophageal pathology in BS patients.^{8–10} While contrast oesophagograms have a much higher sensitivity for oesophageal perforation than chest CT, the false negative rate is still as high as 10%.¹¹ There are several reported cases of contrast oesophagograms using both gastrografin and barium in which the patient's oesophageal perforation was not detected in BS patients.^{9–11} The patient reported vomiting, and radiologic studies revealed subcutaneous emphysema, which are two of the three components of Mackler's triad, but lacked the third Mackler triad component of chest pain.¹² While Mackler's triad when present can be suggestive of BS, it is only present in 5% of patients with BS.¹²

Since the diagnosis of BS was not endoscopically confirmed due to a decision that the risks of the procedure outweighed the benefits, alveolar rupture remains on the differential. The most common causes of non-traumatic pneumomediastinum that have been observed to occur in the setting of vomiting are alveolar rupture and oesophageal perforation.¹³ Alveolar rupture can be identified with the Macklin effect, which is CT imaging that demonstrates gas travelling centrally along the perivascular and peribronchial interstitial sheaths into the mediastinum.¹⁴ The Macklin effect is found in 89–100% of alveolar rupture cases, making this a less likely diagnosis in this patient, since these findings were absent in this case.¹⁴ Other causes of pneumomediastinum include tracheobronchial injury, head and neck trauma, and abdominal injury, but the underlying conditions that would result in these aetiologies were not present in this patient.¹³

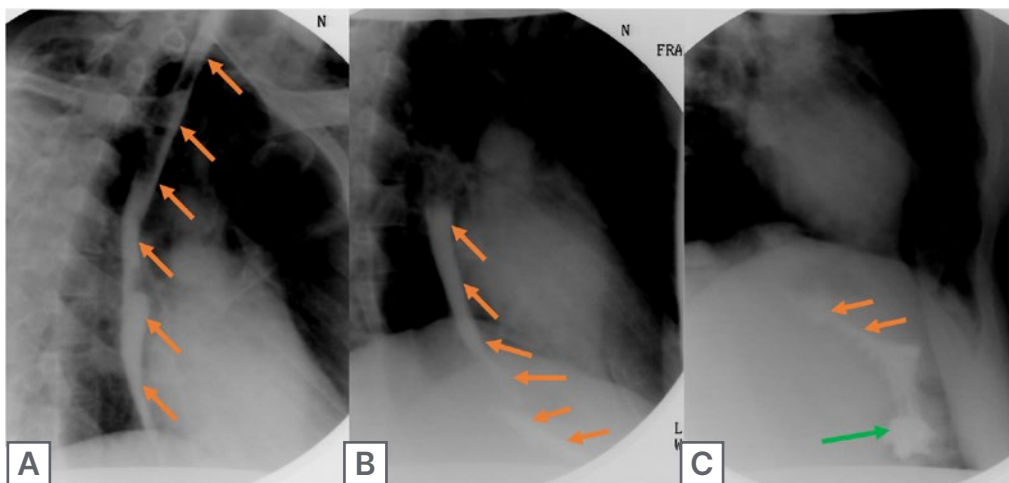
The decision to triage this patient to the Medicine team for conservative management initially triggered a discussion whether such a plan of care was sufficient. It was ultimately decided that the decision to conservatively manage the patient was appropriate, based on guidelines outlined in Cameron et al.,⁷ given that the patient had minimal symptoms, no

Figure 1: CT scans of the chest, abdomen, and pelvis demonstrated gas tracking from the neck (A) through the areas surrounding the first (B), second (C), and third (D) parts of the oesophagus, with more pronounced air tracking around the third part.



No oesophageal wall abnormality was appreciated. The central tracheobronchial tree was patent and there was no evidence of alveolar rupture or gas moving along the bronchovesicular interstitial sheaths. The orange arrows indicate the gas tracking and the green arrows indicate the oesophagus.

Figure 2



Barium esophagogram showed barium contrast proceeding from the upper part into the lower two parts of the oesophagus in A. In B, the barium is better visualised exiting the middle part and filling the lower part of the oesophagus. Subsequently, in C, the barium is seen exiting the third part of the oesophagus and moving past the gastroesophageal junction into the stomach. No contrast extravasation, intramural tracking, or penetration was detected. The orange arrows indicate the barium within the oesophagus and the green arrow indicates the location of the stomach.

evidence of neoplastic tissue, no evidence of obstruction, no detected intramural or transmural perforation, no pleural space contamination, a swallow study that showed no active leakage of contrast, and was at a hospital that has readily available cardiothoracic surgeons and access to a repeat contrast study at any time of the day.^{7,15} Conservatively managed patients that fit these criteria face an average mortality of 17% (range: 0–33%), comparable to the average mortality of 12% (range: 0–31%) for primary oesophageal repair.¹⁶ The current literature primarily recommends surgical management of patients with BS.¹⁷ However, there is a small but growing number of reports that describe situations in which conservative treatment has been used successfully. Between the years 1979–2021, there have been 95 reported cases of BS in which the patient survived the episode with completely conservative treatment without the need for any type of an invasive intervention.^{6,7,10,18–48} Identifying those who are appropriate for conservative management of BS could ultimately benefit such patients. So far, medically managed BS has been associated with significantly shorter hospitalisations and a lower cost of treatment.⁴⁹

Following the decision to manage conservatively, constructing a treatment plan proved difficult, given the lack of formal guidelines on the subject and the subsequent variation in approaches to conservatively managed BS. Most of the available literature suggested at least a week of strict NPO, possible parenteral nutrition, 1–2 weeks of broad-spectrum antibiotics, and acid suppressive therapy.^{7,24,50,51} However, there was conflicting information regarding NPO duration, acid suppressive regimens, the use of parental nutrition, and the choice of antibiotic agent, as well as the role of chest tubes and endoscopy.

A recurrence of BS is extremely rare, with only 12 prior confirmed reports identified among adult patients as of December 2021.^{46,52–55} Among all 13 cases of recurrent BS in adult patients, there are several aspects of this case that make it unique. This is one of only two identified cases of recurrent BS among adult patients in which both occurrences were managed conservatively.^{44,45} Between these two cases, this case stands out because the episodes of BS were separated by 9 months, as compared with the other case in which the reoccurrence happened within several weeks.^{44,45} In addition, between these two cases, this is the first in which the patient denies having regular alcohol intake or other chronic risk factors.

While informal criteria exist to help guide clinicians to which BS patients may be appropriate candidates for conservative management, there is a lack of high-quality studies supporting these criteria. In addition, while there are certain aspects of conservative BS management that appeared frequently in prior case reports, ideal management of recurrent BS remains unclear based on the existing literature. The components of conservative management have varied significantly between different BS cases. This is likely due to the infrequency of BS. A prospective study would be an ideal next step to explore optimal management; however, this would likely be difficult to arrange due to the rarity of a patient appropriate for conservative BS management. For now, through continued reporting of conservatively managed BS cases, the variation of therapeutic approaches and their subsequent outcomes can be further explored, with the ultimate goal of identifying and standardising the optimal treatment regimen.

References


1. Tzeng C-H et al. Challenges in the diagnosis of Boerhaave syndrome: a case report. *Medicine (Baltimore)*. 2020;99(2):e18765.
2. Tuñón C et al. Endoluminal vacuum therapy in the management of an esophago-pleural fistula as a complication of Boerhaave syndrome in a patient with eosinophilic esophagitis. *BMC Gastroenterol*. 2021;21(1):484.
3. Turner AR, Turner SD, Boerhaave Syndrome (2021) Treasure Island: StatPearls Publishing.
4. Goel R et al. Boerhaave syndrome: an unusual cause of bilateral exudative pleural effusion. *Adv Resp Med*. 2021;89(3):339–40.
5. Wang CT et al. Tension hydropneumothorax in a Boerhaave syndrome patient: a case report. *World J Emerg Med*. 2021;12(3):235–7.
6. Tellechea JI et al. Role of endoscopy in the management of Boerhaave syndrome. *Clin Endosc*. 2018;51(2):186–91.
7. Cameron JL et al. Selective nonoperative management of contained intrathoracic esophageal disruptions. *Ann Thorac Surg*. 1979;27(5):404–8.
8. White CS et al. Esophageal perforation: CT findings. *AJR Am J Roentgenol*. 1993;160(4):767–70.
9. O’Kelly F et al. An unusual

- presentation of Boerhaave syndrome: a case report. *Cases Journal*. 2009;2(6):1-3.
10. Kyriakides J, Stackhouse A. Vomiting-induced pneumomediastinum as a result of recurrent Boerhaave's syndrome. *J Surg Case Rep*. 2020;2020(5):rjaa102.
 11. Bladergroen MR et al. Diagnosis and recommended management of esophageal perforation and rupture. *Ann Thorac Surg*. 1986;42(3):235-9.
 12. Lieu MT et al. Tension hydropneumothorax as the initial presentation of Boerhaave syndrome. *Respir Med Case Rep*. 2018;25:100-3.
 13. Bejvan SM, Godwin JD. Pneumomediastinum: old signs and new signs. *AJR Am J Roentgenol*. 1996;166(5):1041-8.
 14. Chassagnon G et al. Spontaneous pneumomediastinum due to the Macklin effect: less is more. *Intern Emerg Med*. 2015;10(6):759-61.
 15. García-Moreno V et al. Treatment of esophageal perforation: a review of our experience at a tertiary referral hospital spanning the past 19 years. *Rev Gastroenterol Mex (Engl Ed)*. 2021;S2255-34X(21)00129-8. [Epub ahead of print].
 16. Brinster CJ et al. Evolving options in the management of esophageal perforation. *Ann Thorac Surg*. 2004;77(4):1475-83.
 17. Hayakawa S et al. Suitable diagnosis and treatment of esophageal ruptures in cases of non-Boerhaave syndrome: a comparison with Boerhaave syndrome. *J Investigat Med High Impact Case Rep*. 2021;DOI:10.1177/23247096211014683.
 18. Truyens M et al. Boerhaave's syndrome: successful conservative treatment in two patients. *Acta Gastroenterol Belg*. 2020;83(4):654-6.
 19. Yuichiro H et al. Boerhaave syndrome due to excessive alcohol consumption: two case reports. *Int J Emerg Med*. 2020;13(1):56.
 20. Barnett D et al. Renal colic causing Boerhaave syndrome. *Transl Androl Urol*. 2020;9(2):828-30.
 21. Kuwano H et al. Pathophysiology of vomiting and esophageal perforation in Boerhaave's syndrome. *Dig Dis Sci*. 2020;65(11):3253-9.
 22. Ioannidis O et al. Conservative treatment of Boerhaave's syndrome in an octogenarian complicated with late distal esophageal stenosis and successfully treated by stent placement. *Cir Cir*. 2021;89(S1):23-7.
 23. Ivey TD et al. Boerhaave syndrome: successful conservative management in three patients with late presentation. *Am J Surg*. 1981;141(5):531-3.
 24. Anwuzia-Iwegbu C et al. Against all odds. Conservative management of Boerhaave's syndrome. *BMJ Case Rep*. 2014;DOI:10.1136/bcr-2013-200485.
 25. Vickers NJ. Animal communication: when I'm calling you, will you answer too? *Curr Biol*. 2017;27(14):R713-5.
 26. Michel L et al. Operative and nonoperative management of esophageal perforations. *Ann Surg*. 1981;194(1):57-63.
 27. Schmidt S et al. Management of esophageal perforations. *Surg Endosc*. 2010;24:2809-13.
 28. Ochiai T et al. Treatment strategy for Boerhaave's syndrome. *Dis Esophagus*. 2004;17(1):98-103.
 29. Smyth A, Wastell C. Spontaneous rupture of the oesophagus (Boerhaave's syndrome): delayed diagnosis and successful conservative management. *J R Soc Med*. 1989;82(8):498.
 30. Wang Y et al. Our experience on management of Boerhaave's syndrome with late presentation. *Dis Esophagus*. 2009;22(1):62-7.
 31. Matsuda A et al. Boerhaave syndrome treated conservatively following early endoscopic diagnosis: a case report. *J Nippon Med Sc*. 2006;73(6):341-5.
 32. del Olmo AG et al. Spontaneous intramural oesophageal perforation. *Endoscopy*. 1985;17(2):76-7.
 33. Mittal S et al. Spontaneous perforation of cervical oesophagus: a rare variant of Boerhaave's syndrome. *J Laryn Otol*. 2009;123(12):1378-80.
 34. Walker W et al. Diagnosis and management of spontaneous transmural rupture of the oesophagus (Boerhaave's syndrome). *Br J Surg*. 1985;72(3):204-7.
 35. Salim AS. Jejunostomy feeding for the conservative management of spontaneous rupture of the oesophagus. *Br J Clin Pract*. 1991;45(1):37-40.
 36. Petousis S et al. High mortality rate of oesophageal perforation is associated with delayed hospital admission: a prospective observational case series study. *Acta Gastroenterol Belg*. 2020;83(1):11-4.
 37. Delamarre J et al. [Spontaneous contained perforation of a hiatal hernia. A new equivalent of Boerhaave's syndrome.] *Gastroenterol Clin Biol*. 1989;13(8-9):734-7. (In French).
 38. Asahina A et al. [Six cases of spontaneous pneumomediastinum.] *Kyobu Geka*. 2009;62(12):1032-4. (In Japanese).
 39. Lindenmann J et al. Management of esophageal perforation in 120 consecutive patients: clinical impact of a structured treatment algorithm. *J Gastrointest Surg*. 2013;17(6):1036-43.
 40. Shaker H et al. The influence of the 'golden 24-h rule' on the prognosis of oesophageal perforation in the modern era. *Eur J Cardiothorac Surg*. 2010;38(2):216-22.
 41. Kallis P et al. Spontaneous rupture of the oesophagus (Boerhaave's syndrome): conservative versus surgical management. *J R Soc Med*. 1991;84(11):690.
 42. Port JL et al. Thoracic esophageal perforations: a decade of experience. *Ann Thorac Surg*. 2003;75(4):1071-4.
 43. Causbie JM et al. S3566 Impending Boerhaave: recurrent esophageal tear after prior perforation. *Am J Gastroenterol*. 2021;116:S1463.
 44. Nakata Y et al. A case of spontaneous esophageal rupture which relapsed after conservative therapy. *Jpn Gastroenterol Surg*. 2001;34:91-4.
 45. Oderuth E et al. Medical school finals, nerves and vomiting: medical student survives Boerhaave's syndrome with recurrence one week after initial presentation. *IJCRI*. 2014;5(3):202-6.
 46. Naitoh H et al. Recurrent, spontaneous esophageal ruptures associated with antiphospholipid antibody syndrome: report of a case. *Int Surg*. 2014;99(6):842-5.
 47. Khan OA et al. Recurrent spontaneous esophageal rupture. *Eur J Cardiothorac Surg*. 2005;28(1):178-9.
 48. Saha S et al. Recurrent spontaneous perforation of the

- midesophagus. 1979;72(8):1028-9.
49. Shaffer Jr HA et al. Esophageal perforation: a reassessment of the criteria for choosing medical or surgical therapy. *Arch Intern Med.* 1992;152(4):757-61.
 50. Aloreidi K et al. Non-surgical management of Boerhaave's syndrome: a case series study and review of the literature. *Endosc Int Open.* 2018;6(1):E92-7.
 51. Triadafilopoulos G. Boerhaave syndrome: effort rupture of the esophagus. 2022. Available at: <https://www.uptodate.com/contents/boerhaave-syndrome-effort-rupture-of-the-esophagus>. Last accessed: 5 August 2021.
 52. Zeyara A et al. Third time recurrent Boerhaave's syndrome: a case report. *J Med Case Rep.* 2021;15(1):1-6.
 53. Wang SC, Scott Jr WW. Recurrent spontaneous esophageal rupture managed with esophageal stenting. *Ann Thorac Surg.* 2016;102(1):e5-6.
 54. Rokicki M et al. Boerhaave syndrome - over 290 years of surgical experiences. Can the disorder recur? *Pol Przegl Chir.* 2019;91(3):27-9.
 55. Barakat MT et al. (Re)building the wall: recurrent Boerhaave syndrome managed by over-the-scope clip and covered metallic stent placement. *Dig Dis Sci.* 2018;63(5):1139-42.

FOR REPRINT QUERIES PLEASE CONTACT: INFO@EMJREVIEWS.COM

Retrorectal Teratoma: A Case Report



Authors:	Melissa Kyriakos Saad, ¹ Wissam Dib, ^{2,4} George El Hachem, ^{3,4} *Elias Saikaly ^{2,4}
	<ol style="list-style-type: none"> 1. Institut Bergonié, Department of Surgical Oncology, Bordeaux, France 2. Department of General Surgery, Saint George Hospital University Medical Center, Beirut, Lebanon 3. Department of Oncology, Saint George Hospital University Medical Center, Beirut, Lebanon 4. University of Balamand, Beirut, Lebanon *Correspondence to dreliassaikaly@gmail.com
Disclosure:	The authors have declared no conflicts of interest.
Acknowledgements:	Written informed consent was obtained from the patient to publish this case report along with all associated radiologic and intraoperative images.
Received:	22.03.22
Accepted:	31.05.22
Keywords:	Kraske procedure, retrorectal space, retrorectal teratoma, teratoma.
Citation:	EMJ Gastroenterol. 2022; DOI/10.33590/emjgastroenterol/22-00022. https://doi.org/10.33590/emjgastroenterol/22-00022 .

Abstract

Retrorectal neoplasms is a rare, heterogeneous group of neoplasms developing in the retrorectal space. Its rarity makes its management a challenge to the unaware. Here, the authors present a case of 37-year-old female patient presenting with anal pain, diagnosed with retrorectal teratoma, which was managed surgically by posterior approach, the Kraske procedure.

Key Points

1. Retrorectal neoplasms are a rare group of heterogeneous neoplasms that presents a challenge to unaware healthcare professionals, especially as there is limited literature on the condition.
2. The authors detailed the importance of a digital rectal examination on patients with a retrorectal teratoma, highlighting how it allowed physicians to study the mass during surgical planning.
3. Full excision is the aim when surgically removing retrorectal teratomas, with a 0% chance of recurrence to be expected if a benign tumour is completely excised.

INTRODUCTION

Retrorectal neoplasms is a rare, heterogeneous group of neoplasms that develops in a potential space known as the presacral or retrorectal space. Anatomically, this potential space is enclosed posteriorly by the sacrum, anteriorly by the rectum, superiorly by the peritoneal reflection, and inferiorly by the rectosacral fascia. Although the supraleveators and the deep postanal space is not included in this space, lesions occurring within these areas are still generally considered as retrorectal or presacral neoplasms. The estimated incidence of admissions diagnosed by retrorectal tumours is 1 out of 40,000 admissions.^{1,2} Due to the rarity, management of retrorectal neoplasms poses a challenge to the unaware, manifested by difficulty to diagnose by physicians, difficulty to characterise by radiologists, and a challenge to manage by surgeons. Here, the authors present a case of 37-year-old female patient presenting with pelvic heaviness and dull anal pain, diagnosed with retrorectal neoplas that was resected by posterior approach, with histologic studies showing a mature teratoma.

CASE PRESENTATION

The authors present a case of 37-year-old female patient, previously healthy with no past medical or surgical history, presenting with the complaint of pelvic heaviness and continuous dull anal pain. The patient reported that pain worsened with prolonged standing and towards the end of the day. They denied any anal discharge, blood per rectum, painful defecation, and feeling of incomplete rectal emptiness. There was no family history of malignancy. On physical exam, their vital signs were within normal limits, blood pressure of 120/80 mmHg, and heart rate of 73 beats/min. Neurologic exam was normal, and digital rectal exam revealed a smooth rectal mucosa with a posterior bulge felt displacing the posterior rectal wall anteriorly.

The mass was palpable, starting 1 cm from the anal verge, with its distal end at around 6 cm from the anal verge. Furthermore, a rigid sigmoidoscopy was completed, showing a bulge in the posterior rectal wall with intact mucosa. Consequently, the patient was scheduled for pelvic CT scan, with intravenous contrast

showing a multilobulated cystic mass with several locules and rim enhancement measuring 6 cm in craniocaudal dimension and 3.5 cm in axial diameter (Figure 1). This mass displaced the rectal wall anteriorly and was located below the level of S3 vertebra. Consequently, the patient was scheduled for the excision of retrorectal tumour by posterior approach, the Kraske procedure. In the operating theatre, the patient was put in prone jackknife position, where a paramedian incision was made; coccygectomy was done for better exposure. Dissection continued until the tumour was reached (Figure 2). During dissection, repetitive digital rectal examinations were done, which aids in better surgical exposure and avoids injury to the rectum. Complete excision of the tumour was carried out (Figure 3). The patient had an uneventful hospital stay, and was discharged on Day 1 after surgery. The final histopathology showed mature teratoma with stratified squamous epithelium and regular pseudostratified ciliated respiratory-type epithelium.

DISCUSSION

Teratomas have been reported to occur in different anatomical locations, such as the head and neck region, mediastinum, intraperitoneal or retroperitoneal, and in the retrorectal or presacral space. In fact, 11% of retroperitoneal tumours are teratomas and tend to occur in the paediatric age group.^{3,4}

Due to the rarity, retrorectal teratomas present a challenge to the unaware, with the medical literature being limited to case reports and only a scarce large case series. Review of the medical literature revealed a total of 88 reported cases.⁵⁻⁷ Teratomas are considered a true neoplasm, and they include the three germ layers: epithelium of the gastrointestinal tract, respiratory tract, and nervous system. Teratomas can be solid, cystic, and frequently contain both components. Furthermore, teratomas have the potential to undergo malignant transformation to squamous cell carcinoma or rhabdomyosarcoma.⁸ In fact, the risk of malignant degeneration in an adult population reaches 40–50%, and even higher with incomplete surgical resection.^{9,10} Furthermore, the tendency of these lesion

Figure 1: Pelvic CT scan with intravenous contrast showing a multilobulated cystic mass with several locules and rim enhancement.

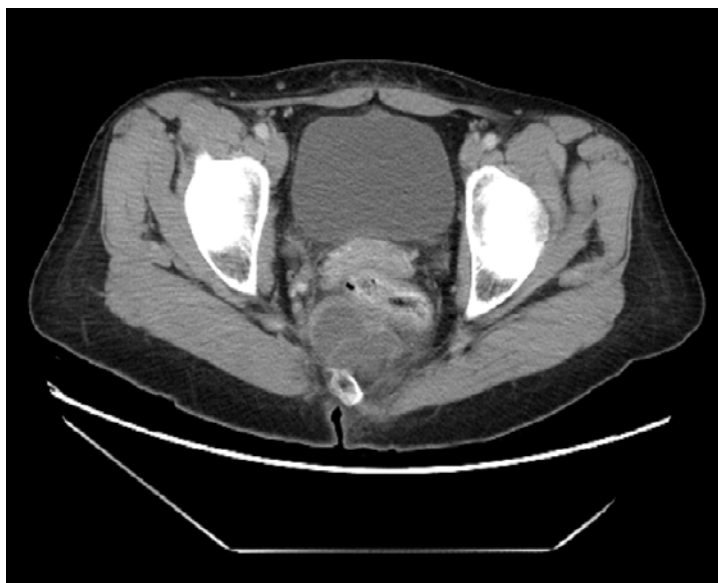
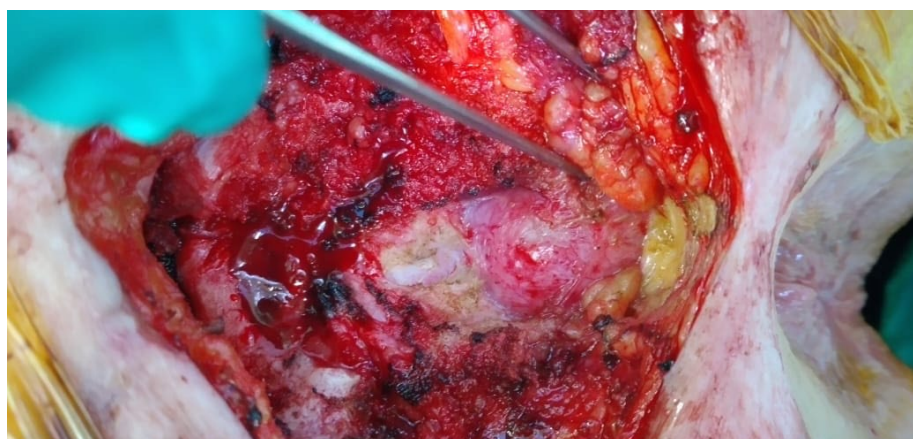

Figure 2: Retrorectal tumour intraoperative.

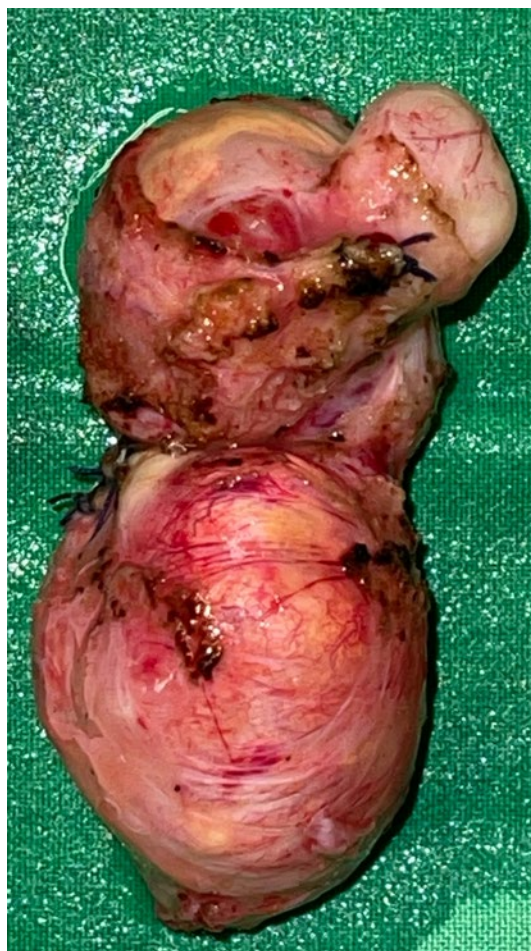


to adhere to the coccyx mandates at some instances an en bloc coccygectomy.⁸

Retrorectal teratomas are characterised by their slowly progressive nature. They are frequently incidentally detected during a pelvic or rectal exam from one side or by imaging while investigating another complaint from the other side. Symptoms attributed to retrorectal teratomas are due to the mass effect posed by the tumour. This mass effect is manifested by compression or consequent invasion to adjacent structures, including the pelvic viscera and nerves.^{8,11}

Having said this, patients present with a wide range of symptoms depending on the location of the tumour from one side and the invasion of nearby structures from the other side. These symptoms include low back pain, pelvic heaviness, anal pain, and constipation. Furthermore, if invasion of pelvic nerves happen, rectal incontinence, urinary incontinence, and sexual dysfunction may occur. Moreover, patients may present with urinary tract obstruction.¹² On the other end, patients may present with septic complications, including chemical peritonitis due to tumour rupture or abscess formation.¹³⁻¹⁵ Patients also may present with

Figure 3: Complete excision of the tumour.



chemical peritonitis related to dermoid rupture.^{4,8} Chronic infection of dermoid cysts is a known complication with associated local abscess and fistulous tract formation to adjacent structures, including the skin.^{12,15}

From here, a detailed physical exam, including a neurologic exam to assess for neurologic deficiency, and a digital rectal examination is vital and usually demonstrates an intact rectal mucosa with a posterior extra rectal bulge displacing the posterior rectal wall anteriorly.¹¹ The importance of digital rectal examination is evident for surgical planning. For instance, a digital rectal exam allows the physician to study the extent of fixation of the mass by palpation and its relation to nearby structures. Furthermore, it allows the examiner to realise the proximal and distal level of the tumour, which aids in choosing the best surgical approach.

Physical exam in such patients is accompanied by a rigid or flexible sigmoidoscopy, which can be performed to ensure the integrity of the rectal mucosa and the absence of anterior trans mural invasion by the tumour. On the other hand, it is believed that the best imaging modalities to diagnose, characterise, and aid in planning for surgical resection are the CT scan and MRI. These modalities allow the study of the anatomical location of the tumour, and hence determine the surgical approach in conjunction with physical exam. Having said this, the final diagnosis cannot be achieved unless surgical resection is done.^{3,16}

From here, the cornerstone in treatment of retrorectal teratomas is complete surgical resection. The best surgical approach is directly related to the anatomical location of the tumour, the nature, and the size, as well as the invasion

of adjacent structures such as the sacrum, the pelvic sidewalls, the rectum, and the anal canal.¹⁷ The three most commonly described surgical approaches for resection of retrorectal tumours in medical literature are the anterior approach, either open or laparoscopic, the combined abdominoperineal approach, and the perineal or posterior approach. The main determinant of the surgical approach utilised, along with surgeon preference, is the relation of the tumour to the S3 vertebra. In general, tumours located above the level of S3 will necessitate an anterior or combined approach, whereas lesions located below the level of S3 are excised utilising the posterior approach. Irrespective of the surgical approach utilised for resection, complete excision is the aim. In fact studies have demonstrated a recurrence rate ranging between 0–15% of cases.^{18,19} However, a recurrence rate of 0% is expected with a complete excision of a benign tumour. This is reinforced by a study published by Glasgow et al.²⁰ demonstrating that

the recurrence rate in 22-month follow-up was 0% in completely excised tumours, with a 5-year survival rate of 100%.²¹ In the authors' case, the tumour was located inferior to the S3 level, hence a posterior approach was chosen.

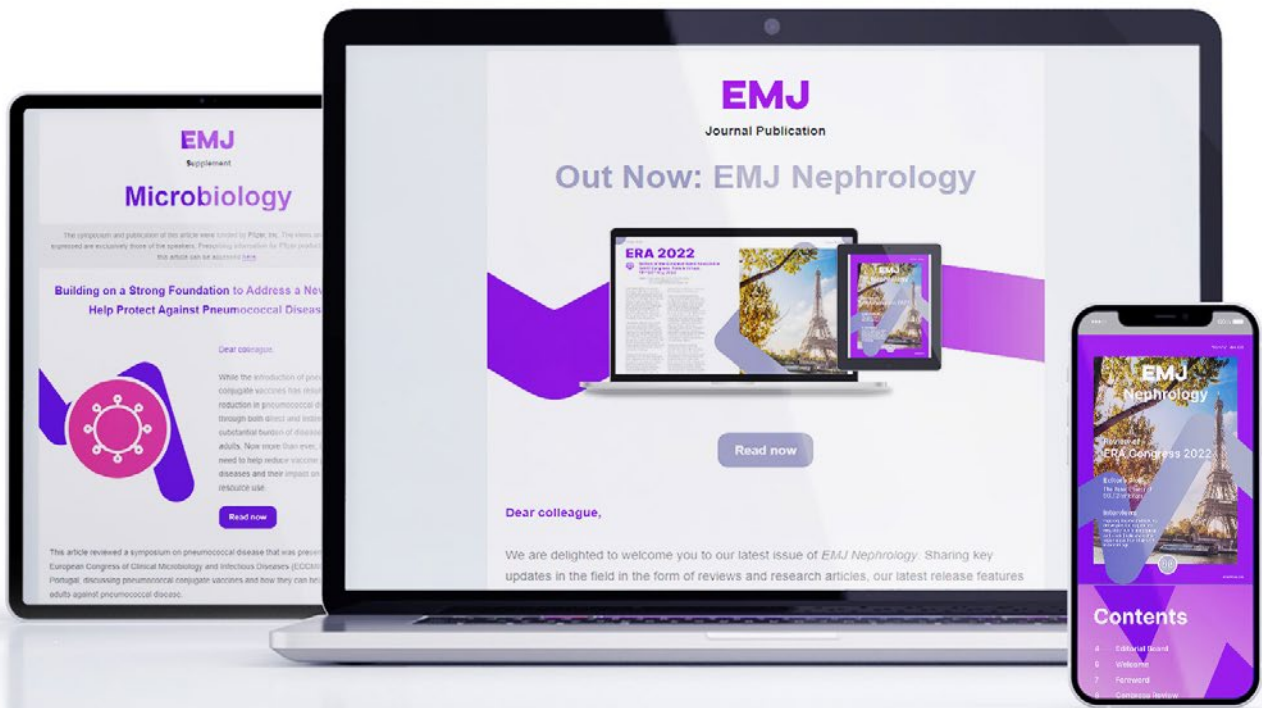CONCLUSION

In conclusion, retrorectal or presacral teratomas are a rare condition with a wide and nonspecific clinical presentation. Such lesions are a challenge to the unaware and are often diagnosed late. Radiologic assessment is a key component in surgical planning that is the cornerstone in treatment of these neoplasms. Treatment should be planned in collaboration between radiologists and surgeons with expertise in pelvic and cancer surgery in order to obtain the best possible outcomes with the lowest recurrence rate, as well as the lowest morbidity and mortality.

References

- Jao SW et al. Retrorectal tumors. Mayo Clinic experience, 1960-1979. *Dis Colon Rectum*. 1985;28(9):644-52.
- Dozois EJ et al. "Presacral tumors," Wolff BG et al. (eds.), *The ASCRS Textbook of Colon and Rectal Surgery* (2007), New York: Springer Science Business Media, pp.501-14.
- Tiu A et al. Primary retroperitoneal mature cystic teratoma (dermoid cyst) in a 51-year-old male: case report and historical literature review. *SAGE Open Med Case Rep*. 2017;5:2050313X17700745.
- Rajiah P et al. Imaging of uncommon retroperitoneal masses. *Radiographics*. 2011;31(4):949-76.
- Head HD et al. Presacral teratoma in the adult. *Am Surg*. 1975;41(4):240-8.
- Ng EW et al. Sacrococcygeal teratoma in adults: case reports and a review of the literature. *Cancer*. 1999;86(7):1198-202.
- Bull J Jr et al. Mature presacral teratoma in an adult male: a case report. *Am Surg*. 1999;65(6):586-91.
- Gordon PH, "Retrorectal tumors," Gordon PH, Nivatvongs S (eds.), *Principles and Practice of Surgery for the Colon, Rectum and Anus* (1999), St. Louis: Quality Medical Publishing, pp.427-45.
- Waldhausen JA et al. Sacrococcygeal teratomas. *Surgery*. 1963;54:933-49.
- Hickey RC, Martin RG. Sacrococcygeal teratomas. *Ann N Y Acad Sci*. 1964;114:951-7.
- Young-Fadok TM, Dozois EJ, "Retrorectal tumors," Yeo CJ (ed.), *Shackelford's Surgery of the Alimentary Tract* (2007), Philadelphia: Saunders, pp.2299-311.
- Alhumayed M, Liau J. Extensive mature cystic teratoma in the pelvis of an adult male patient mimicking a prostatic abscess. *Radiol Case Rep*. 2021;16(6):1343-7.
- Gatcombe HG et al. Primary retroperitoneal teratomas: a review of the literature. *J Surg Oncol*. 2004;86(2):107-13.
- Dahan H et al. Retrorectal developmental cysts in adults: clinical and radiologic-histopathologic review, differential diagnosis, and treatment. *Radiographics*. 2001;21(3):575-84.
- Erkan N et al. Retrorectal dermoid cyst. *Visc Med*. 2006;22(1):55-7.
- Chalhoub K et al. Primary mature cystic teratoma compressing the prostate in a 28-year-old male: a case report and literature review. *Urol Case Rep*. 2019;2019:8970172.
- Woodfield JC et al. Algorithms for the surgical management of retrorectal tumours. *Br J Surg*. 2008;95(2):214-21.
- Dozois RD, Chiu LK, "Retrorectal tumors," Nicholls RJ, Dozois RR (eds.), *Surgery of the Colon and Rectum* (1997), New York: Churchill Livingstone, pp. 533-45.
- Stener B. Resection of the sacrum for tumors. *Chir Organi Mov*. 1990;75(Suppl 1):108-10.
- Glasgow SC et al. Retrorectal tumors: a diagnostic and therapeutic challenge. *Dis Colon Rectum*. 2005;48(8):1581-7.
- Mathur P et al. Giant primary retroperitoneal teratoma in an adult: a case report. *Case Rep Med*. 2010;2010:650424.

FOR REPRINT QUERIES PLEASE CONTACT: INFO@EMJREVIEWS.COM



Receive our free newsletters and alerts

Get the latest updates on all our upcoming journals and receive first-class insights into ground-breaking news and advancements in medicine across multiple therapeutic areas.

[Join our mailing list](#)

www.emjreviews.com

EMJ