



aesthetic medicine

**Official Journal of the International
Union of Aesthetic Medicine – UIME**



Official UIME English Language Journal of:

Aesthetic and Anti-Aging Medicine Society of South Africa
Aesthetics Medical Society of Uruguay
Aesthetic Medicine Society of Venezuela
Algerian Society of Aesthetic Medicine
American Academy of Aesthetic Medicine
Argentine Society of Aesthetic Medicine
Canadian Association of Aesthetic Medicine
Colombian Association of Aesthetic Medicine
Ecuadorian Society of Aesthetic Medicine
French Society of Aesthetic Medicine
Georgian Society of Aesthetic Medicine
Italian Society of Aesthetic Medicine
Kazakhstan Association of Aesthetic Medicine and Plastic Surgery
Korean Academy of Aesthetic Medicine
Mexican Scientific Society of Aesthetic Medicine
Moroccan Society of Aesthetic Medicine
Polish Society of Aesthetic and Anti-Aging Medicine of Polish Medical Society
Romanian Society for Aesthetic Medicine and Dermatologic Surgery
Society of Aesthetic Medicine in Turkey
Spanish Society of Aesthetic Medicine
Swiss Society of Aesthetic Medicine
Ukrainian Society of Aesthetic Medicine



Official Journal of the International Union of Aesthetic Medicine - UIME

Editor-in-chief

Francesco Romanelli
Rome, Italy

Editors

Emanuele Bartoletti, Italy
Alfonso Carvajal Gomez, Colombia
Annarosa Catizzzone, Italy
Loredana Cavalieri, Italy
Nadia Fraone, Italy
Fernando García Manforte, Spain
Mohamed Oughanem, Algeria
Raul Pinto, Argentina
Sandra Ramirez Naranjo, Colombia
Ferdinando Terranova, Italy
Dorota Wydro, Poland
Jan-Bong Yun, Korea

Executive Editors

Emanuele Bartoletti, Italy
Annarosa Catizzzone, Italy
Loredana Cavalieri, Italy
Nadia Fraone, Italy
Giovanni Messina, Italy
Hernan Pinto, Argentina
Raffaele Rauso, Italy
Ferdinando Terranova, Italy

Managing Editor

Emanuele Bartoletti, Italy

Associate Editors

Patricia Frisari, Argentina - Tulegenova Gulnur, Kazakhstan - Andrzej Ignaciuk, Poland - John Kim, California (USA) - Alexander Kutubidze, Georgia - Omnia Latif, New Jersey (USA) - Leonor Lemmo, Venezuela - Mihaela Leventer, Romania - Alp Mamak, Turkey - Xavier Martin, Swiss - Gilda Marzullo, Chile - David Melamed, California (USA) - Farid-Salim Oughanem, Algeria - Olga Panova, Russia - Susan Roberts, Canada - Pilar Rodrigo Anoro, Spain - Ismael Terzano, Uruguay - Viveka Tinoco Kirby, Ecuador - Sonia Lamari, Algeria.

Statistical Editor

Patrizio Pasqualetti, Italy

Editorial Board

Gladys Arroyave Estrada, Colombia - Ahmed Bourra, Morocco - Elma Bulnar, Croatia - José Cabo Soler, Spain - Alfonso Carvajal Gómez, Colombia - Andrés Eliú Castell Rodríguez, Mexico - Eduardo Civila, Uruguay - Michel Delune, California (USA) - Fernando Echeverria, Chile - Alberto Elbaum, Uruguay - Victor Garcia-Guevara, Venezuela - Jean Hebrant, Belgium - Andrej Ignaciuk, Poland - Alexander Katsitadze, Georgia - Serge Lê Huu, Swiss - Jean-Jacques Legrand, France - Mihaela Leventer, Romania - Hongcheng Liu, China - Xavier Martin, Swiss - Joao Pedro Macedo Vale, Portugal - Gilda Marzullo, Chile - Alena Mayorova, Russia - Irina Medvedeva, Ukraine - Blanca Miller Kobisher, Mexico - Mohamed Oughanem, Algeria - Olga Panova, Russia - Iván Pinto, Venezuela - Raul Pinto, Argentina - Catalin Mihai Popescu, Romania - Aicha Salhi, Algeria - Rikie Smit, South Africa - Hasan Subasi, Turkey - Vladimir Tsepkolenko, Ukraine - Viveka Tinoco Kirby, Ecuador - Ekaterina Ugrekheidze, Georgia - Renier Van Aardt, Canada - Pedra Vega, Spain - Jerzy Woy-Wojciechowski, Poland - J. Yun, Korea - Gulnar Zhumatova, Kazakhstan.

Aesthetic Medicine (registered by the Court of Rome on 28/4/2015 under the number 63/2015) is published 4 times a year (March, June, September, December) by Editrice Salus Internazionale srl, via Giuseppe Ferrari 4 - 00195 Roma, tel. +39 06 36003462 - fax +39 06 37519315, e-mail: salus@editricesalus.it; www.lamedicinaestetica.it.

Subscription Information: All subscriptions inquiries, orders, back issues, claims, and renewals should be addressed to Editrice Salus Internazionale srl. **Free subscription** (Four issues: March, June, September, December).

Copyright Permission: Permission requests to photocopy or otherwise reproduce material published in this journal should be submitted by sending and e-mail to aemj@aestheticmedicinejournal.org.

Advertising: Current advertising rates and specifications may be obtained by sending and e-mail to aemj@aestheticmedicinejournal.org.
EPub [31/07/2017]

Guidelines for Authors

Aesthetic Medicine is a multidisciplinary Journal with the aim of informing readers about the most important developments in the field of Aesthetic Medicine.

Submission of manuscripts

All articles in their final version - completed with name, surname, affiliation, address, phone number and e-mail address of the author (s) - must be sent in word format to the Editorial Committee at the following e-mail address: aemj@aestheticmedicinejournal.org

Manuscripts must be written in English, and authors are urged to aim for clarity, brevity, and accuracy of information and language. All manuscripts must include a structured abstract. Authors whose first language is not English should have their manuscripts checked for grammar and stylistic accuracy by a native English speaker.

MANUSCRIPT SPECIFICATIONS

Title page

The title page should include:

- The name(s) of the author(s)
- A concise and informative title
- The affiliation(s) and address(es) of the author(s)
- The e-mail address, telephone and fax numbers of the corresponding author
- Include a short title (not to exceed 30 characters in length, including spaces between words) for use as a running head
- The authors must disclose any commercial interest that they may have in the subject of study and the source of any financial or material support

Abstract: the length of the abstract should be no more than 250 words and should include the following headings: Background, Aim, Methods, Results, Conclusions

Keywords up to six keywords should be listed and separated by a comma (please, verify keywords on MeSH).

Manuscript categories

Original article

The manuscript should be organised in the following sections:

- Structured Abstract. The length of the abstract should be no more than 250 words and should include the following headings: Background, Aim, Methods, Results, Conclusions
- Introduction
- Materials and Methods
- Results
- Discussion and Conclusions
- Acknowledgments
- Conflict of interest
- Reference list
- Legends (max 10)

The manuscript must not exceed 4000 words and 50 references.

Review

This type of article uses Unstructured Abstract. It must not exceed 4000 words and includes figures and tables (max 15), legends, and up to 200 references.

Mini-review

This type of article uses Unstructured Abstract. It must not exceed 2000 words and includes figures and tables (max 12), legends, and up to 100 references.

Case Report

This type of article uses Unstructured Abstract. It must not exceed 1500 words and includes figures and tables (max 6), legends, and up to 30 references.

Style

- Use a normal, plain font (e.g., 12-point Times Roman) for text
- Double-space the text
- Use italics for emphasis
- Use the automatic page numbering function to number the pages
- Do not use field functions
- Use tab stops or other commands for indents, not the space bar
- Use the table function, not spreadsheets, to make tables

ACKNOWLEDGMENTS

The authors declare that they have no conflict of interest.

If potential conflicts of interest do exist, the authors should provide details (see below) for each affected author in a note in a separate DISCLOSURE section of the manuscript document text, before the list of references.

CONFLICT OF INTEREST DISCLOSURE

Conflicts of Interest need to be explicitly defined before any manuscript can be considered for publication.

References

References must be cited consecutively in the text as superscript numerals and listed on a separate sheet in numerical order at the end of the text. The references must be cited according to the AMERICAN MEDICAL ASSOCIATION (AMA) CITATION STYLE.

For this reason, they must contain author's surname and name initial, the original title of the article, the title of the journal (abbreviated and in italic), the year of publication, the number of the volume, the number of the first and last page.

AMERICAN MEDICAL ASSOCIATION (AMA) CITATION STYLE

Rev. 11/1/2012

General rules from the 10th edition

- Items are listed numerically in the order they are cited in the text
- Include up to 6 authors
- For more than six, provide the names of the first three authors and then add et al
- If there is no author, start with the title
- Periodicals (journals, magazines, and newspapers) should have abbreviated titles; to check for the proper abbreviation, search for the Journal Title through [LocatorPlus](#) at the National Library of Medicine website

Citation Type	Example
Journal article – in print – one author	Spencer J. Physician, heal thyself – but not on your own please. <i>Med Educ.</i> 2005; 89: 548-549.
Journal article – in print – 2-6 authors	Salwachter AR, Freischlag JA, Sawyer RG, Sanfey HA. The training needs and priorities of male and female surgeons and their trainees. <i>J Am Coll Surg.</i> 2005; 201: 199-205.
Journal article – in print – more than 6 authors	Fukushima H, Cureoglu S, Schachern P, et al. Cochlear changes in patients with type 1 diabetes mellitus. <i>Otolaryngol Head Neck Surg.</i> 2005; 133: 100-6.
Journal article – online *if there is no DOI, provide the URL for the specific article	Coppinger T, Jeanes YM, Hardwick J, Reeves S. Body mass, frequency of eating and breakfast consumption in 9-13-year-olds. <i>J Hum Nutr Diet.</i> 2012; 25(1): 43-49. doi: 10.1111/j.1365-277X.2011.01184.x
Journal article – online from a library database* *there is no specific way to cite articles found in library databases according to the AMA so double check with your professor	Calhoun D, Trimarco T, Meek R, Locasto D. Distinguishing diabetes: Differentiate between type 1 & type 2 DM. <i>JEMS [serial online]</i> . November 2011; 36(11):32-48. Available from: CINAHL Plus with Full Text, Ipswich, MA. Accessed February 2, 2012.
Newspaper article – in print *if the city name is not part of the newspaper name, it may be added to the official name for clarity * if an article jumps from one page to a later page write the page numbers like D1, D5	Wolf W. State's mail-order drug plan launched. <i>Minneapolis Star Tribune.</i> May 14, 2004:1B.
Newspaper article – online	Pollack A. FDA approves new cystic fibrosis drug. <i>New York Times.</i> January 31, 2012. http://www.nytimes.com/2012/02/01/business/fda-approves-cystic-fibrosis-drug.html?ref=health . Accessed February 1, 2012.
Websites	Outbreak notice: Cholera in Haiti. Centers for Disease Control and Prevention Web site. http://wwwnc.cdc.gov/travel/notices/outbreak-notice/haiti-cholera.htm Published October 22, 2010. Updated January 9, 2012. Accessed February 1, 2012.
Entire book – in print	Modlin J, Jenkins P. <i>Decision Analysis in Planning for a Polio Outbreak in the United States</i> . San Francisco, CA: Pediatric Academic Societies; 2004.
Book chapter – in print	Solensky R. Drug allergy: desensitization and treatment of reactions to antibiotics and aspirin. In: Lockey P, ed. <i>Allergens and Allergen Immunotherapy</i> . 3 rd ed. New York, NY: Marcel Dekker; 2004:585-606.

To find more AMA style citations, go checkout the [AMA Manual of Style: A Guide for Authors and Editors](#). 10th ed. Oxford: Oxford UP.

AMERICAN MEDICAL ASSOCIATION (AMA) CITATION STYLE

Rev. 11/1/2012

Citing sources within your paper

Unlike APA or MLA, you will not use the author's last name for the in-text citations. Instead, you will number each instance when you are referencing an article. The order of numbering will be contingent on the order in which you use that reference within your paper. In the example below, the first article referenced is given the number one in superscript. In the References section, you will find the matching article listed as number 1.

Example Article	
1. Zoellner J, Krzeski E, Harden S, Cook E, Allen K, Estabrooks PA. Qualitative application of the theory of planned behavior to understand beverage consumption behaviors among adults. <i>J Acad Nutr Diet</i> . 2012;112(11):1774-1784. doi: 10.1016/j.jand.2012.06.368.	
In-Text Citation Example	<p>LARGE INCREASES IN AMERICANS' CONSUMPTION OF sugar-sweetened beverages (SSB) have been a topic of concern. Between 1977 and 2002, the intake of "caloric" beverages doubled in the United States, with most recent data showing that children and adults in the United States consume about 172 and 175 kcal daily, respectively, from SSB.¹ It is estimated that SSB account for about 10% of total energy intake in adults.^{2,3} High intake of SSB has</p>
References Section Example	<p>References</p> <ol style="list-style-type: none"> 1. Duffey KJ, Popkin BM. Shifts in patterns and consumption of beverages between 1965 and 2002. <i>Obesity</i>. 2007;15(11):2739-2747. 2. Nielsen SJ, Popkin BM. Changes in beverage intake between 1977 and 2001. <i>Am J Prev Med</i>. 2004;27(3):205-210. 3. Drewnowski A, Bellisle F. Liquid calories, sugar, and body weight. <i>Am J Clin Nutr</i>. 2007;85(3):651-661.

Use commas to separate multiple citation numbers in text, like you see between references 2 and 3. Unpublished works and personal communications should be cited in the text (and not on the reference list).¹ Superscript numbers are placed outside periods and commas, and inside colons and semicolons. When citing the same source more than once, give the number of the original reference, then include the page number (in parentheses) where the information was found. See pages 41-44 of the *AMA Manual of Style* for more information.

References

Citing AMA guide website. <http://libguides.stkate.edu/content.php?pid=99799&sid=749106>. Updated April 2011. Accessed October 24, 2012.

To find more AMA style citations, go checkout the [AMA Manual of Style: A Guide for Authors and Editors](#). 10th ed. Oxford: Oxford UP.

Images and Tables

All images within the word file must be numbered progressively and accompanied by the corresponding captions, with precise references in the text. Moreover, the images should be sent separately and in HD (at least 300 Dpi, in TIFF or JPEG format).

Graphs and charts are progressively numbered and accompanied by the corresponding captions, with precise references in the text. They must be sent separately, preferably in Excel format.

It is necessary to give the authorization to reproduce already published materials or to use people portraits, in case they are recognizable. The Authors has full, exclusive and personal responsibility and respect for the rules protecting privacy, originality and content (text, images) of the articles.

Artwork instructions**Permission**

Photographs in which a person is identifiable must either have the face masked out, or be accompanied by written permission for publication from the individual in the photograph. Authors wishing to include figures, tables, or text passages that have already been published elsewhere are required to obtain permission from the copyright owner(s) for both the print and the online format and to include evidence that such permission has been granted when submitting their papers. Any material received without such evidence will be assumed to originate from the authors. Please be informed that we will not be able to refund any costs that may have occurred in order to receive these permissions from other publishers. Please be aware that some publishers do not grant electronic rights for free (an example is Thieme Publishers). In these cases we kindly ask you to use figures from other sources.

Editorial Office**Editrice Salus Internazionale srl**

Via Giuseppe Ferrari 4 - 00195 Roma

Tel. + 39 06 36003462 - Fax +39 06 37519315

E-mail: aemj@aestheticmedicinejournal.orgWebsite: www.aestheticmedicinejournal.org

Submit your manuscripts at aemj@aestheticmedicinejournal.org

Publication Ethics and Publication Malpractice Statement

Aesthetic Medicine undertakes to defend the rules of ethical behavior in every stage of the process by adopting and promoting the standards set by Code of Conduct and Best Practice Guidelines for Journal Editors.

Duties of Editors

Publication decisions

The editor of a peer-reviewed journal is responsible for deciding which of the articles submitted to the journal should be published.

The editor will evaluate manuscripts without regard to the authors' race, gender, sexual orientation, religious belief, ethnic origin, citizenship, or political philosophy. The editor may be guided by the policies of the journal's editorial board and constrained by such legal requirements as shall then be in force regarding libel, copyright infringement and plagiarism.

Confidentiality

The editor and any editorial staff must not disclose any information about a submitted manuscript to anyone other than the corresponding author, reviewers, potential reviewers, other editorial advisers or the publisher, as appropriate.

Disclosure and conflicts of interest

Unpublished materials disclosed in a submitted manuscript must not be used in an editor's own research without the express written consent of the author. Privileged information or ideas obtained through peer review must be kept confidential and not used for personal advantage. When the editorial board is notified or discovers a significant problem regarding errors/ inaccuracy, undisclosed conflict of interest, plagiarism, in a published article, the editorial board will promptly notify the corresponding author and the publisher and will undertake the necessary actions to clarify the issue and in case of need to retract the paper or publish an *Erratum*, following the COPE Guidelines.

Involvement and cooperation in investigations

An editor should take reasonably responsive measures when ethical complaints have been presented concerning a submitted manuscript or published paper, in conjunction with the publisher (or society). Such measures will generally include contacting the author of the manuscript or paper and giving due consideration of the respective complaint or claims made, but may also include further communications to the relevant institutions and research bodies, and if the complaint is upheld, the publication of a correction, retraction, expression of concern, or other note, as may be relevant. Every reported act of unethical publishing behaviour must be looked into, even if it is discovered years after publication.

Duties of reviewers

Contribution to editorial decisions

Peer review assists the editor in making editorial decisions and through the editorial communications with the author may also assist the author in improving the paper. Peer review is an essential component of formal scholarly communication, and lies at the heart of the scientific endeavour. *Aesthetic Medicine* shares the view of many that all scholars who wish to contribute to publications have an obligation to do a fair share of reviewing.

Promptness

Any selected referee who feels unqualified to review the research reported in a manuscript or knows that its prompt review will be impossible should notify the editor and excuse him/herself from the review process.

Confidentiality

Any manuscripts received for review must be treated as confidential documents. They must not be shown to or discussed with others except as authorised by the editor.

Standards of objectivity

Reviews should be conducted objectively. Personal criticism of the author is inappropriate. Referees should express their views clearly with supporting arguments.

Acknowledgement of sources

Reviewers should identify relevant published work that has not been cited by the authors. Any statement that an observation, derivation, or argument had been previously reported should be accompanied by the relevant citation. A reviewer should also call to the editor's attention any substantial similarity or overlap between the manuscript under consideration and any other published paper of which they have personal knowledge.

Disclosure and conflict of interest

Unpublished materials disclosed in a submitted manuscript must not be used in a reviewer's own research without the express written consent of the author. Privileged information or ideas obtained through peer review must be kept confidential and not used for personal advantage. Reviewers should not consider manuscripts in which they have conflicts of interest resulting from competitive, collaborative, or other relationships or connections with any of the authors, companies or institutions connected to the papers.

Duties of authors**Reporting standards**

Authors of reports of original research should present an accurate account of the work performed as well as an objective discussion of its significance. Underlying data should be represented accurately in the paper. A paper should contain sufficient detail and references to permit others to replicate the work. Fraudulent or knowingly inaccurate statements constitute unethical behaviour and are unacceptable. Review and professional publication articles should also be accurate and objective, and editorial 'opinion' works should be clearly identified as such.

Data access and retention

Authors may be asked to provide the raw data in connection with a paper for editorial review, and should in any event be prepared to retain such data for a reasonable time after publication.

Originality and plagiarism

The authors should ensure that they have written entirely original works, and if the authors have used the work and/or words of others, that these have been appropriately cited or quoted. Plagiarism takes many forms, from "passing off" another's paper as the author's own paper, to copying or paraphrasing substantial parts of another's paper (without attribution), to claiming results from research conducted by others. Plagiarism in all its forms constitutes unethical publishing behaviour and is unacceptable.

Multiple, redundant or concurrent publication

An author should not in general publish manuscripts describing essentially the same research in more than one journal or primary publication. Submitting the same manuscript to more than one journal concurrently constitutes unethical publishing behaviour and is unacceptable. In general, an author should not submit a previously published paper for consideration in another journal.

Acknowledgement of sources

Proper acknowledgment of the work of others must always be given. Authors should cite publications that have been influential in determining the nature of the reported work. Information obtained privately, for example in conversation, correspondence, or discussion with third parties, must not be used or reported without explicit, written permission from the source. Information obtained in the course of confidential services, such as refereeing manuscripts or grant applications, must not be used without the explicit written permission of the author of the work involved in these services.

Authorship of the paper

Authorship should be limited to those who have made a significant contribution to the conception, design, execution or interpretation of the reported study. All those who have made significant contributions should be listed as co-authors.

Where there are others who have participated in certain substantive aspects of the research project, they should be acknowledged or listed as contributors. The corresponding author should ensure that all co-authors have seen and approved the final version of the paper and have agreed to its submission for publication.

Hazards and human or animal subjects

If the work involves chemicals, procedures or equipment that have any unusual hazards inherent in their use, the author must clearly identify these in the manuscript. If the work involves the use of animal or human subjects, the author should ensure that the manuscript contains a statement that all procedures were performed in compliance with relevant laws and institutional guidelines and that they have been approved by the appropriate institutional committee(s). Authors should include a statement in the manuscript that informed consent was obtained for experimentation with human subjects. The privacy rights of human subjects must always be observed.

Disclosure and conflicts of interest

All authors should disclose in their manuscript any financial or other substantive conflict of interest that might be construed to influence the results or interpretation of their manuscript. All sources of financial support for the project should be disclosed. Examples of potential conflicts of interest which should be disclosed include employment, consultancies, stock ownership, honoraria, paid expert testimony, patent applications/registrations, and grants or other funding. Potential conflicts of interest should be disclosed at the earliest stage possible.

Fundamental errors in published works

When an author discovers a significant error or inaccuracy in his/her own published work, it is the author's obligation to promptly notify the journal editor or publisher and cooperate with the editor to retract or correct the paper. If the editor or the publisher learns from a third party that a published work contains a significant error, it is the obligation of the author to promptly retract or correct the paper or provide evidence to the editor of the correctness of the original paper.

EDITORIAL

In modern years, aesthetics has become quite important in every aspect of everyday life: following the hundreds of journals, magazines, blogs and websites pointing their attention towards this interesting and fascinating topic, the request for aesthetic medicine has increased manifolds.

Aesthetic Medicine is a new field of medicine, in which different specialists share the aim of constructing and reconstructing the physical equilibrium of the individual. Treatment of physical aesthetic alterations and unaesthetic sequel of illnesses or injuries, together with the prevention of aging, are perhaps two of the most iconic areas of intervention for Aesthetic Medicine. However, in order to prevent frailty in the elderly, a program of education is similarly important. Furthermore, the line between health and beauty is extremely thin: psychosomatic disorders resulting from low self-esteem due to aesthetic reasons are frequent and cannot be ignored by a clinician.

It is therefore clear that there is no figure in the field of medicine which is not involved in Aesthetic Medicine: endocrinologists, gynecologists, angiologists, psychologists and psychiatrists, plastic surgeons, dermatologists, dieticians, physiotherapists, orthopedists, physical education instructors, massophysiotherapists, podologists, and rehabilitation therapists are just some of the specialists who are sooner or later going to have to answer their patients' needs for aesthetic interventions. The involvement of all these specialists fits the description of health as defined by the WHO: "a state of complete physical, mental and social well-being and not merely the absence of disease or infirmity" for which, undeniably, a team of different physicians is required.

The number of patients requiring medical consultation for esthetic reasons is rapidly increasing: in order to be able to provide adequate feedback, medical and paramedical specialists should be trained and, more importantly, should be taught how to work together. Existing Societies of Aesthetic Medicine from different countries share the aim of creating such teams and provide constant updates to the literature: the creation of an international network of specialists from all around the world under the

flag of Aesthetic Medicine represents a challenge, but at the same time it is the proof of the widespread interest in this topic.

The first issue of this Journal represents the results of the efforts of the many national Societies and of the *Union Internationale de Médecine Esthétique*, now together as one; it is our hope that in years to come this Journal might improve our knowledge in this field, and provide adequate scientific advancement in the field of Aesthetic Medicine.

Francesco Romanelli, MD
Editor-in-chief
Associate Professor at "Sapienza"
University of Rome

EDITORS' NOTES

Aesthetic Medicine, the booming medical activity

Aesthetic Medicine was born in France 40 years ago. The French Society of Aesthetic Medicine was the first of its kind in the world, followed by Italy, Belgium and Spain. Starts were rather difficult as aesthetic procedures in those early years were only surgical. At that time aesthetic doctors and cosmetic dermatologists had very few real medical procedures to offer to their patients for treating aesthetic problems on face and body.

At the beginning of the '80s, viable medical procedures started to emerge in Europe for aesthetic and cosmetic purposes. Mostly, at that time, they were imported from the United States: those included collagen injections for wrinkles (Zyderm by Dr. Stegman), and chemical peels (phenol by Dr. Baker, TCA by Dr. Obagi). But, subsequently, European research on Aesthetic Medicine gained momentum. Hyaluronic acid appeared on the market, as it was discovered that it could be used as a dermal filler for wrinkles.

During the '90s, the use of lasers offered aesthetic doctors and cosmetic dermatologists new possibilities. The "beam revolution" started with CO2 laser for facial resurfacing. Today, CO2 resurfacing is not used as much anymore, because of the long and difficult post-op. CO2 laser was replaced with the gentler Nd-YAG and Erbium lasers and more recently with non-invasive photonic devices for facial rejuvenation, including IPL, US and radiofrequency. These new technologies allow today's aesthetic doctors and cosmetic dermatologists to offer their patients procedures with low risk of post-op complications.

Then, Botulinum Toxin has "invaded" both sides of the Atlantic Ocean. Today, Botox injections are the most popular treatment for facial expressive wrinkles. Botox injections are now so common everywhere that many cosmetic surgeons have given up their bistouries for syringes.

Last but not least, development in Aesthetic Medicine is shown by mesotherapy and adipolipolysis. About lipolysis, new data and recent publications have explained that radiofrequency, ultrasounds and cryolyse could have positive action to dissolve fat and to improve some unaesthetic disorders like cellulite. The-

se non invasive procedures intend to replace the surgical liposculpture with success.

Nowadays, Aesthetic Medicine has the necessary tools to address all major disorders within the aesthetic field.

After 40 years, Aesthetic Medicine is now active in 27 countries in the world (France, Italy, Spain, Belgium, Morocco, Poland, Russia, Switzerland, Romania, Kazakhstan, Algeria, Brazil, Argentina, Uruguay, Venezuela, Colombia, Chile, Mexico, U.S.A, Canada, South Korea, and recently Ecuador, China, South Africa, Turkey, Ukraine and Georgia). All 27 national Societies are members of the *Union Internationale de Médecine Esthétique* (U.I.M.E.).

Aesthetic Medicine is taught in 8 countries (France, Italy, Spain, Brazil, Argentina, Mexico, Venezuela, Kazakhstan) in universities that deliver UIME's diplomas after 3 to 4 years of studies.

What is the future of Aesthetic Medicine?

In the last few decades, patients' desires to look and feel young, have fueled Aesthetic Medicine and Cosmetic Dermatology: many different procedures have been developed to satisfy the demands.

As life-span have increased, patients today are not only asking about aesthetic procedures, they are also asking for a way to stay in good physical conditions in the last decades of their lives.

As a direct result, Anti-Aging Medicine, which covers skin aging and general aging, has recently emerged and expanded very quickly.

Anti-Aging Medicine can offer senior patients better nutrition, dietary supplementation with vitamins, minerals, antioxidants, and eventually hormone replacement therapy, but only when needed.

Today, and in the near future, both Aesthetic Medicine and Anti-Aging Medicine will offer to our patients, who now live longer, better wellness with aesthetic treatments for skin aging and anti-aging treatments for general aging.

Aesthetic Medicine is booming, but all medical practitioners should be correctly trained, so its future will be bright.

*Jean-Jacques Legrand, MD
General Secretary of UIME*

Aesthetic Medicine: a bioethic act

When in 1977 the Italian Society of Aesthetic Medicine published the first issue of the magazine “La Medicina Estetica” Carlo Alberto Bartoletti, the Founder, wrote an editorial in which traced the pathway of the discipline and of the Scientific Society, still valid and projected into the future.

Today from that Editorial Board arise an International Journal, which wants to be indexed, in order to give to the doctors practicing Aesthetic Medicine all around the world a solid basis of shared knowledge.

In the late ‘60s, what was called in Italy Aesthetic Medicine, moved its first steps thanks to “remise en forme and anti aging projects” imported from the experience the “Institutul de geriatrie Bucuresti”, directed by Dr. Ana Aslan.

For this reason, there is the bioethical imperative that the Discipline should be first prevention, then return to physiology and finally correction.

The worldwide diffusion and the efforts of Industries born on the wave of the phenomenon have often led to choose the fastest route to achieve and maintain the physical aspect in the myth of beauty at all costs, without considering that aesthetic is not synonymous of beauty, but it is a balance between body and mind, and the role of the doctor is to take care of the Person globally and not only focusing on the correction of “a badly accepted blemish”.

Faithful to the teaching of my Master had almost 50 years ago, this new journal will have the task of elevating the human resources, aligning and validating methodologies, but above all affirming the *humanitas* of the medical art in its purest sense to pursue the good and the graceful for the person who relies on it.

*Fulvio Tomaselli, MD
Honorary President of the Italian
Society of Aesthetic Medicine*

Aesthetic Medicine needs science. All over the world.

All Aesthetic Doctors know that science is the basis for safety. Safety is the most important issue in our discipline.

Unfortunately, Aesthetic Medicine is more often surrounded by marketing than by science, despite the hard work done by Scientific Societies all over the World. And, too often doctors working in this field are dealing with sellers that promote products with insufficient scientific studies. However, they sell it anyway. I think that doctors must learn that the first thing to ask about a medical device is the scientific background regarding that product: patients treated, follow up period, adverse events and, most of all, publications.

With this new International Journal completely dedicated to Aesthetic Medicine, proposed by the Italian Society of Aesthetic Medicine, endorsed by UIME and shared by all the National Societies of Aesthetic Medicine belonging to UIME, World Aesthetic Medicine wants to stimulate scientific production in this discipline to increase safety and quality in aesthetic medical procedures.

Another important goal of the Journal is to catalyze the proposal of new protocols and guidelines in Aesthetic Medicine, with the consensus of the entire Aesthetic Medicine Scientific Community.

What this Journal should achieve in the near future is to improve the number and quality of scientific production in Aesthetic Medicine, in order to allow this discipline to grow in the field of evidence based medicine, not only in the rationale field.

I hope this can be the start of a new era for Aesthetic Medicine, with the commitment of all Scientific Societies all over the world.

*Emanuele Bartoletti, MD
Managing Editor
President of the Italian
Society of Aesthetic Medicine*

**INTERNATIONAL SOCIETIES
and NATIONAL SOCIETIES OF AESTHETIC MEDICINE**

INTERNATIONAL SOCIETY OF AESTHETIC MEDICINE
154, rue Armand Silvestre - 92400 Courbevoie - France
Honorary Presidents: C.A. BARTOLETTI † (Italy), A. BOURRA
(Morocco), M. DELUNE (USA), A. FARIA DE SOUZA (Brazil),
J. FONT-RIERA† (Spain), G. MARZULLO (Chile), R. PINTO
(Argentina), J. HEBRANT (Belgium), A. ELBAUM (Uruguay)

President: M. OUGHANEM (Algeria)
Vicepresident: V. GARCIA GUEVARA
(Venezuela)
General Secretary: J.J. LEGRAND (France)
General Secretary in charge
of the American Continent:
of Africa and Middle East: R. PINTO (Argentina)
A. BOURRA (Morocco)

ALGERIAN SOCIETY OF AESTHETIC MEDICINE
Bt.T1, N°2, Diar Es Saada, El Madania, Algiers - Algeria
oughanem_m@hotmail.com - www.same-dz.com
President: M. OUGHANEM

ARGENTINE SOCIETY OF AESTHETIC MEDICINE
Avenida Santa Fé 3288, 4°A - 1425 Buenos Aires - Argentina
pinto@soarme.com - www.soarme.com
President: R. PINTO

BELGIAN SOCIETY OF AESTHETIC MEDICINE
Chaussée de Marche 390 - 5100 Jambes - Belgium
jean.hebrant@skynet.be - www.aesthetic-medicine.be
President: J. HEBRANT

BRASILIAN ASSOCIATION OF AESTHETIC MEDICINE SCIENCES
Avenida Vereador José Diniz - 2480 - Brooklin
Sao Paulo CEP 04604-004
clara_santos@terra.com.br
President: C. SANTOS

CANADIAN ASSOCIATION OF AESTHETIC MEDICINE
c/o CongressWorld Conferences Inc.
220-445 Mountain Highway
North Vancouver, BC, Canada V7J 2L1
drvanaardt@nslaser.com - s.roberts@caam.ca - www.caam.ca
President: R. VAN AARDT

CHILEAN ASSOCIATION OF AESTHETIC MEDICINE
Avda President Riesco 2955, apto 1102, Las Condes Santiago - Chile
dogcm@estetic.cl
President: G. MARZULLO

CHINA ACADEMY OF AESTHETIC MEDICINE
Department of Stomatology, General Hospital of PLA 28 Fuxing
road, BEIJING 100853 - China
caam01@126.com - www.caamed.com
President: LIU HONG CHENG

COLOMBIAN ASSOCIATION OF AESTHETIC MEDICINE
Calle 4 Sur, n. 43 a 195 - Oficina 141 - Bloque B - Medellin -
Colombia
acicme@gmail.com - www.acicme.com.co
President: G. ARROYAVE ESTRADA

ECUADORIAN SOCIETY OF AESTHETIC MEDICINE
Ave de los Shyris 344 y Eloy Alfaro, Edificio Parque Central, Oficina
609 - Quito - Ecuador
seem2008cg@gmail.com - www.seem.com.ec
President: V. TINOCO KIRBY

FRENCH SOCIETY OF AESTHETIC MEDICINE
154, rue Armand Silvestre - 92400 Courbevoie - France
jilegrand-md@sfme.info - www.sfme.info
President: J.J. LEGRAND

GEORGIAN SOCIETY OF AESTHETIC MEDICINE
I. Abashidze str. 77, Tbilisi 0162 - Georgia
info@gsoam.ge - www.gsoam.ge
President: E. UGREKHELIDZE

ITALIAN SOCIETY OF AESTHETIC MEDICINE
Via Monte Zebio 28 - 00195 Rome - Italy
simei@lamedicinaestetica.it - www.lamedicinaestetica.it
President: E. BARTOLETTI

KAZAKHSTAN ASSOCIATION OF AESTHETIC MEDICINE AND
PLASTIC SURGERY
139, Tulebaeva Str. - 480091 Almati, Medeouski
arugulnar@hotmail.com - www.estetic.kz
President: G. ZHUMATOVA
KOREAN ACADEMY OF AESTHETIC MEDICINE
Han-Song B.D. 801, Myeong-dong, Jung-gu, Seoul - Korea
zzang0703@naver.com - www.ons.or.kr
President: J-B. YUN

MEXICAN SCIENTIFIC SOCIETY OF AESTHETIC MEDICINE
Cincinnati 81-307 - Col. Noche Buena - Mexico D.F. 03720 - Mexico
bmillerkobisher@yahoo.com
President: J-B. MILLER KOBISHER

MOROCCAN SOCIETY OF AESTHETIC MEDICINE
19, place du 16 Novembre - 20250 Casablanca - Morocco
drbourra@hotmail.com - www.dermastic.asso.ma
President: A. BOURRA

POLISH SOCIETY OF AESTHETIC AND ANTI-AGING MEDICINE OF
POLISH MEDICAL SOCIETY
Ujazdowskie 22, 00-478 Warszawa - Poland
psme@psme.waw.pl; www.ptmeiaa.pl
President: A. IGNACIUK

ROMANIAN SOCIETY FOR AESTHETIC MEDICINE AND DERMATO-
LOGIC SURGERY
Sevastopol 13-17, Sector 1, Hotel Diplomat, Apt.204 Bucharest -
Romania
mihaelaleventer@drleventercentre.com - www.srme.ro
President: M. LEVENTER

RUSSIAN NATIONAL AESTHETIC MEDICINE SOCIETY
12/3 Fotievoi Street, Pol. n.3 - of.512 - 119333 Mosca - Russia
o.panova@rs-am.ru - www.rs-am.ru
President: O. PANOVA

AESTHETIC AND ANTI-AGING MEDICINE SOCIETY OF SOUTH
AFRICA
PO Box 1190 - Montana Park 0159 - South Africa
drsmmit@ackmain.com
President: R. SMIT

SPANISH SOCIETY OF AESTHETIC MEDICINE
Ronda General Mitre, 210
08006 Barcelona - Spain
secretaria@seme.org - www.seme.org
President: P. VEGA

SWISS SOCIETY OF AESTHETIC MEDICINE
La Clinique - avenue de Collonge, 43 - CH - 1820 Territet -
Montreux
s.lehuu@laclinique.ch - www.ssme.ch
President: S. LE-HUU

SOCIETY OF AESTHETIC MEDICINE IN TURKEY
Rumeli Caddesi Durak Apt N° 2, D.7 - Nisantasi, Istanbul
subasihanm@superonline.com
www.estetiktipdernegi.org.tr
President: H. SUBASI

UKRAINIAN SOCIETY OF AESTHETIC MEDICINE
Bunina Street, 10 Odessa 65026 - Ukraine
office@virtus.ua
President: V. TSEPKOLENKO

AESTHETIC MEDICINE SOCIETY OF URUGUAY
Ave. Sarmiento, 2470 - 11300 Montevideo - Uruguay
alberto@drelbaum.com - www.sume.com.uy
President: A. ELBAUM

AMERICAN ACADEMY OF AESTHETIC MEDICINE
24671 La Vida Drive - Laguna Niguel, Ca 92677 - USA
mdelune@aol.com - www.aaamed.org
President: M. DELUNE

AESTHETIC MEDICINE SOCIETY OF VENEZUELA
Av. Sucre de Los Dos Caminos, entre 4ta y 5ta transversal,
Res. Centro Parque Boyacá, Edificio Centro, Piso 20, Off. 201 1070
Caracas - Venezuela
fuceme@gmail.com - www.fuceme.org - www.sociveme.org
President: V. GARCIA GUEVARA

PORTUGUESE SOCIETY OF AESTHETIC AND ANTI-AGING MEDICINE
Rua Maria Vitoria Bourbon Bobone, Lote 21, N°41, Apto. 201
P-3030-502 Coimbra
joao.vale@spme.pt - www.spme.pt
President: J.P. MACEDO VALE

CROATIAN ASSOCIATION OF AESTHETIC MEDICINE
Joakima Rakovca 10, HR-51410 Opatlia
dr.bunar@gmail.com - www.huem.hr
President: E. BUNAR

Dermoscopy in Aesthetic Medicine: usefulness and limits (I part)

Elisabetta Fulgione^{1,2}, Vincenzo Piccolo¹, Anna Rosa Catizzone²,
Giuseppe Argenziano¹

¹Dermatology Unit, University of Campania "Luigi Vanvitelli", Napoli

²Academy Section of the Italian Society of Aesthetic Medicine (SIME)

ABSTRACT

Dermoscopy is a non-invasive diagnostic technique that permits the visualization of morphologic features that are not visible to the naked eye.

This tool is thus a very important support for the dermatologist but also for the aesthetic doctor who, while addressing "healthy" skin with no disease, he can make a more accurate diagnosis and choose the most suitable treatment with the best aesthetic results for the patient.

The purpose of this article is to provide an overview of the most important recent advances in the world of dermoscopy that can be useful for the aesthetic doctor.

Keywords

Dermoscopy, pigmented skin lesions, 3-point check list

Correspondence

Elisabetta Fulgione, MD
Dermatology Unit, Second University of Napoli
Via Sergio Pansini, 5 - 80131 Napoli
E-mail: elisafulgione@gmail.com

Accepted for publication 18 May 2017

© 2017 Editrice Salus Internazionale srl

Introduction

Dermoscopy is a non-invasive diagnostic technique that permits the visualization of morphologic features that are not visible to the naked eye, thus representing a link between macroscopic clinical dermatology and microscopic dermatopathology¹. Dermoscopy improves the diagnostic accuracy in the clinical evaluation of pigmented skin lesions, but it is also useful for the assessment of vascular structures that are not visible to the naked eye. As a consequence, dermoscopy has been increasingly employed for the differential diagnosis of nonpigmented skin disorders, including tumours but also inflammatory and infectious diseases^{2,3}.

Although dermoscopy represents an exquisitely a specialised investigation, it could be a valuable support in aesthetic medicine to:

- correctly identify benign pigmented lesions that can be safely treated for cosmetic purposes;
- facilitate the differential diagnosis of inflammatory skin diseases (rosacea, LES, etc);
- allow differential diagnosis of a large number of disorders of the skin appendages cosmetic problems (nail and hair disorders);

Technique

Dermoscopy (or dermatoscopy), also known as epiluminescence microscopy or episcopy, is a non-invasive diagnostic tool that helps in the evaluation of the colours and microstructures of the epidermis, dermo-epidermal junction, and papillary dermis, which are not normally visible to the naked eye. Functionally, a dermoscope is similar to a magnifying lens, but with the added advantages of having inbuilt illumination and a higher magnification that makes it possible to assess structures as deep as in the reticular dermis. The list of dermoscopy instrumentation is long and continues to grow and evolve with the development of better and more sophisticated handheld instruments and computer systems¹. The basic principle of dermoscopy is the transillumination of a lesion and the study of it with greater magnification. Fluid immersion and polarized systems are available. Fluid immersion involves applying mineral oil or spraying alcohol onto the lesion, then placing the lens in contact with the skin. This system has the advantage of accurate focus but the disadvantage of compressing the vessels. The plate should be cleaned and sterilised after each patient observation using alcohol. Alternatively, the lens can be covered with a fresh piece of polyvinyl film (cling film) between each patient. On the other hand polarised lenses do not need to be in contact with the skin and they enable you to quickly scan over many lesions on the body surface. In general, the polarised system is as good as the fluid immersion technique, but it is better in vessel

evaluation. However, it may be helpful to wipe a scaly lesion with oil to enhance the view.

The colours in dermoscopy⁴

Understanding colours in dermoscopy is important as it helps to determine the level of melanin in the skin (figure 1 and table 1):

- Black - superficial epidermis;
- Brown - epidermis;
- Black - superficial epidermis;
- Brown - epidermis;
- Grey - papillary dermis;
- Blue - reticular dermis.

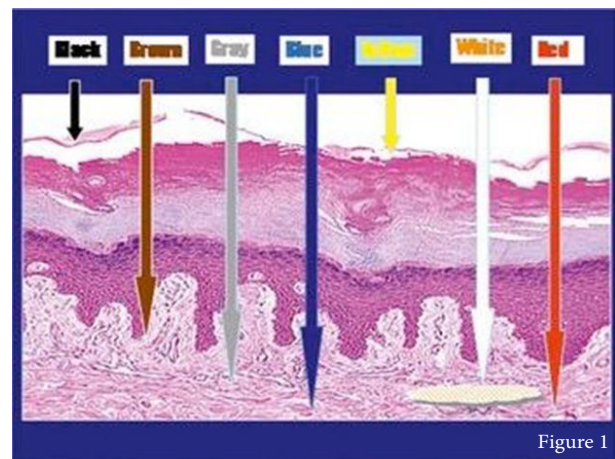


Figure 1

Figure 1 - The colour of dermoscopy

LOCALISATION OF THE PIGMENT	COLOUR OF THE LESION IN DERMOSCOPY
Melanin in stratum corneum	Black
Melanin in the epidermis, dense	Dark Brown
Papillary dermis	Light Brown
Melanin in the papillary dermis	Grey
Melanin in the reticular dermis	Blue
Combination of melanin and keratin, serum in crust	Orange
Keratin	Yellow
Absence of melanin, sclerosis of the dermis, keratin	White
Blood	Red
Blood (poorly oxygenised)	Purple

Table 1 - Localisation of the pigment

Skin lesions have a variety of colours including brown, black, blue, grey, white, yellow and red. In general, the greater the number of colours, the more likely the lesion is to be malignant. This is not always true, in fact a minority of melanomas are relatively non-specific and can be amelanotic/hypomelanotic.

Dermoscopy and Aesthetic Medicine

Differential diagnosis of pigmented skin lesions

The treatment of pigmented lesions of the skin in cosmetic medicine cannot be done without a correct differential diagnosis. The examination of pigmented skin lesions should always be accompanied by two steps: the first step consisting of the clinical and medical history, and the second step consisting of dermoscopy.

Step I: Identification of patients at risk⁵

Three types of patients can be identified in different age groups:

- 1) Patients younger than 15 years with congenital nevi or Spitz nevi;
- 2) Patients older than 15 years with:
 - Many moles on the arms (> 20);
 - One or more flat lesions, large (>6 mm) and asymmetric (ABCDE rule);
 - One or more nodular growing lesions (EFG);
- 3) Patients older than 50 years with severe solar damage.

In aesthetic medicine, most patients belong to the second and third category in the list above.

Patients older than 15 years with: many moles on the arms (> 20)

Patients with more than 20 moles on the upper limbs are more likely affected by the so-called "dysplastic nevus syndrome", which is one of the most important risk factor for melanoma in this age group. In these cases, before treating a pigmented lesion for any reason, it is advisable that the patient should be evaluated using dermoscopy. It should be pointed out that nevi less than 2mm in diameter should not be considered in the total count of the lesions.

"ABCDE" rule⁶

Pigmented flat lesions could be evaluated with the ABCD rule of melanoma, where "A" stands for asymmetry, "B" for irregular edges (like geographical map), "C" for heterogeneous colour (varying from brown to black to grey), and "D" for diameter larger than 6mm. Some authors report the opportunity to

add to the ABCD the letter "E" for evolution, i.e. patient self-assessment of variation in shape, colour and size. In these cases, dermoscopy is advisable to promptly detect melanoma. Several benign pigmented lesions may show morphological characteristics similar to melanoma in situ. In particular, the aesthetic doctor could often be requested to treat solar lentigos on the face, which sometimes cannot not be easily distinguished from lentigo maligna (melanoma in situ). Although dermoscopic examination still remains the key diagnostic tool in these cases, some clinical features could be useful to suspect lentigo maligna: asymmetry and irregular edges, darker pigmentation, and growth rate of the lesion.

"EFG" rule⁶

Nodular lesions should be assessed according to the rule of EFG. This acronym is useful to remember the clinical features of fast-growing melanoma, that is usually nodular and does not fits the ABCD criteria. In EGF, "E" stands for elevation, "F" for firm nodule (hard to palpation), and "G" for growing (in less than) one year. This type of melanoma has a very aggressive biologic behaviour, that's why lesions detected by the EFG rule should be immediately sent to a dermatologist for correct evaluation and excision. In aesthetic medicine, the main differential diagnosis of nodular melanoma is with dermal nevus, that is in general a nodular lesion, but soft on palpation, with papillomatous surface and a history of long standing lesion.

Patients older than 50 years

In this age group, a selective criterion for a specialised examination is the presence of actinic damage on the face, décolleté, and the dorsum of the hands. When in these sites actinic keratoses are present, total body dermoscopy is advisable. Skin examination usually shows benign lesions, such as dermal nevi, seborrheic keratoses and cherry angiomas. Among benign lesions, a careful dermatologic and dermoscopic examination permits one to easily recognize suspicious lesions.

Step II: dermoscopy

Differential diagnosis of melanocytic and non-melanocytic lesions^{1,7}

Dermoscopy is a specialised investigation, but it may be useful for the aesthetic doctor to distinguish a potentially malignant lesion. The distinction between melanocytic lesions (nevi, lentigo, and malignant melanoma) (figures 2a-b, 3a-b) and non-melanocytic (seborrheic keratosis, dermatofibroma, basal cell carcinoma) is the first step to avoid inappropriate treatments (figures 4a-b, 5a-b).

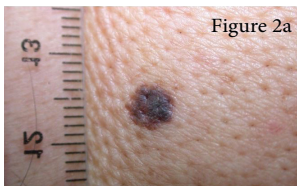


Figure 2a

Figure 2a - Clark nevus

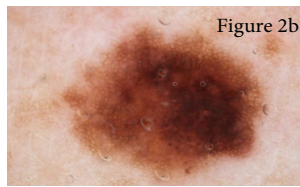


Figure 2b

Figure 2b - Clark nevus (dermoscopy)

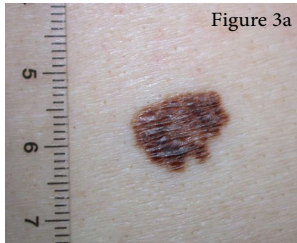


Figure 3a

Figure 3a - Melanoma

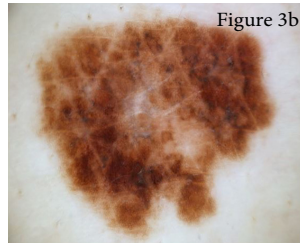


Figure 3b

Figure 3b - Melanoma (dermoscopy)

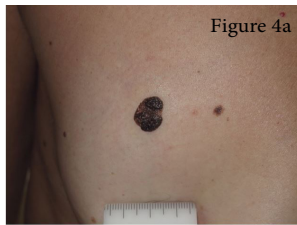

Figure 4a

Figure 4a - Seborrheic keratosis

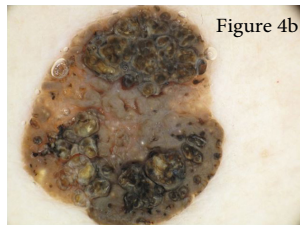


Figure 4b

Figure 4b - Seborrheic keratosis (dermoscopy)

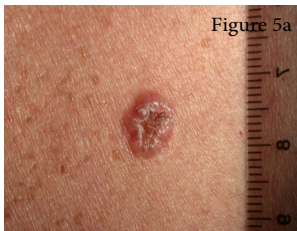


Figure 5a

Figure 5a - Basal cell carcinoma

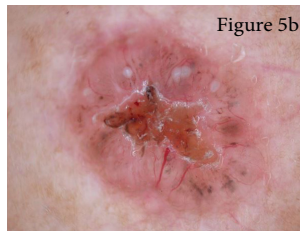


Figure 5b

Figure 5b - Basal cell carcinoma (dermoscopy)

Global dermoscopic patterns for melanocytic lesions

Reticular pattern

The reticular pattern is the most common global pattern in melanocytic lesions. It is characterised by a pigment network covering most parts of a lesion. The pigment network appears as a grid of line segments in different shades of black, grey and brown. Modifications of the pigment network vary with changes in the biologic behaviour of melanocytic skin lesions, and these variations therefore deserve special attention.

Global pattern

Variably-sized, round-to-oval brown structures make up these melanocytic lesions.

Homogeneous pattern

This pattern is characterised by a diffuse, uniform structureless colour filling on most of the lesion. Colours include black, brown, grey, blue, white or red.

Starburst pattern

This pattern is characterised by the presence of pigmented streaks and/or dots and globules in a radial arrangement at the periphery of a melanocytic lesion.

Non-specific pattern

In some instances, a melanocytic lesion cannot be categorised into one of global patterns listed above and it is therefore categorised as having a “non-specific pattern”. A non-specific pattern may be found in melanoma. To diagnose non-melanocytic pigmented skin lesions, there should be an absence of criteria for melanocytic lesions (pigmented network, globules, streaks, homogeneous and parallel patterns) and the presence of criteria specifically considered for seborrheic keratoses, vascular lesions, and basal cell carcinomas.

3-point checklist⁸

The 3-point checklist was developed specifically for non-expert doctors with little training in dermoscopy to help them to recognise melanoma.

Results of the Consensus Net Meeting in Dermoscopy showed that the following three criteria were especially important in distinguishing suspicious skin lesions from other benign pigmented skin lesions:

- Asymmetry: asymmetry of colour and structure in one or two perpendicular axes;
- Atypical network: pigmented network with irregular holes and thick lines;
- Blue-white structures: any type of blue and/or white colour.

The presence of two or three criteria is suggestive of a suspicious lesion: it is recommended that all lesions with a positive test (3-point checklist score of 2 or 3) should be excised by a dermatologist because they are potentially malignant (figures 6-7-8).

Dermoscopy in aesthetic medicine

After the extensive introduction dealing with the general rules of dermoscopy for the diagnosis of

melanocytic lesions, the purpose of this review is to give practical tips for the diagnosis of cutaneous lesions and skin disorders which practitioners encounter in daily practice of aesthetic medicine.

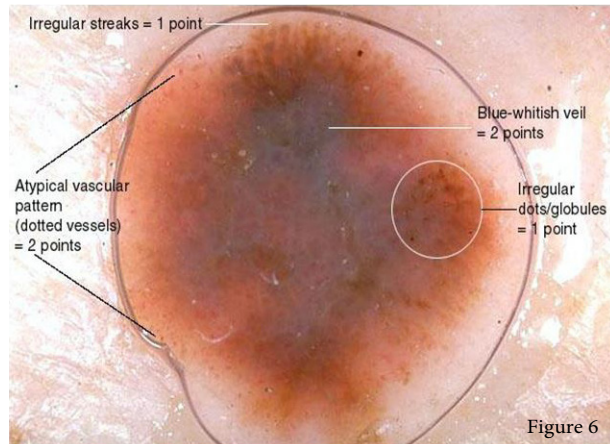


Figure 6 - 3-point checklist

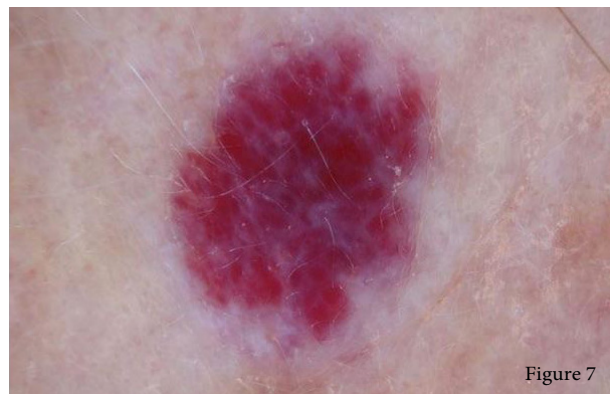

Figure 7 - Cherry angioma (score 1)

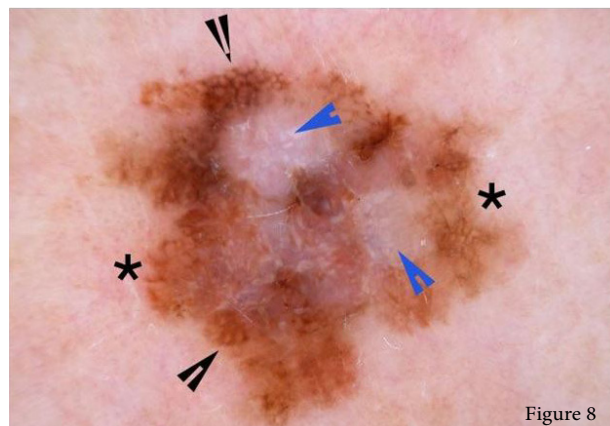


Figure 8 - Melanoma (score 3)

The universe of pigmented facial lesions

In aesthetic medicine, patients commonly seek consultation for the removal of disfiguring pigmented lesions of the face.

Since solar lentigo/seborrheic keratosis (SL/SK) (figures 9a and 9b), lichenoid keratosis (LPLK), and lentigo maligna (LM) (figures 10a and 10b) often display overlapping clinical and dermoscopic features, the correct recognition of LM is one of the most challenging clinical tasks in dermatology.

Dermoscopic features in favour of LM diagnosis are: asymmetric pigmented follicular openings, dark rhomboidal structures, slate-grey globules, and slate-grey dots. In contrast, the detection of a sharp demarcation, moth-eaten borders, and fingerprinting supports the diagnosis of SL/SK⁹. The differentiation between PAK and LM could be difficult and biopsy is often required for the diagnosis. A simple rule should be kept in mind when dealing with facial pigmented lesions: to avoid ablative treatments (e.g. cryotherapy, laser therapy, and so on) on equivocal facial lesions.

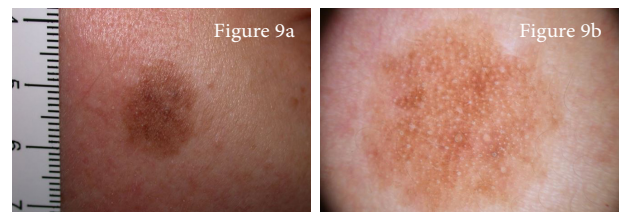


Figure 9a - Solar lentigo

Figure 9b - Solar lentigo (dermoscopy)

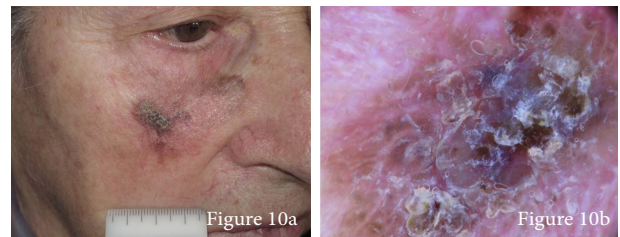


Figure 10a - Lentigo maligna

Figure 10b - Lentigo maligna (dermoscopy)

Dermal nevi and nodular melanoma

Patients often request removal of dermal nevi (figures 11a and 11b) for aesthetic or functional purposes. Dermal nevi can have a heterogeneous clinical presentation ranging from a firm papule to a nodular nodule. Occasionally, it may be difficult to differentiate a dermal nevus from a nodular melanoma (figures 12a and 12b), even more if hypo/amelanotic¹⁰.

Although despite the common lack of pigmentation, dermoscopy can support this distinction on the basis of different vascular structures, since dermal nevi usually

show comma vessels, while melanoma frequently reveal irregular linear vessels. Once again a simple rule to keep in mind is: to excise and have histopathology in doubtful lesions.

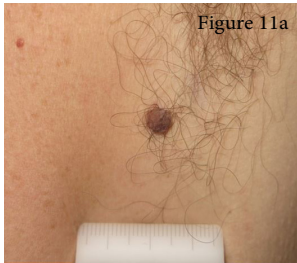


Figure 11a - Dermal nevus

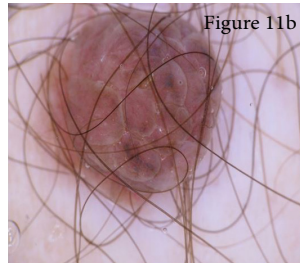


Figure 11b - Dermal nevus (dermoscopy)

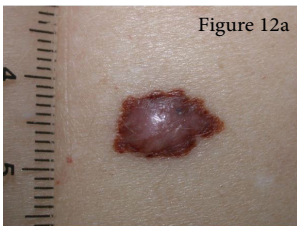

Figure 12a - Nodular melanoma

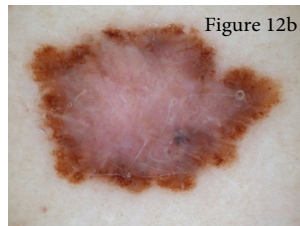


Figure 12b - Nodular melanoma (dermoscopy)

Non melanoma skin cancer

In this wide group of tumours the main actors are basal cell carcinoma (BCC) and squamous cell carcinoma (SCC), although a large variety of different tumours can appear on the skin¹⁰. Clinical presentation of BCC is extremely heterogeneous, ranging from superficial BCC to nodular forms, although plenty of different variants have been described. Non-pigmented BCC usually show at dermoscopy arborizing vessels or fine telangiectasia, ulcerations or multiple small erosions, shiny white-red structureless areas, and short white streaks.

On the other hand, the presence of blue-grey dots/globules, in-focus dots, maple leaf-like areas, spoke wheel areas, concentric structures, and blue-grey ovoid nests are the key dermoscopic features of pigmented BCC. White/red structureless areas are characteristic of infiltrative BCC, whereas whitish background characterizes the sclerodermiform BCC.

Dermoscopy of well-differentiated SCC (figures 13a and 13 b) shows scales, keratin, white areas, and yellow keratotic follicular plugs surrounded by a white circle. Conversely poorly differentiated SCC lack signs of keratinization, revealing a predominant red colour, which is the result of dense vascularity. Surgery is mandatory for nodular BCC and SCC, while alternative treatments (imiquimod, cryotherapy, etc) can be chosen for superficial BCC.

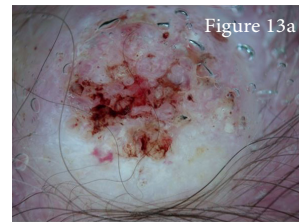


Figure 13a - Squamous cell carcinoma

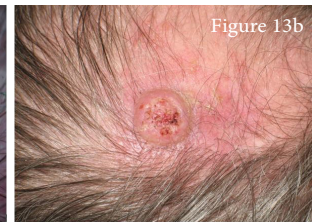

Figure 13b - Squamous cell carcinoma (dermoscopy)

Vascular lesions

The last, but not the least clinical scenario which we face in everyday practice is the distinction between benign vascular lesions of the skin and challenging hypomelanotic melanocytic lesions¹¹⁻¹³.

Clinicians should be aware of this differentiation in order to promptly excise doubtful lesions and send them to the pathologist. Vascular lesions are very common and patients often require their removal.

Among them, cherry angiomas (figures 14a and 14b) are the most frequent and they usually do not show any diagnostic problem. As matter of fact, pyogenic granuloma (PG) (figures 15a and 15b) is a challenging diagnostic pitfall, because it can mimic Spitz nevus and hypomelanotic melanoma. Dermoscopy can be helpful in this difficult task, usually showing in PG vascular lacunae and whitish rail lines, although other dermoscopic features have been described. Conversely, hypopigmented Spitz nevus usually displays dotted vessels and reticular depigmentation. Hypomelanotic melanoma can mimic different lesions, including Spitz nevus and PG, and histopathology is mandatory for the diagnosis.

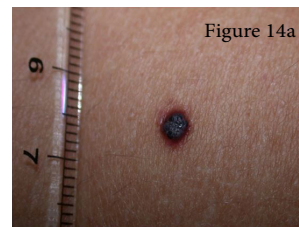


Figure 14a - Angioma

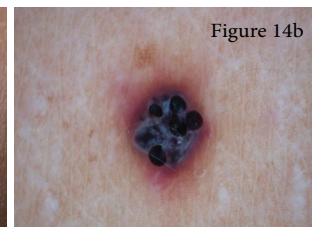


Figure 14b - Angioma (dermoscopy)

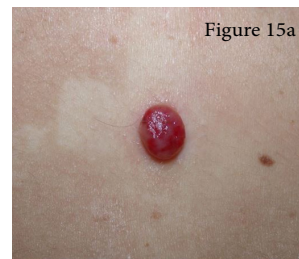

Figure 15a - Pyogenic Granuloma

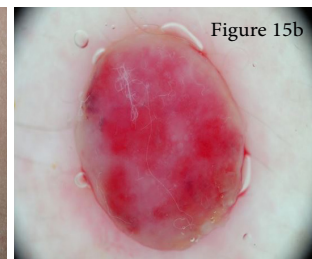


Figure 15b - Pyogenic Granuloma (dermoscopy)

References

1. Jhorr R, Soyery HP, Argenziano G. *Dermoscopy*. USA: Mosby, 2004.
2. Lallas A, Giacomel J, Argenziano G, et al. Dermoscopy in general dermatology: practical tips for the clinician. *Br J Dermatol*. 2014; 170(3):514-26.
3. Lallas A, Zalaudek I, Argenziano G, et al. Dermoscopy in general dermatology. *Dermatol Clin*. 2013; 31(4):679-94.
4. Weismann K, Lorentzen HF. Dermoscopic Color Perspective. *Arch Dermatol*. 2006; 142(9):1250.
5. Argenziano G, Pelleciani G, Zalaudek et al. Triage, diagnosi e gestione pazienti con tumori cutanei: proposta di un modello condiviso. LILT Roma 2011.
6. Fox GN. ABCD-EFG for diagnosis of melanoma. *Clin Exp Dermatol*. 2005; 30(6):707.
7. Braun RP, Rabinovitz HS, Oliviero M, Kopf AW, Saurat JH. Pattern analysis: a two-step procedure for the dermoscopic diagnosis of melanoma. *Clin Dermatol*. 2002; 20(3):236-239.
8. Soyer HP, Argenziano G, Zalaudek, et al. Three-point checklist of dermoscopy. A new screening method for early detection of melanoma. *Dermatology*. 2004; 208(1):27-31.
9. Russo T, Piccolo V, Lallas A, Argenziano G. Recent advances in dermoscopy. *F1000Res*. 2016; 5:F1000 Faculty Rev-184.
10. Russo T, Piccolo V, Lallas A, et al. Dermoscopy of Malignant Skin Tumours: What's New? *Dermatology*. 2017; 233(1):64-73.
11. Baroni A, Piccolo V. Images in clinical medicine. Red melanoma. *N Engl J Med*. 2013; 18;368(16):1536.
12. Piccolo V, Russo T, Mascolo M, Staibano S, Baroni A. Dermoscopic misdiagnosis of melanoma in a patient with targetoid hemosiderotic hemangioma. *J Am Acad Dermatol*. 2014; 71(5):e179-81.
13. Brancaccio G, Russo T, Lallas A, Moscarella E, Agozzino M, Argenziano G. Melanoma: clinical and dermoscopic diagnosis. *G Ital Dermatol Venereol*. 2017; 152(3):213-223.

Cryoadipolysis: a technique that delivers results

Rafael Serena

MD, Serena Clinic, Barcelona

ABSTRACT

Cryoadipolysis is a non-invasive therapy that combines vacuum application and heat extraction for localized adiposity reduction. The possibility to selectively damage the adipocytes reducing subcutaneous fat panicle thickness with no added damage to any other tissues has always been very appealing in aesthetic medicine. Today, too many players compete for this fast growing market but few of them contribute to it with scientific studies. Generating new evidence with the Cooltech® protocol seemed mandatory to us and was the aim of this small series of cases: ultrasound, plicometry and direct measurements were used to assess the clinical results of Cooltech® sessions.

Keywords

Cryoadipolysis, CoolTech®, adiposities, reduction

Correspondence

Rafael Serena, MD
E-mail: rafael.serena@serenaclinic.com

Introduction

Since ancient times, human beings have fought to conceive methods to allow them to reduce the unwanted accumulation of adipose tissue in their own bodies¹. Some of the techniques that are ready and available on the market have proved to be safe and effective for this purpose. One such non-invasive technique is cryoadipolysis². This therapy combines vacuum application and heat extraction for localized adiposity reduction³, with top effectiveness when the adiposities treated are moderate⁴.

The possibility to selectively damage adipocytes with a consequent reduction of subcutaneous fat panicle⁵⁻⁶ and with no added damage to any other tissues has always been very appealing and well accepted by professionals and patients in the aesthetic medicine market. This technique has become established as a safe alternative with proven effectiveness⁷ and minimum complications⁸ when facing a deep lipodystrophy reduction. Today, cryoadipolysis is a treatment that is spreading quickly around the globe⁹.

The theoretical basis' of this procedure were proposed a few years ago³. Pioneering works claimed that fat reduction could result from the local apoptotic adipocyte destruction as a consequence of a heat extraction triggering stimulus³⁻⁴. Apoptotic adipocytolysis as a consequence of intracellular changes was the first and most logical mechanism put forward for this technique. It was assumed that adipocytolysis was a biological consequence of intracellular lipid crystallization¹⁰. Some authors were reluctant to it and suggested that changes could have been better explained by a gel-like transition process rather than by lipid crystallization.

But new knowledge about crystallization vs. lipid-to-gel transition surfaced a couple of years ago and confirmed crystallization as the intimate cause for adipocyte destruction¹¹. In spite of this, and although cryoadipolytic' action is better understood day after day, there is a feeling that its clinical outcome could be improved¹².

At the same time, there is broad consensus in the fact that cryoadipolysis is not a harmful technology, as well as evidence of clinical results being safely achieved without side tissue damage. Still, very little has been said regarding specific issues like the functionality of the adipocytes that remain in the body after the procedure¹³. Efforts were deployed towards better side effects understanding. Some authors¹⁴ analyzed tissue biopsies from patients with remnant post-session hypoaesthesia and showed the absence of structural damage or any changes in peripheral nerve fibers, as well as process reversibility in 100% of cases.

Other studies observed a mild post-session decrease in HDL (not below 4 mg/dl) concomitantly with a moderate increase in serum triglycerides (not over 11 mg/dl), both values normalizing at 12 weeks post-treatment³. Lastly, there have been some reports of

paradoxical adipose hyperplasia (PAH), a rare adverse effect that is getting more and more attention and has even been recently reviewed⁷.

PAH was completely unknown some years ago, probably indicating that its incidence is extremely low. This is under debate for we believe that PAH - though slightly incident - is widely infra-diagnosed.

Truth is that to date only few studies have properly addressed the issue of the adverse effects of this technique, including severe, rare, new and the well-known mild complications that are usually associated with the trauma caused by suction.

Combined, the great interest in cryoadipolysis, the short evidence for the development of new and improved protocols and the lack of information regarding the determinants of its adverse effects, were crucial in motivating some works that tried to assess the frequency of some of the cryoadipolysis adverse effects⁸. Notwithstanding, its' mid- to long-term side effects have not been fully investigated yet.

Though we are running into new evidence every day, for a world-wide massively consumed product as cryoadipolysis, this is not enough.

With too many players competing for the cryoadipolysis growing market but few of them contributing to it with scientific studies, generating new evidence with the Cooltech[®] machine and its protocol seemed mandatory to us and was the aim of this small series of cases.

Material and Method

The sample consisted of 3 volunteer women recruited consecutively between the 1st and the 31st of July 2016, with a mean age of 50 years old (SD 4.36) and a mean BMI of 24.08 Kg/m² (SD 1.64). Follow-up was made for 6 months. This study was performed in accordance to the standards set by the Helsinki Declaration of 1975 and its amendments.

Inclusion criteria were: a) no systemic pathologies, b) not on medication, c) no contraindications for cryoadipolysis application, d) >2cm skin fold in the treatment area and e) a diagnosis of deep lipodystrophy.

Three variables were measured and evaluated: body contour (direct measurement), lower abdominal skin fold (plicometry) and adipose panicle thickness (ultrasound). Standard pictures were also taken.

The treatment involved two sessions separated 2 months from one another. Each session was performed in the lower abdominal area and lasted 70 minutes.

The cryoadipolysis session was performed with Cooltech[®] (Cocoon Medical, Barcleona), using the Oval[®] handpiece and following the Cooltech[®] application protocol, which involved the following sequential steps: Cool Gel[®] application, suction test, Cool Gel Pad[®] placement, CoolTech[®] session. Plicometry was performed with a Harpenden Skinfold Caliper[®]. Every treatment and clinical evaluation was delivered and

carried out by the same personnel. Ultrasound was performed with a General Electric Logic E machine and a lineal multi-frequency 6-12MHz probe. Measurements were taken between 8 and 12 MHz. All tests were performed by the same physician.

Pre- and post-treatment means were compared with a t-Student paired test. Statistical analysis was performed with SPSS version 17 for Windows (IBM Corporation, Armonk, NY, USA).

Results

Body contour assessment (abdominal). Pre-treatment mean: 96.33 cm (SD 7,05); post-treatment mean: 95.00 cm (SD 8.05). *p value*: 0.157 (figure 1).

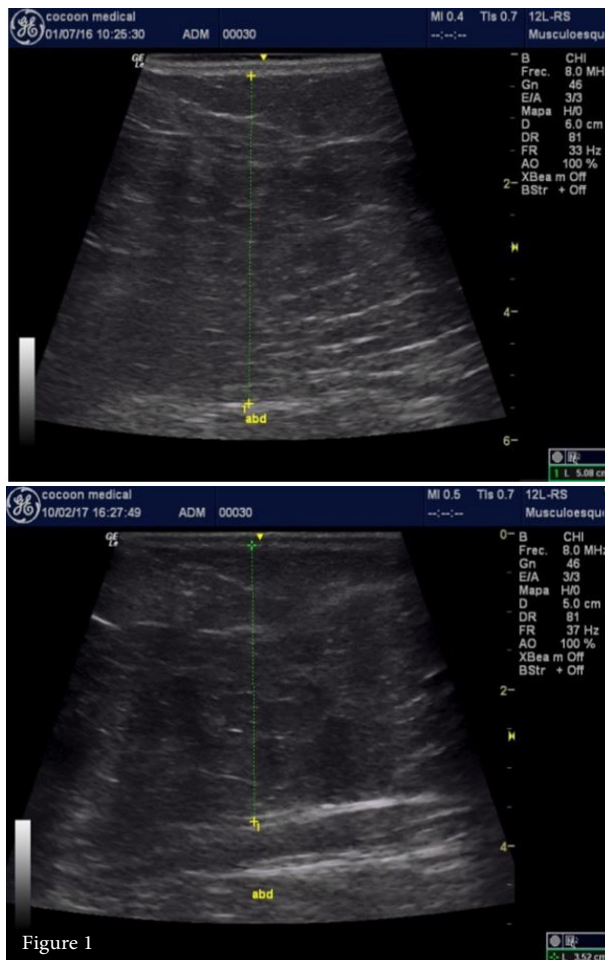


Figure 1 - Ultrasound: pre (up) and post (down) lower abdomen adipose panicle ultrasound

Low abdomen plicometry (skin fold). Pre-treatment mean: 44.00 mm (SD 6.56); post-treatment mean: 34.02 mm (SD 1.01). *p value*: 0.102. Low abdomen adipose panicle thickness measurement (ultrasound).

Pre-treatment mean: 3.10 (1.77) cm. Post-treatment mean: 2.25 (1.15) cm. *p value*: 0.269.

Discussion

No ambitious conclusions can truly be made from such a small series of cases ($n= 3$). This extremely low n and an anecdotic important dispersion of the sample necessarily implied *p values* > 0.05.

In addition to these, a 6-month follow-up made things even more complicated, making the appearance of weight fluctuations more probable. As foreseen, they were observed during control visits and compromised a proper clinical evaluation even further.

A special mention is for ultrasound, for it is the gold standard technique for fat panicle thickness assessment. When comparing pre and post treatment measurements, the two-tailed *p value* equaled 0.2691. By conventional criteria, this difference is considered to be not statistically significant.

This fact is not surprising at all when the characteristics of the small and dispersed sample are considered (figure 2).

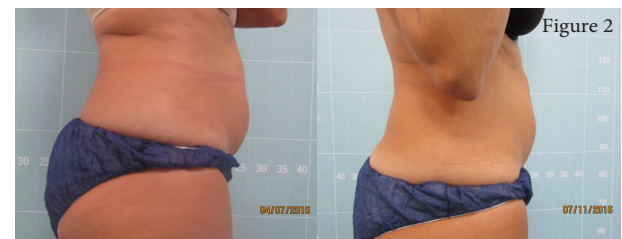

Figure 2 - Clinical effectiveness: pre (left) and post (right) lower abdomen picture. Arrows show abdominal reduction after Cryoadipolysis with Cooltech* protocol

Still, the reduction we saw in the lower abdominal fat layer accounted for a mean 27.4%. This is a very important and promising reduction and is exactly the type of event we were expecting to see. Further research with larger samples must be conducted to be able to extrapolate these findings to the general population.

Cryoadipolysis is an effective and very well-established technique. Cooltech® protocol is revealing its potential as the effectiveness and patient satisfaction empiricism grows thick. In the near future, technological improvements will allow physicians to submit adipocytes to cooler temperatures and provide better results.

Disclosure: none.

Acknowledgements: the author would like to thank the i2e3 medical writing team.

References

1. Pinto HR, Garcia-Cruz E, Melamed GE. Study to evaluate the action of lipocryolysis. *Cryo Letters*. 2012; 33(3):176-80.
2. Nelson AA, Wasserman D, Avram MM. Cryolipolysis for reduction of excess adipose tissue. *Semin Cutan Med Surg*. 2009; 28(4):244-9.
3. Manstein D, Laubach H, Watanabe K, Farinelli W, Zurakowski D, Anderson RR. Selective cryolysis: a novel method of non-invasive fat reduction. *Lasers Surg Med*. 2008; 40(9):595-604.
4. Avram MM, Harry RS. Cryolipolysis for subcutaneous fat layer reduction. *Lasers Surg Med*. 2009; 41(10):703-8.
5. Preciado JA, Allison JW. The effect of cold exposure on adipocytes: examining a novel method for the non-invasive removal of fat. *Cryobiology*. 2008; 57:327.
6. Klein KB, Zelickson B, Riopelle JG, et al. Non-invasive cryolipolysis for subcutaneous fat reduction does not affect serum lipid levels or liver function tests. *Lasers Surg Med*. 2009; 41(10):785-90.
7. Ho D, Jagdeo J. A Systematic Review of Paradoxical Adipose Hyperplasia (PAH) Post-Cryolipolysis. *J Drugs Dermatol*. 2017; 16(1):62-7.
8. Vidal R, Segura L, Vergara P, Pinto H. Adverse effects of lipocryolysis: analysis of 28 cases. *J Surg*. 2015; 3(1-1):6-7.
9. Pinto H, Arredondo E, Ricart-Jané D. Study for the evaluation of adipocytic changes after a simillipocryolysis stimulus. *Cryo Letters*. 2013; 34(1):100-5.
10. Pinto H, Ricart-Jané D, Pardina E. X-ray diffraction analysis confirms intra-adipocitary lipid crystallization after a lipocryolysis-like stimulus. *Cryo Letters*. 2013; 34(6):619-23.
11. Pinto H, Melamed G. Contrast lipocryolysis pre- and post-session tempering improves clinical results. *Adipocyte*. 2014; 3(3):212-4.
12. Pinto H, Pardina E, Ricart-Jané D, Melamed G. Cooling speed affects adipocyte survival. *Journal of Surgery*. 2015; 3(1-1):11-3.
13. Pinto H, Ricart-Jané D, Pardina E. Isolated Rat Adipocytes are still Capable of Inducing Lipolysis after a Lipocryolysis-like Thermic Stimulus. *Journal Glyc&Lipidomics*. 2014; 4(4).
14. Coleman S, Sachdeva K, Egbert B, Preciado JA, Allison J. Clinical Efficacy of NonInvasiveCryolipolysis™ and its Effects on Peripheral Nerves. *Aesthetic Plast Surg*. 2009; 33:482-8.

Height enhancement using hyaluronic acid and minimally invasive technique

Dario Martusciello

MD, Aesthetic and maxillofacial physician in private practice, Napoli - Via Chiatamone no. 23, 80125 Napoli, Italia

ABSTRACT

Height increase is a very important social demand, currently the only valid method to achieve this objective is the Ilizarov technique.

The long-stay treatment and the high costs have restricted this valid technique only to ultra-specialized centres and to strongly convinced and motivated patients. Through this study of 21 patients from 2015 to 2016 we tried to achieve a protocol based on a minimally invasive approach. In fact, through careful study of foot anatomy, the choice of a thixotropic and easily manageable material, short recovery time, low costs, patient safety, it is possible to achieve a height increase of 2 to 3.8 cm both for aesthetic purposes and correction of light heterometry and associated pathologies.

This is feasible through infiltration of a macromolecular hyaluronic acid in a clearly-defined anatomical space able to increase height without side effects on ambulation.

Keywords

Height augmentation, hyaluronic acid filler, non invasive procedure aesthetics, innovative approach

Correspondence

Dario Martusciello, MD, Centro DAMA,
Via Chiatamone, 23 - 80125 Napoli, Italia
E-mail: dottordariomartusciello@gmail.com

Introduction

All those having a lower than average height are always willing to know how to increase their height without resorting to dramatic surgery¹⁻². Taller people have always been considered more attractive for their partners and height has always been considered an attractive feature.

Social discrimination in case of height lower than average is a real and well known condition for the affected individuals and is also a great psychological stress disrupting work, emotional and social relationships³.

For example, if we observe several subjects and professional fields, we see that a specific minimum height is required and this prevents many aspiring sportsmen or sportswomen, dancers, potential candidates for army special forces, top models, etc. from being able to realize their ambitions⁴.

Due to those reasons, acting on the individual sphere of acceptance of human beings, there is the need for researching and implementing surgical techniques in order to change that disabling condition at different stages. This widespread need of women and men of different age and different social backgrounds, seems to have no specific solutions using minimally invasive aesthetic treatments.

Nowadays, the only valid and effective one is the "Ilizarov" technique using the principle of post-distraction osteogenesis with exoskeleton of metal rings or semi-rings and actually resulting in lengthening of the femoral and/or tibial, peroneal bones⁵.

The morbidity of the procedure and complications, the long-stay treatment and the high costs have restricted this valid method only to ultra-specialized centres and to strongly convinced and motivated patients who opt for this procedure⁶.

In addition to the above-mentioned considerations, there is a need to overcome those problems connected to the procedure which is the only currently available solution.

Hence, this study focuses on a minimally invasive technique using resorbable materials which fully complies with individual physical safety and the widespread natural trend all around the world.

The goal of this research is to standardize a minimally invasive technique assuring minimum height lengthening (2-4 cm) with short convalescence (about 7 days), consequently resuming daily activities both at work and social, and reasonable costs for a larger number of patients.

Such method is indicated not only for aesthetic purposes but also recommended for widespread diseases such as heterometry ranging from 0.5 to 1.5 cm. 70% of global population is affected by the disease and express pain from non-clearly defined symptoms coming from the muscles' forced contraction for the purpose of stabilizing spinal heterometry⁷.

Material and methods

This study was carried out from 2014 to 2016 assessing 21 patients: 17 women and 4 men, whose age ranges from 25 to 36 year old, (average of 27) and related height from 1.58 to 1.72m with average of 1.68. BMI (Body Mass Index) ranging from 19 to 24.5 (average 21.38).

Criteria for inclusion were:

- Lack of immunosuppressive disorders;
- Lack of diabetes and lymphatic drainage system deficit of lower limbs;
- Low or no tobacco use;
- Lack of significant allergies;
- Previous aesthetics medicine treatments using filler injections of hyaluronic acid;
- Activity: indicating daily walking: poor less than 40min daily; medium about 1 hour a day; common between 1 and two hours a day;
- BMI ranging from 19 to 24.5 (table 1).

A macromolecular hyaluronic acid, HAC-20, was used to perform this study.

Chemical composition of 1 ml of HAC-20 includes:

- Reticulated sodium hyaluronate (Hyan Gel) 20 mg;
- Free sodium hyaluronate 20 mg;
- Sodium Chloride 6.9 mg;
- Water for injections 1 ml.

We used a specific platform (OSG BAT) for barometric assessments.

- Ultrasound scanning was used both pre and post treatment (mylab 25 gold ESAOTE scan with linear probe);
- All measurements were done using the metric system;
- During the post-treatment stage, BAUER silicone insoles were placed in order to minimize stress load in the implantation area.

The prescribed home treatment considers:

Pre-treatment: morphine-based drugs such as Targin 5 mg (2 tab for 3 days before treatment).

Post-treatment:

Painkillers: the dosage of Targin 5 mg was increased to 4 tablets per day, 1 in the morning, 1 after lunch, and 2 before sleeping. The treatment may also include Toradol if needed.

Antibiotic treatment: background treatment of Cefixoral 400 mg, tablet per day for 7 days.

Anti-inflammatory and anti-oedema treatments: this treatment is essential because pain is associated to the distraction degree of the vascular-nervous peduncle of the heel. We administered Seractil 400 mg after the

Patients	Bmi	Activity	Smoke	Gender	Height before treatment (m)
25	19	poor	no	f	1.58
26	19,2	poor	5	f	1.60
28	19	common	2	f	1.62
29	23,2	poor	10	m	1.65
32	24,9	poor	no	m	1.71
36	22,6	poor	10	f	1.67
35	19,2	medium	no	f	1.59
28	20	medium	8	f	1.60
29	19,5	poor	10	f	1.65
25	23,5	common	10	f	1.72
26	24,5	poor	10	m	1.70
34	21,6	common	10	f	1.63
33	19,8	poor	no	f	1.61
30	23,1	medium	no	f	1.63
29	20,1	common	8	f	1.60
28	20,9	medium	5	f	1.64
27	19	poor	2	f	1.66
31	20	poor	no	f	1.69
26	23,4	common	no	m	1.62
29	23,6	medium	no	f	1.70
34	22,9	medium	no	f	1.72

Table 1 - Characteristics of patients before treatment

main meals for one week. Rehabilitating treatment: the silicone insoles were used by the patients to reduce direct trauma on heels. Moreover, the rehabilitating treatment, consisting of early walking, is recommended to activate lymphatic drainage of the foot, and reduce swelling and connected pain, and also to avoid embolism.

Description of technique

Before starting a careful study of the patient was performed. The height, weight, and postural/ barometric assessment were measured. This was essential in order to correctly define the posture of the patients and to check for any alteration of the posture and its extent. The measurement of the fibre-adipose panniculus of the heel was taken by an echo-ultrasound system. The fibre-adipose tissue is found above the surface of the calcaneus, it consists of hyperkeratotic tissue and its development is proportionally inverse to the degree of tissue elasticity and expandability. The assessment of its thickness is critical because its size is correlated to

the degree of expandability of the tissue and to its ability to hold lower or higher quantity of hyaluronic acid: therefore, to sum up, it defines the patient's potential to increase in height. This procedure is followed by localization of the medial tibial neurovascular pedicle (figure 1) in order to perform an anaesthetic block that is made taking advantage of the ultrasound-guided system. Once the neurovascular pedicle is identified, anaesthesia is performed injecting 0.5 ml of lidocaine with a 12 mm 33 G needle (figure 2).

Additional anaesthesia is performed by randomly injecting 1.5 ml of lidocaine in the region of the treatment area (figure 3). The area concerned extends from the cutaneous projection of the calcaneus posterior edge to the imaginary line which transversally divides the heel into two sections. The area was identified considering that at this stage, the aponeurotic fascia is less represented. Consequently there are lower possibilities to damage or to accidentally inject the product under the fascia, causing difficulties in walking. The macromolecular hyaluronic acid was infiltrated through different injections from the proximal margin of that area to its caudal margin, through a 1 cc Luer Lock syringe with a

27 G and 40 mm long cannula, in different quantities patient by patient, inside a virtual space, the so-called “Martusciello pouch”, a space located between the upper fascial bone structure and the fibre-adipose tissue of the heel (figure 4). Infiltration was made using ultrasound-guided support (figure 5).

Introduction of macromolecular hyaluronic acid inside this virtual space (figure 6) was prolonged until it reached the stage of “maximum tumescence”, obtained when the material leaked out during injection from a different access hole that was prepared in the same area. Immediately post-treatment, the correct position of the implanted material is assessed by a postural/ barometric test.

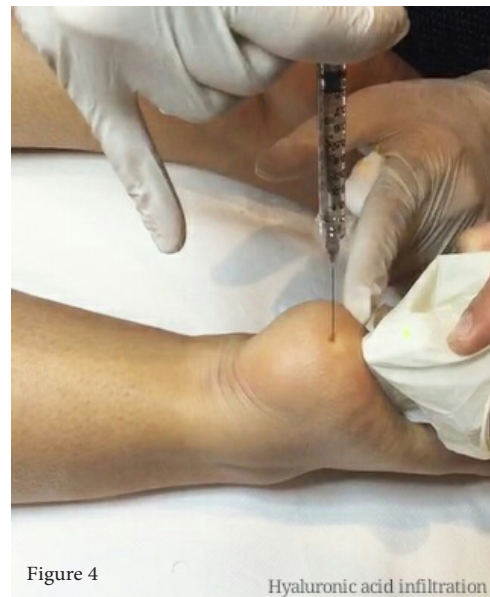

Figure 4

Hyaluronic acid infiltration

Figure 4 - Infiltration made using ultrasound-guided procedure

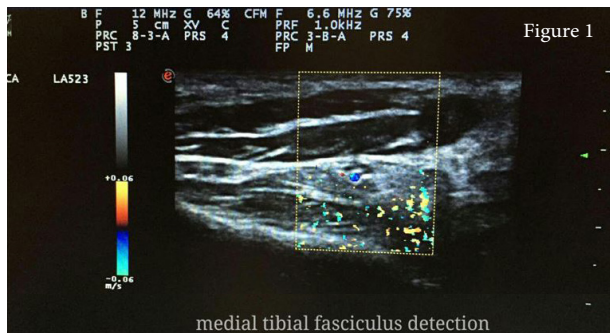


Figure 1

medial tibial fasciculus detection

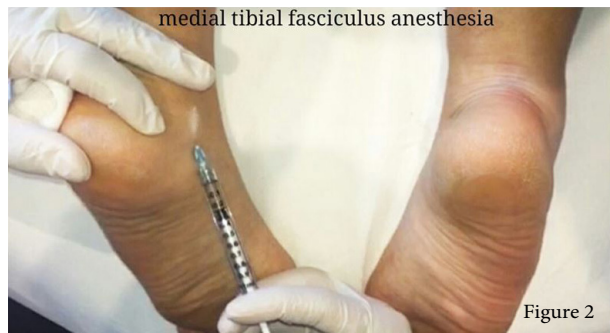
Figure 1 - Detection of the medial tibial neurovascular pedicle

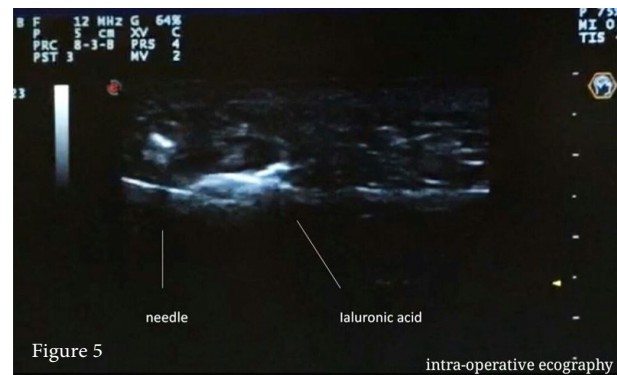

Figure 5

intra-operative ecography

Figure 5 - Infiltration inside the “Martusciello pouch” using the ultrasound-guided support



medial tibial fasciculus anesthesia

Figure 2

Figure 2 - Anaesthesia on medial tibial neurovascular fasciculus

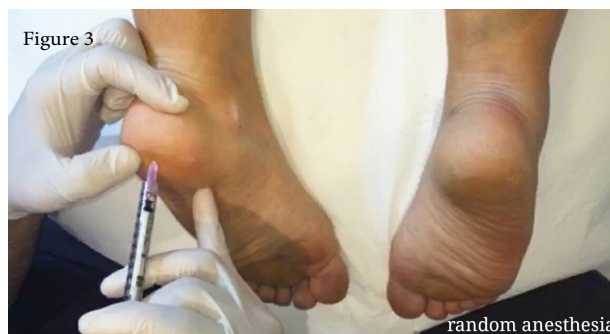

Figure 3

random anaesthesia

Figure 3 - Random anaesthesia

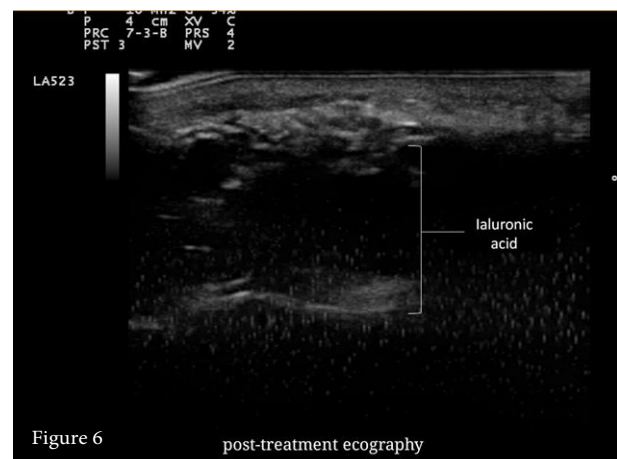


Figure 6

post-treatment ecography

Figure 6 - Complete introduction of the macromolecular hyaluronic acid

Results

Results highlighted an instant increase in the patient’s height, observed also in frontal (figures 7 and 8) and posterior view (figures 9 and 10), variable from 2.2 cm to 3.8 cm (tables 2 and 3).

In order to reach an average improvement of 1 cm height, 3.5 cc of macromolecular hyaluronic acid is needed. There is no evidence of correlations between the quantity of the injected product and a larger degree of resorption.

Rather, resorption seems to be directly related to the basal metabolism, to the patient’s features and to the daily activity on the plantar area: running, walking, or sports. The average degree of satisfaction of the patients after the treatment was 3.8 assessed with a numeric scale ranging from 1 (not sufficient) to 5 (very satisfactory).

Follow up was planned at 1 week; 1, 3 and 6 months; 1 year.

During the follow-up, no migration of the implants outside Martusciello’s pouch was observed in all the patients, assessed using the ultrasound system.

At one year follow-up, the average detected degree of resorption measured was 1cm; with measures included between 0,7 and 1.5cm.

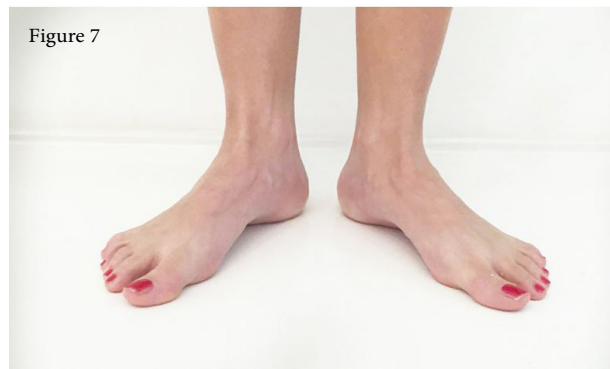

Figure 7 - Pre-treatment in posterior view

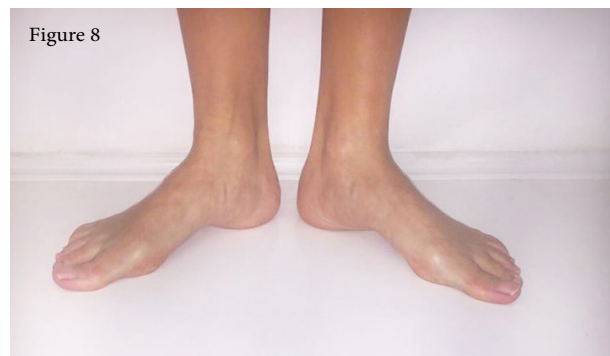

Figure 8 - Post-treatment in front view

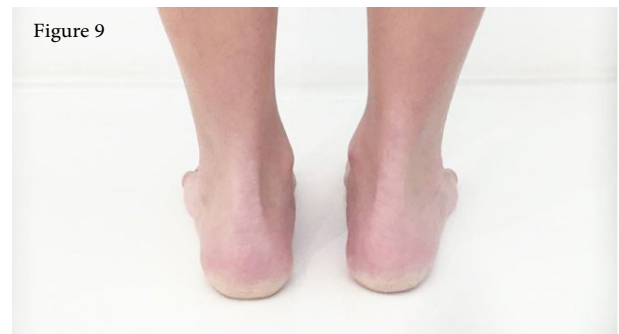

Figure 9 - Pre-treatment in posterior view

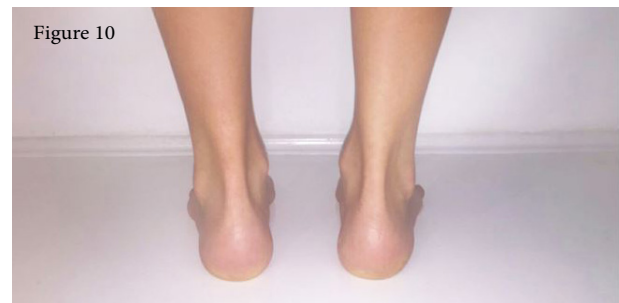

Figure 10 - Post-treatment in posterior view

Patients N°	PAIN
1	3
2	4
3	3
4	4
5	5
6	5
7	4
8	3
9	4
10	3
11	4
12	3
13	3
14	3
15	5
16	4
17	4
18	4
19	4
20	3

Table 2 - Reported pain assessment. Range is between 0, no pain, and 5, very painful

PZ	1	2	3	4	5	6	7	8	9	10	11	12	13	14	15	16	17	18	19	20	21
Height fibre-adipose panniculus (cm)	0,8	1,0	0,9	1,4	1,3	1,2	0,9	1,0	0,9	1,1	1,4	1,0	0,8	0,9	1,0	1,1	1,1	1,1	1,4	1,2	1,4
Height obtained (cm)	3,6	3,4	3,2	2,2	2,5	2,7	3,8	3,7	3,5	2,7	2,2	3,5	3,8	3,3	3,5	3,1	3,2	2,9	2,6	2,8	2,8

Table 3 - Relationship between the height of fibre-adipose panniculus and the height obtained

Observed complications

No major complications were detected during the follow-up period. Some feared complications were: necrosis in the treatment area, infection, paraesthesia or anaesthesia, posture alterations, alteration of the skeletal structure; none of those mentioned occurred.

Pain was assessed by a numeric pain assessment scale, which ranged from 0 (no pain) to 5 (very painful). Patient's assessment revealed an average measure of 3.7 immediately post-treatment. Pain arises from the momentary distraction of the medial tibial vascular nervous pedicle, due to the macromolecular hyaluronic acid injection and from tissue expansion, related to osmotic withdrawal of the hyaluronic acid. After one-month the follow-up showed that 2 patients, the first ones treated, (not included in the final assessment), showed a leak of hyaluronic acid from the site, the Martusciello pouch, that developed into a subcutaneous vesicle, painless in orthostatic and supine position and also while walking (figure 11). Such complication is due to leak of the gel, filled out from the access hole that for the first two patients was performed using a 16 G needle, in order to create an input hole, and a 25 G and 40 mm long cannula. This caused a "funnel effect" which resulted in the material being ejected through the only access under load pressure. Such problem was addressed using a multiple-hole technique and 27 G thinner needles, in order to distribute the load pressure over a larger area.

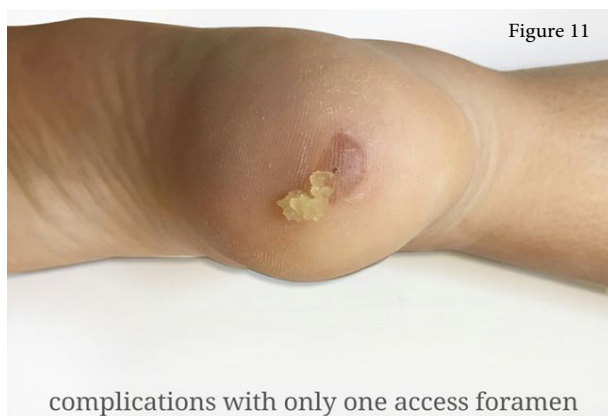

Figure 11 - Leak of the filler out from the only access hole

Discussion

The request for treatments to extend the lower limbs or to make them symmetric has strongly increased in the last few years. To obtain such result, the only well-known technique consist in the Lizarov's technique⁸ that currently may be indicated for several diseases such as osteomyelitis, heterometry greater than 2 cm, to correct posture deviations and for achondroplasia. This technique makes it possible to achieve lengthening of the lower limbs up to 10 cm. The Russian lizarov technique is based on distraction osteogenesis that uses a flexible exoskeleton. The daily degree of bone growth ranges from 1 to 2 mm. It has been estimated to result in new complete bone formation of about 1 cm per month⁹. The main complications of this procedure are: nervous aplasia, damage on tendons, malunion of the bone segments, articular rigidity¹⁰. Minor complications are: infection of the bone stump, oedema, transitory paraesthesia. The high risk of complications connected with the high costs of the technique¹¹ including a specific and considerable convalescence time, mean the technique is not suitable for aesthetic purposes¹², making this type of surgery practicable only in few and specialized centres with very motivated patients fully aware of the possible complications¹³⁻¹⁴. The search for a simpler method started with the aim to standardize a simple technique, that was able to correct slight heterometry ranging from 0.5 to 1.5 cm, easy to use to make it suitable for aesthetic purposes. To make it possible, we needed to find an appropriate, distinctive hyaluronic acid¹⁵⁻¹⁶⁻¹⁷ that was able to be strong enough to withstand the load yet able to easily flow through small needles to prevent trauma during infiltration. We found the features we sought in a specific product, strong enough to withstand due to its macromolecular structure consisting of 800um particles and able to easily flow trough the needle. This property is due to its production technology, that is so-called THIXOTROPY which indicates the ability to become fluid under pressure and immediately going back to its original viscosity within the tissues. This feature is linked to a system that shows a decrease in viscosity when the percentage of applied force represented by the exerted load pressure is increased. This feature may result in

excellent implant stabilization without hyaluronic acid migration. Indeed, one of the main problems connected with administration of resorbable materials in the calcaneal area, is the migration of the product toward the plantar fascia, leading to more or less serious disorders when walking. Furthermore, in order to prevent damage to the plantar fascia, such infiltration technique was designed to consider the position of the implant in a specific area where the fascia is less notable. The scan-guided support makes it possible to perfectly and properly locate the plane between the plantar fascia and the fibre-adipose panniculus, inside that virtual space that we called "Martusciello pouch". Single access with 16 G needle or with cannula was avoided in order to prevent the product from leaking out at a later stage, under load pressure, moreover the large size of the molecules in association with their high degree of cohesiveness assures slower degradation and longer stability of the outcome. Hyaluronic acid was chosen in consideration of the fact that it should enzymatically degrade (hyaluronidase)¹⁸⁻¹⁹⁻²⁰ if any problems occur after its inoculation and migration on the plantar fascia²¹⁻²². It also focuses on the patient's safety, considering that vascular support of the heel is a terminal one and that it depend on the vessels' blood flow provided by the medial tibial area²³. In order to prevent post-treatment vascular disorders, paraesthesia or anaesthesia from excessive distraction of the peduncle, the "maximum swelling" stage was avoided. Such stage is reached when a leak of hyaluronic acid is observed, during the implant procedure from another access hole. This is the maximum degree of expandability, for a single treatment session, of the fibre-adipose panniculus. Such anatomical structure mainly consists of hyperkeratotic tissue which increases when the load pressure rises, or when the body weight increases, or due to mechanical stimulus on the heels such as intensive sports activity. Furthermore, ageing is also responsible for its augmentation. The echo-guided study of said fibre-adipose panniculus thickness during the pre-treatment stage, lets one understand its degree of expandability and consequently the ability to receive a smaller or larger quantity of hyaluronic acid inside the "Martusciello pouch". As a consequence, this makes it possible to understand the degree to which the patient is able to improve their height by keeping within the safety range, that is below the maximum swelling stage. We have found a reverse trend of gain between the size of the panniculus and its capacity, considering that when treating a 9mm-high fibre-adipose panniculus, the most significant increase was 3.8 mm, while treating a 14/15mm-high fibre-adipose panniculus, this gain decreased to 2.2 / 2.5 cm (table 3).

Conclusions

This study finally gives the opportunity to achieve the specific goal of increasing height using a minimally

invasive technique that can be used for aesthetic purposes, while treating light heterometry as well. One week of convalescence is enough before rapidly resuming social life. The filler implant was well accepted by patients and assured immediate verifiability of the outcome (table 3).

References

1. National Health Statistics Reports, Number 10, (October 22, 2008).
2. Lineamenti di Antropologia per le scienze motorie, di B. Chiarelli, R. Bigazzi e L. Sineo.
3. Pineau JC, Delamarche P, Bozinovic S. Average height of adolescents in the Dinaric Alps. *C R Biol*. 2005; 328:841-6.
4. Cassazione 23562/2007: Altezza minima per uomini e donne, di Avv. Hermans Joseph Iezzoni.
5. Aronson J, Harrison BH, Stewart CL, Harp JH Jr. The histology of distraction osteogenesis using different external fixators. *Clin Orthop Relat Res*. 1989; 241:106-116.
6. Wagner H. Operative lengthening of the femur. *Clin Orthop Relat Res*. 1978; 136:125-42.
7. Bartolozzi P, Pratelli R, Barneschi G. Heterometry of the lower limbs: clinico-statistical findings on the incidence and correlation with lumbago symptoms. *Arch Putti Chir Organi Mov*. 1989; 37(2):317-24.
8. Simard S, Marchant M, Mencio, G. The Ilizarov procedure: limb lengthening and its implications. *Phys Ther*. 1992; 72(1):25-34.
9. Ilizarov GA. The tension-stress effect on the genesis and growth of tissues: Part II. The influence of the rate and frequency of distraction. *Clin Orthop Relat Res*. 1989; 239:263-285.
10. Reinker KA. CORR Insights: cosmetic lower limb lengthening clinic orby ilizarov apparatus: what are the risks? *Clin Orthop Relat Res*. 2014; 472(11):3557-3558.
11. Paley D. Problems, obstacles, and complications of limb lengthening by the ilizarov technique. *Clin Orthop Relat Res*. 1990; 250:81-104.
12. Rose RE. Femoral lengthening using the ilizarov technique. *West Indian Med J*. 2006; 55(6) 420-424.
13. Popova, L. A. & Khodosevich, N. I. (1984) Ilizarov Method in Science and Practice: It's Economic and Social Significance. In: Transosseous Compression-Distraction Osteosynthesis in Trauma and Orthopaedics. Kurgan. pp 63-68.
14. Arron AD, Eilert RE. Results of the Wagner and Ilizarov methods of limb-lengthening. *J Bone Joint Surg Am*. 1996; 78(1):20-9.
15. Wayne Carman. Encyclopedia of Aesthetic Rejuvenation Through Volume Enhancement. *Aesthet Surg J*. 2016; 36(1):NP43-NP44.

16. Friedman PM, Mafong EA, Kauvar AN, Geronemus RG. Safety data of injectable nonanimal stabilized hyaluronic acid gel for soft tissue augmentation. *Dermatol Surg.* 2002; 28(6):491-494.
17. Matarasso SL. Understanding and using hyaluronic acid. *Aesthet Surg J.* 2004; 24(4):361-364.
18. Cohen JL. Understanding, avoiding, and managing dermal filler complications. *Dermatol Surg.* 2008; 34 Suppl 1:S92-S94.
19. Brody HJ. Use of hyaluronidase in the treatment of granulomatous hyaluronic acid reaction or unwanted hyaluronic acid misplacement. 2005; 31(8 pt 1):893-897.
20. Cavallini M, Gazzola R, Metalla M, Vaienti L. The role of hyaluronidase in the treatment of complications from hyaluronic acid dermal fillers. *Aesthet Surg J.* 2013; 33(8):1167-74.
21. Pecharki D, Petersen FC, Scheie AA. Role of hyaluronidase in *Streptococcus intermedius* biofilm. *Microbiology.* 2008; 154(Pt 3):932-938.
22. De Boulle K. Management of complications after implantation of fillers. *J Cosmet Dermatol.* 2004; 3(1):2-15.
23. DeLorenzi C. Complications of injectable fillers, part 2: vascular complications. *Aesthet Surg J.* 2014; 34(4):584-600.

Efficacy of a phytotherapeutic preparation on professional activities of nurses in an Italian hospital

Alberto Garavello¹, Ugo Alonzo²

¹MD, Center for ulcer therapy. Department of Emergency Surgery, San Filippo Neri Hospital - Via Martinotti 20, Roma

²MD, Past President SIFL

ABSTRACT

Background: CEAP class 1 patients often report heaviness, cramps and paresthesias of the lower limbs, which often does not find an adequate solution. Phlebotonic drugs usually are prescribed but not always solve the problem.

Methods: The authors tested the effectiveness of a phytotherapeutic preparation in a particularly “at-risk” category for venous disease: the female nursing staff. 50 class CEAP 1 patients were selected for this study; they were administered two tablets/day of a preparation based on “Rusco” and Curcuma” (Eudren*) for a period of 15 days, as “short-term therapy”. The symptoms were “heaviness” in 50 pts., “cramps” in 23 pts., “paresthesias” in 16 pts.

Results: At a 15-day control a positive result was obtained in 74% (37 pts.) of cases for “heaviness”, in 78% (18 pts.) for “cramps” and 81% (13 pts.) for paresthesias. 5 pts. discontinued the therapy for various reasons.

Conclusions: In class CEAP 1 patients we can get satisfactory results with a “short-term” therapy even in patients who perform demanding physical activity in a prolonged standing position like nurses.

Keywords

Drugs, varicose veins, nurses

Correspondence

Alberto Garavello, MD
Via Manfredi Azzarita, 41 - 00189 Roma
Phone: +39 335 5357073

Introduction

The CEAP class 1 includes patients with cutaneous defects like spider veins and reticular varicosities, often associated with heaviness, cramping and paresthesias in the lower limbs¹. This is a very common problem that is often unsolved; sometimes there are orthopedic or postural problems that worsen the symptomatology, while echolor Doppler examination shows no reflux in superficial and/or deep circulation but only small varicosities.

Generally, the patient is dismissed with the prescription of phlebotonic drugs and the recommendation to wear elastic stockings; however these measures are not always successful sometimes to a multifactorial etiopathogenesis of the leg problems. The most important risk factors for vein diseases are female gender, a job in a prolonged standing position, pregnancies², obesity and a history of varicose vein diseases³. Nurses are particularly susceptible to these conditions so we decided to propose a herbal preparation to a selected population of CEAP 1 class health operators of the San Filippo Neri hospital in Rome, to assess the effectiveness on leg symptoms while on duty. It was a "short-term" study for a period of two weeks; the Authors evaluated the efficacy of the preparation on the symptoms during working hours.

Material and methods

Among nurses of the San Filippo Neri hospital in Rome, which on a preliminary interview reported symptoms attributable to a venous disease of the legs, we selected 50 CEAP 1 class patients. Informed consent was asked in order to participate in the study; purpose and method of the research were explained to all the participants as well as the composition and the therapeutic effects of the herbal preparation (Eudren* RPF Salerno-Italy, see table 1) with phlebotonic, anti-oedema, anti-inflammatory and diuretic action, together with contrast to free radicals. In table 1 we summarised the components of the preparation and the mg. of active substance contained in each tablet.

Patients selection was performed with anamnesis, physical examination and EchoColorDoppler ultrasound for evidence of pathology of the superficial and or deep venous system; the examination was performed with the patient in the upright position, scanning the sapheno-popliteal and sapheno-femoral junction, and the deep venous system, using the usual compression and squeezing maneuvers.

The study included patients regardless of age, excluding those who had taken phlebotropic drugs in the month prior to selection, pregnant or suffering from medical disabling conditions; the phlebotonic drug was administered at a dose of 2 tablets/day for two weeks to test the effectiveness of a short-term therapy. At the end of the study the patients were

asked about the effects on daily working activities by means of a questionnaire and the results was classified as:

- Excellent: total disappearance of symptoms;
- Good: significant improvement of symptoms with benefits during the working day;
- Moderate: only small improvement during the working day;
- No improvement;
- Discontinuation of the therapy.

Composition of herbal preparation "Eudren"*	mg/cps
Ruscus aculeatus root	120
Curcuma longa root	20
Ippocastano cortex	50
Solidago Virga Aurea	110
Mosto d'uva Jaquez	20
Pino marittimo Francese Cortex	3

Table 1 - Composition of herbal preparation "Eudren"*

Results

The characteristics of the patients of the examined sample are summarised in table 2.

The symptoms reported consisted in 50 cases of "heaviness" of the limbs at the end of the working day, in "cramps" in 23 patients and in 16 patients in a "paresthesia" and "burning sensation" in the legs.

In table 3 we specify the department of the patients enrolled in our study.

In the table 4 we listed the results of the two-week control; 5 patients discontinued therapy prematurely because of difficulties in swallowing the tablets, one for forgetfulness and three because of the occurrence of an influenza syndrome.

Age	min. 31 max. 63 mean 48
BMI<30	10 pts.
Estrogen therapy	3 pts.
Orthopaedic problems	hallux valgus; 8 pts.
	flat foot; 4 pts.
	knee valgus; 2 pts.
	hip osteoarthritis; 2 pts.
	Spine osteoarthritis; 2 pts.
Menopause	20 pts.
Elastic Stocking	14 pts.

Table 2 - Patient's clinical history

Job position of nurses joining the study	N°
Outpatient	10 pts.
Emergency room	9 pts.
Operating theatre	8 pts.
Ward	8 pts.
Auxiliary Personnel	6 pts.
Intensive Care	6 pts.
Physiotherapy	3 pts.

Table 3 - Job position of nurses joining the study

Symptom improvement	Excellent	Good	Moderate	Any
Heaviness	26	11	3	6
Cramps	15	3	3	2
Paresthesia	10	3	-	3

Table 4 - Two-week therapy results

Discussion

The CEAP class 1 patients represent a large part of the daily work of the phlebologist - often symptoms such heaviness and cramps are the main reason for the exam, together with the need to perform sclerotherapy or laser treatment of spider veins.

For our study we identified the most critical conditions; female patients with a physically demanding working activity in the upright position for most of the time.

This is why we chose the nursing staff of our hospital, a category of professionals who present the largest number of risk factors for varicose veins, as well as for an easier follow-up.

Some researchers observed that a varicose vein disease is present in 34% of hospital workers, especially among those in a prolonged standing position⁴; besides our investigation we believe that this evidence should lead to putting together prevention programs, especially now as the average age of nurses in Italy is rapidly increasing.

Prevention of varicose vein disease is mandatory for these professionals; only 14 of the patients included in our study routinely wore elastic stockings, with occasional use in 3, which shows the lack of attention to the problem despite the presence of subjective symptoms. This job is at high risk for varicose veins, particularly in women where incidence is higher than in men (77.9% vs 56.9%), while other contributing factors are represented by years of service and Body Mass Index^{5,6}. It is well known that the prolonged standing position represents a risk factor for varicose veins⁷; a survey carried out among hairdressers showed that in

these professionals - aged over 45 years - working for more than 260 hours per month standing and more than 30 years of service represent risk factors, while in those less than 45 years old inheritance seems mainly responsible⁸. Some authors have found that leg symptoms become more frequent upon increasing age^{9,10,11,7}; the risk of venous insufficiency increases with age, triples over 50 years while women complain of leg problems up to 3 times more than men¹².

In the patients included in our study, the average age was 48 years, with 28 patients older than 50 years, the latter are in a "critical zone" where we can see most of the risk factors among those mentioned above. Pregnancy has been shown to be associated with diseases of the venous system and this may explain the prevalence of varicose diseases in females²; among our 20 menopausal patients only 3 were on estrogen therapy. Obesity also contributes to the appearance of subjective complaints of lower limb conditions more in women than in men; in our series 20% of study participants had a Body Mass Index > 30.

In 18 of our patients orthopedic problems were present which may worsen the painful symptoms of the lower limbs; however these have not affected the results of the therapy. We paid attention to these problems since it is clear that an alteration of the foot can affect the subjective complaints of the patient. Regarding the results - as for the feeling of "heaviness" 37 (74%) - patients reported a "good-excellent" result, with resolution of symptoms. Among the 6 patients who did not achieve a satisfactory result in one case it was a patient operated for a kidney neoplasm, while in the second hystero annessiectomy with lymphadenectomy was performed for cancer; we think these problems may account for part of the treatment failure. About "cramps", a frequently reported symptom with onset in the evening hours at the end of the working hours, there has been a "good-excellent" result in 18 (78%) patients, while for "paresthesia-burning" this was achieved in 13 cases (81%); we believe these are satisfactory results, particularly in this class of patients. One final fact about the diuretic effect of the preparation: about two-thirds of patients remarked an increased frequency of urination - this result is difficult to quantify so we can only report it in an anecdotal way and further analysis is required.

Conclusions

The subjective symptoms in CEAP class 1 patients are often the cause of medical advice; in our study we tested the effectiveness of a herbal compound on the daily activity of a "high-risk class of patients", the nursing staff, with a 15-day "short-term" therapy.

The results were satisfactory with an improvement of subjective symptoms during and after working hours.

We believe that in this particular category of professionals programs to prevent varicose veins disease should be implemented because of the many risk factors which they are exposed to on a daily basis.

References

1. Ramelet AA. Daflon 500 mg: symptoms and clinical update. *Angiology*. 2005; 56 Suppl 1:S25-32.
2. Broman K, Pannier-Fisher F, Stang A, Rabe E, Bock E, Jöckel KH. Should sex specific differences in venous diseases be explained by pregnancies and hormone intake? *Gesundheitswesen*. 2004; 66(3):170-4.
3. Beebe-Dimmer JL, Pfeifer JR, Engle JS, Schottenfeld D. The epidemiology of chronic venous insufficiency and varicose veins. *Ann Epidemiol*. 2005; 15(3):175-184.
4. Ziegler S, Eckardt G, Stöger R, Machula J, Rüdiger HW. High prevalence of chronic venous disease in hospital employees. *Wien Klin Wochenschr*. 2003; 115(15-16):575-9.
5. Sharif Nia H, Chan YH, Haghdoost AA, Soleimani MA, Behesti Z, Bahrami N. Varicose veins of the legs among nurses: Occupational and demographic characteristics. *Int J Nurs Pract*. 2015; 21(3):313-20.
6. Umesh SR, David S, Segaran F, Venkatesh K. Work related health problems among nursing personnel. *Nurs J India*. 2014; 105(6):254-7.
7. Fowkes FG, Lee AJ, Evans CJ, Allan PL, Bradbury AW, Ruckley CV. Lifestyle risk factors for lower limb venous reflux in the general population: Edinburgh Vein Study. *Int J Epidemiol*. 2001; 30(4):846-52.
8. Chen CL, Guo HR. Varicose veins in hairdressers and associated risk factors: a cross-sectional study. *BMC Public Health*. 2014; 14:885.
9. Wrona M, Jöckel KH, Pannier F, Bock E, Hoffmann B, Rabe E. Association of venous disorders with leg symptoms; result from the Bonn Vein Study 1. *Eur J Vasc Endovasc Surg*. 2015; 50(3):360-7.
10. Jawien A. The influence of environmental factors in chronic venous insufficiency. *Angiology*. 2003; 54 Suppl 1:S19-31.
11. Seidel AC, Belczak CE, Campos MB, Campos RB, Harada DS. The impact of obesity on venous insufficiency. *Phlebology*. 2015; 30(7):475-80.
12. Chiesa R, Marone EM, Limoni C, Volonté M, Schaefer E, Petrini O. Effect of chronic venous insufficiency on activities of daily living and quality of life: correlation of demographic factors with duplex ultrasonography findings. *Angiology*. 2007; 58(4):440-9.

Courses and Congresses

2017

12-14 May – Rome (Italy)
38th National Congress of the Italian Society of Aesthetic Medicine
12th National Congress of the Italian Academy of Aesthetic Medicine

Venue: Congress Centre Rome Cavalieri
President: Emanuele Bartoletti
E-mail: sime@lamedicinaestetica.it
congresso@lamedicinaestetica.it
Web: www.lamedicinaestetica.it

8-9 September - Paris (France)
38th National Congress of Aesthetic Medicine and Dermatologic Surgery

French Society of Aesthetic Medicine
French Association of Morpho-Aesthetic and Anti-Aging Medicine
National Institute of education in aging prevention
President: J.J. Legrand
Web: www.sfme.info

22-24 September - Almaty (Kazakhstan)
9th National Congress of Aesthetic Medicine and Plastic Surgery
Kazakhstan Association of Aesthetic Medicine and Plastic Surgery

President: G. Zhumatova
E-mail: info@esthetic.kz
Web: www.estetic.kz

27-29 October - Istanbul (Turkey)
21th World Congress of Aesthetic Medicine

Turkish Society of Aesthetic Medicine
President: Hasan Subasi
Rumeli Caddesi Durak Apt N° 2, D.7
Nisantasi, Istanbul - Turkey
E-mail: subasihasanm@superonline.com
Web: www.estetiktipdernegi.org.tr

2018


2-3 March - Mexico City (Mexico)
15th Mexican Scientific Congresso of Aesthetic Medicine and Antiaging
15th Venezuelan Congress of Aesthetic Medicine

Mexican Scientific Society of Aesthetic Medicine
Aesthetic Medicine Society of Venezuela
Presidents: Blanca Miller Kobisher and Víctor García Guevara
Venue: Pepsi Center - World Trade Center, Mexico City
E-mail: congresoacademico@ippc.mx

4-6 April - Buenos Aires (Argentina)
12th Pan-American Congress of Aesthetic Medicine
28th Argentinian Congress of Aesthetic Medicine

Argentinian Society of Aesthetic Medicine - SOARME
President: Raul Pinto
Venue: Auditorio de la Universidad Católica Argentina
Av. Alicia Moreau de Justo 1680
Puerto Madero - Buenos Aires
Web: www.soarme.com

Contents



Dermoscopy in Aesthetic Medicine: usefulness and limits (I part)	45
Elisabetta Fulgione, Vincenzo Piccolo, Anna Rosa Catizzone, Giuseppe Argenziano	
Cryoadipolysis: a technique that delivers results	53
Rafael Serena	
Height enhancement using hyaluronic acid and minimally invasive technique	57
Dario Martusciello	
Efficacy of a phytotherapeutic preparation on professional activities of nurses in an Italian hospital	65
Alberto Garavello, Ugo Alonzo	
Courses and Congresses	69